

1420

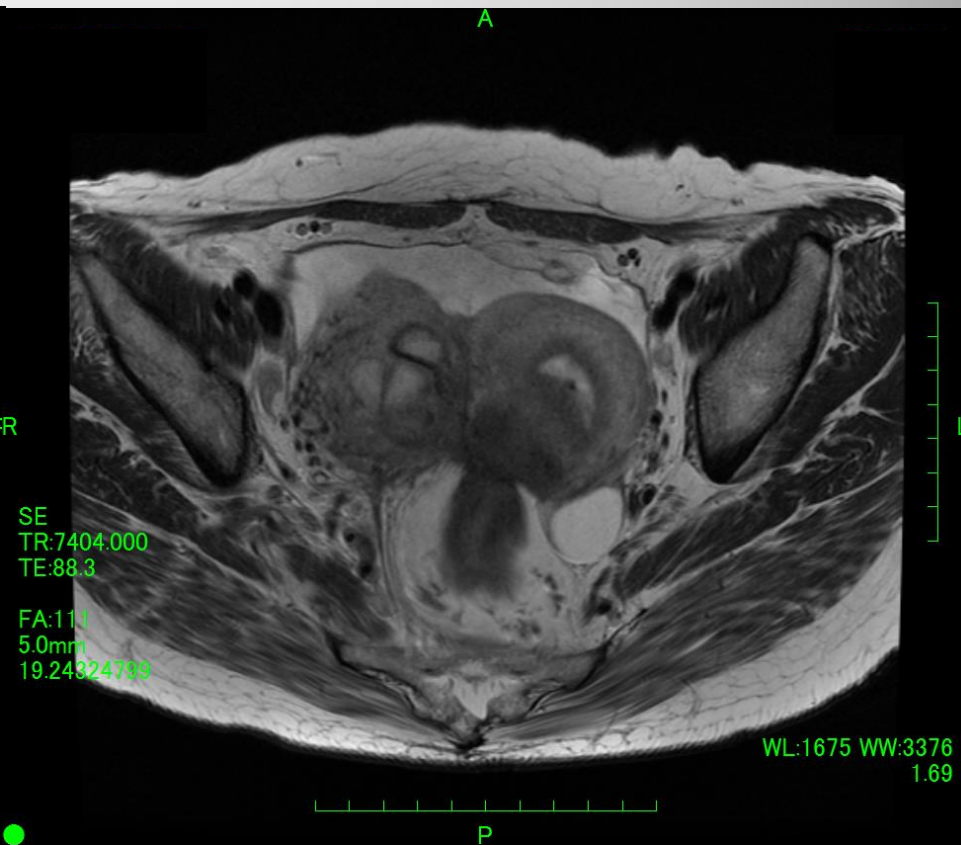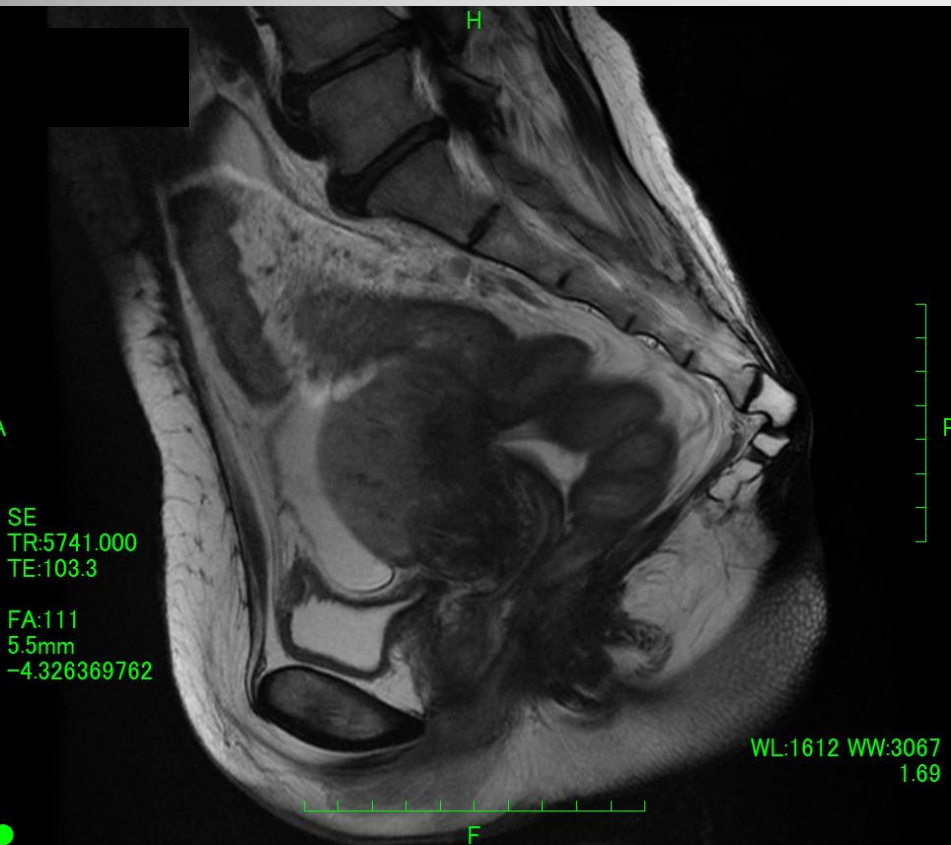子宮病変

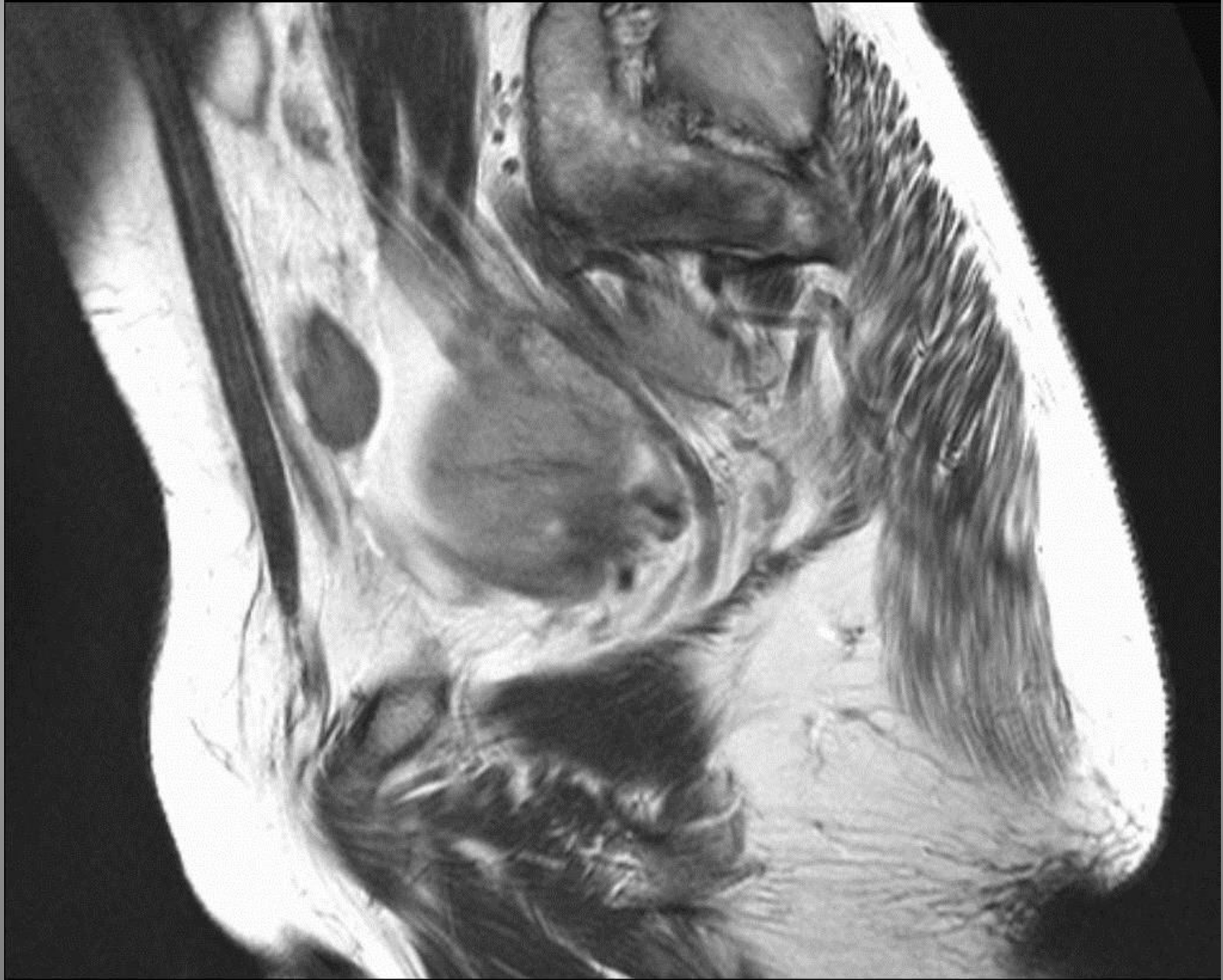
倉敷中央病院 病理診断科

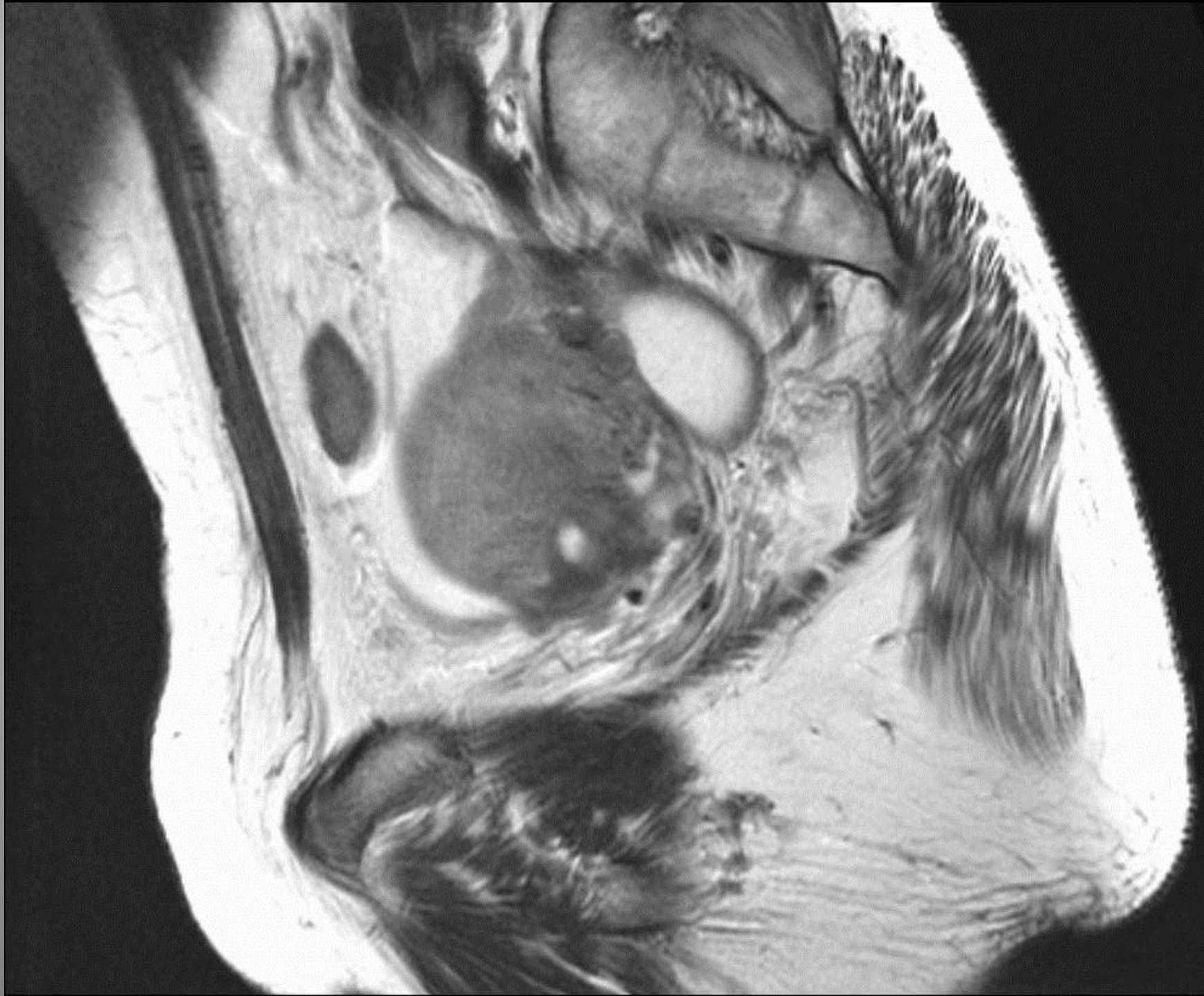
**井関 昭子、寺田 和弘、沖田 千佳
板倉 淳哉、石井 文彩、内野 かおり、能登原 憲司**

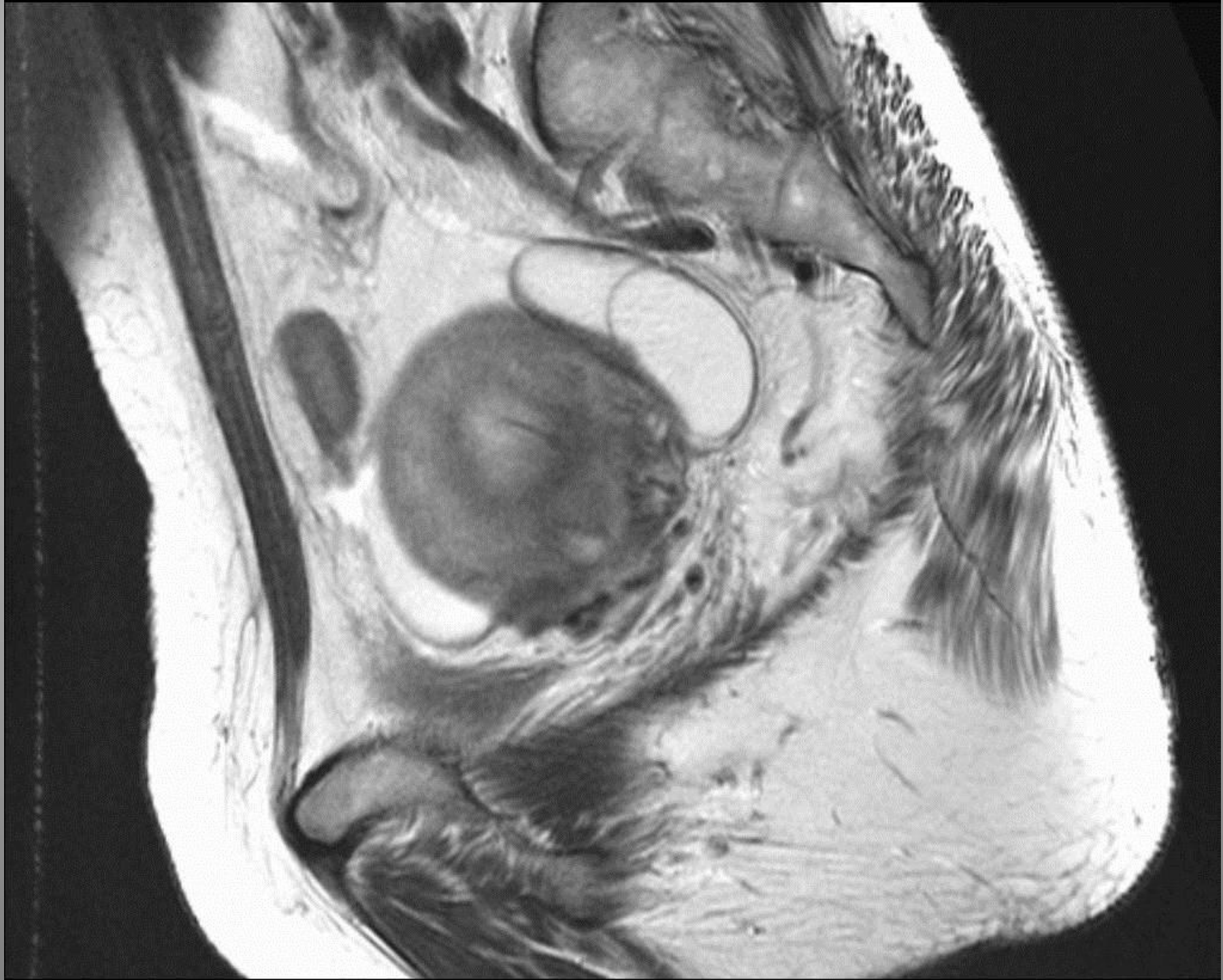
MRI画像

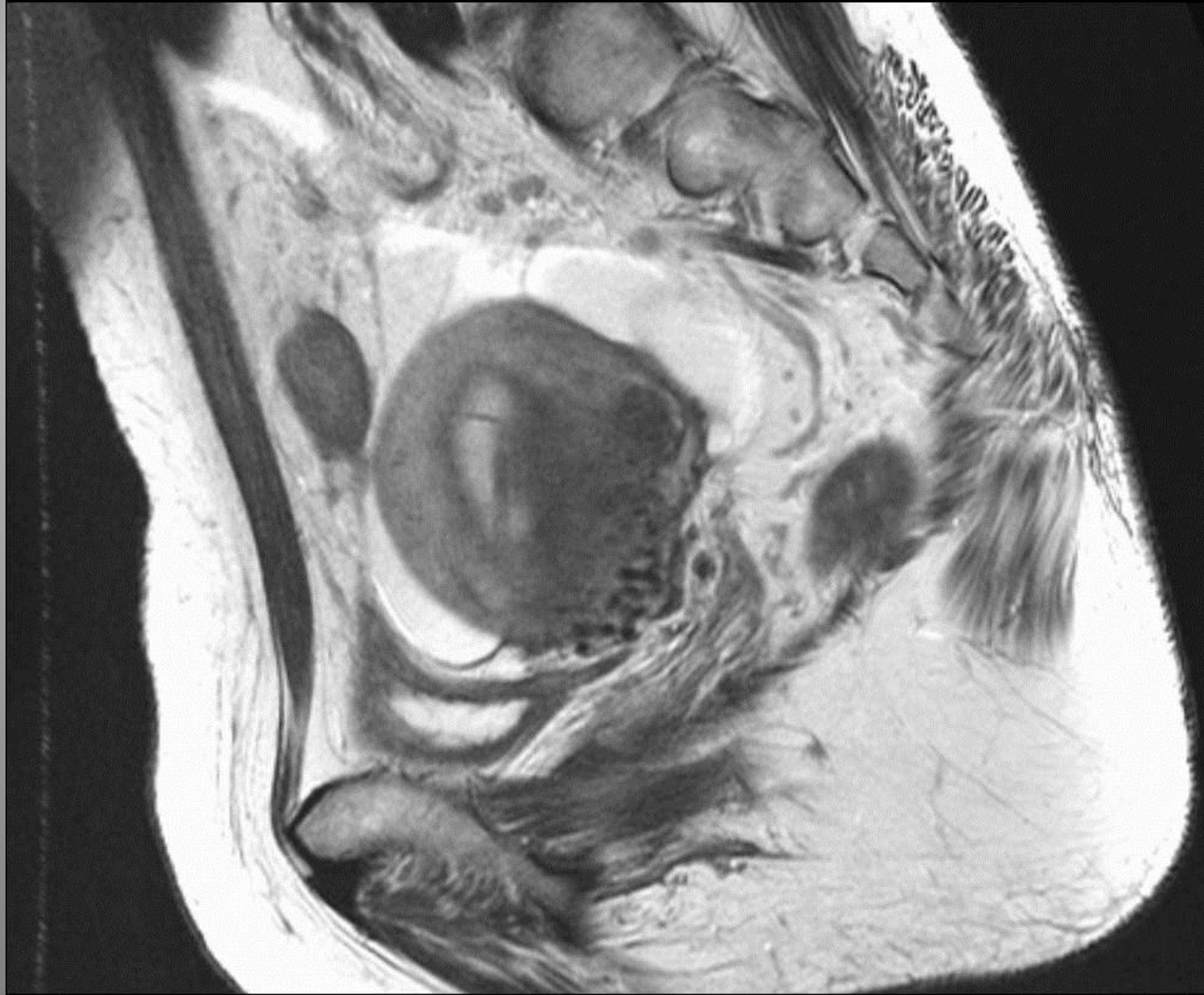T2強調像

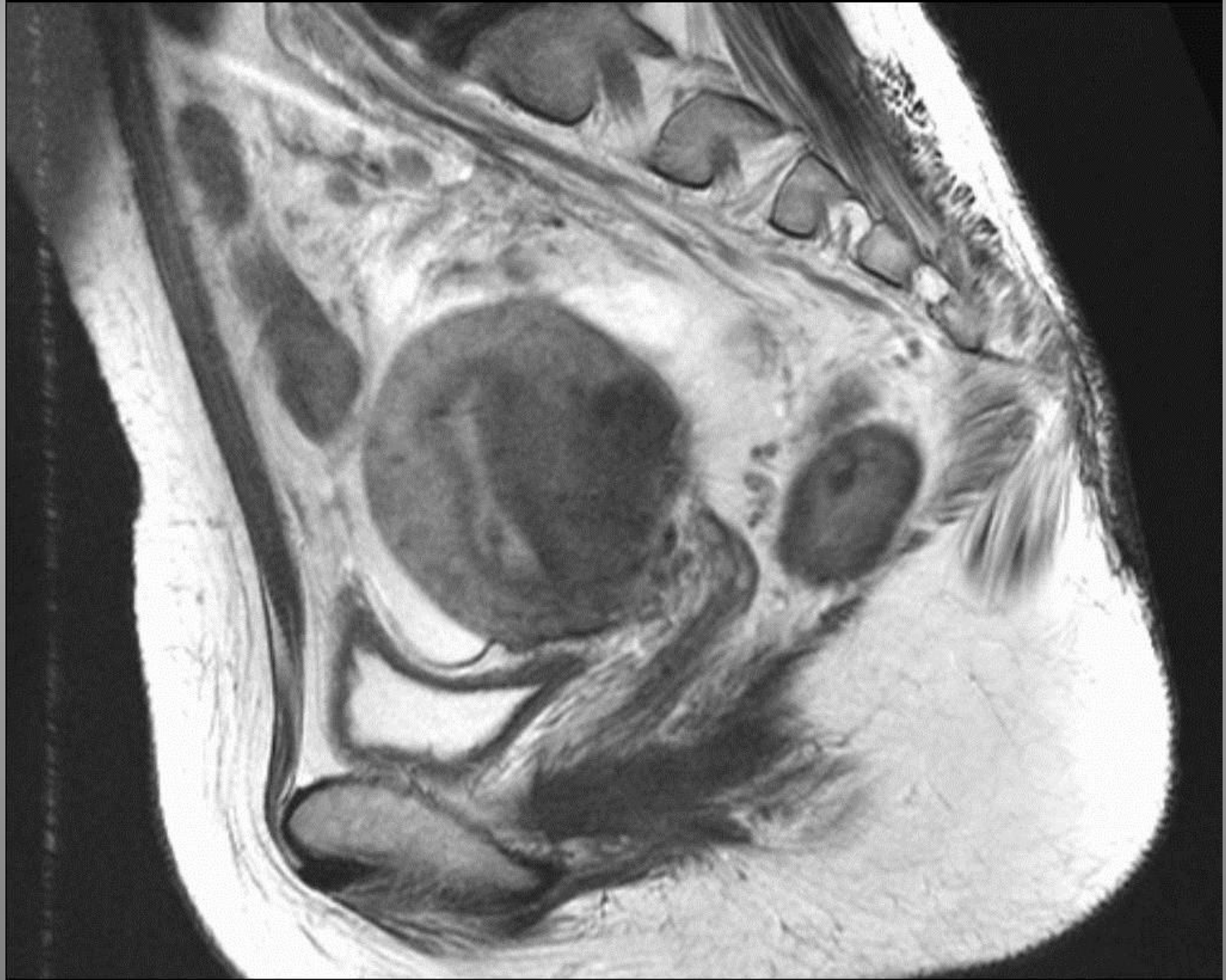


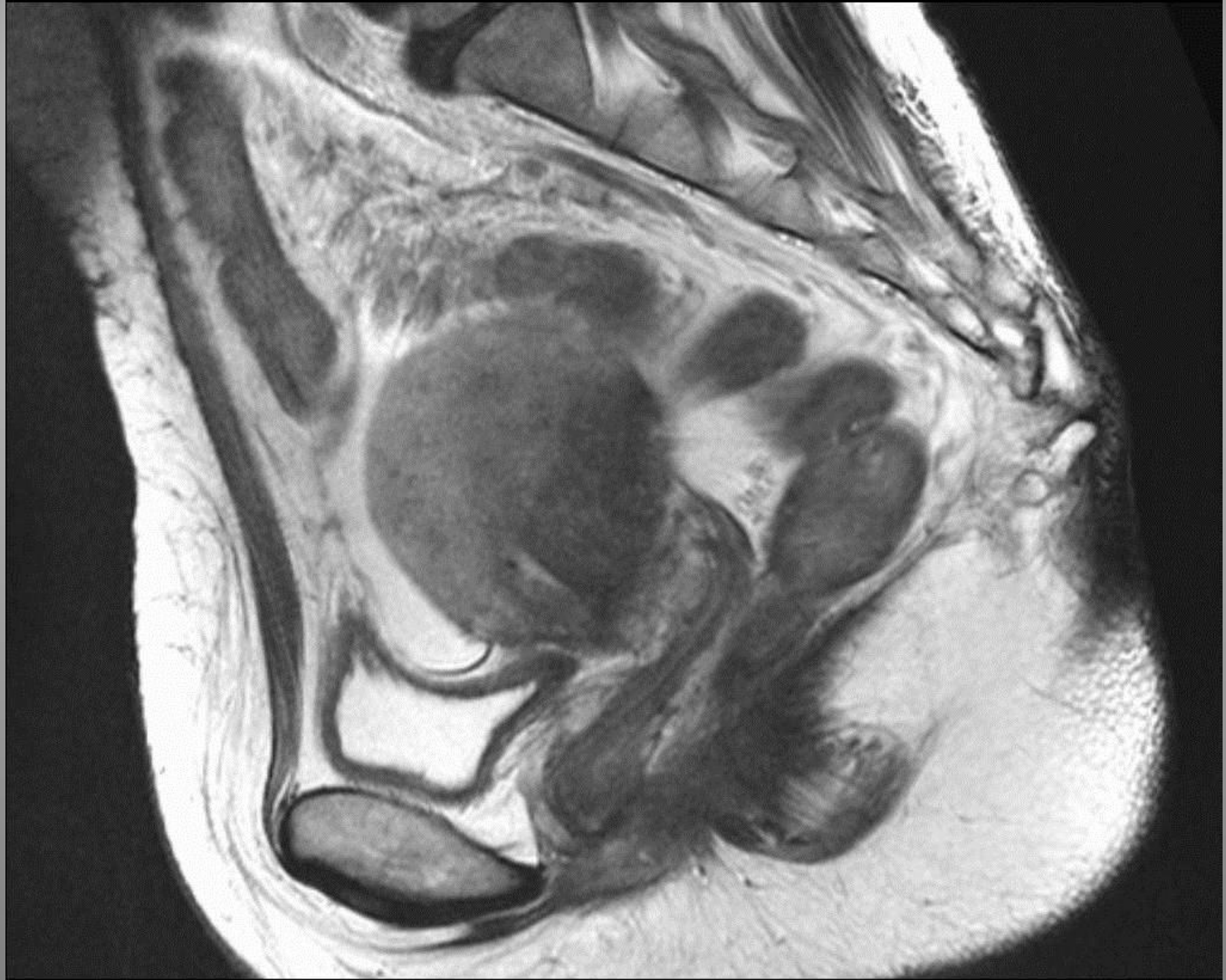


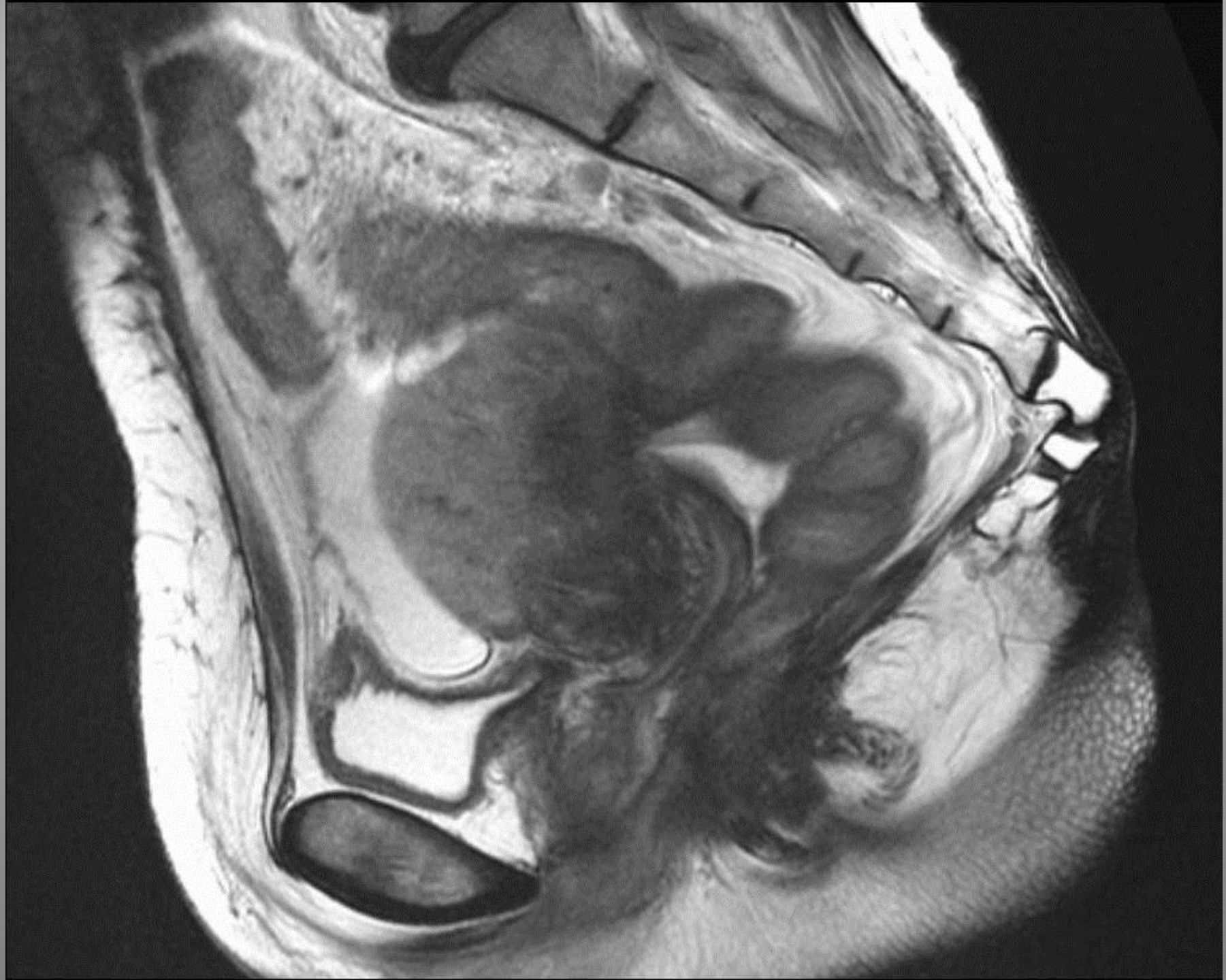


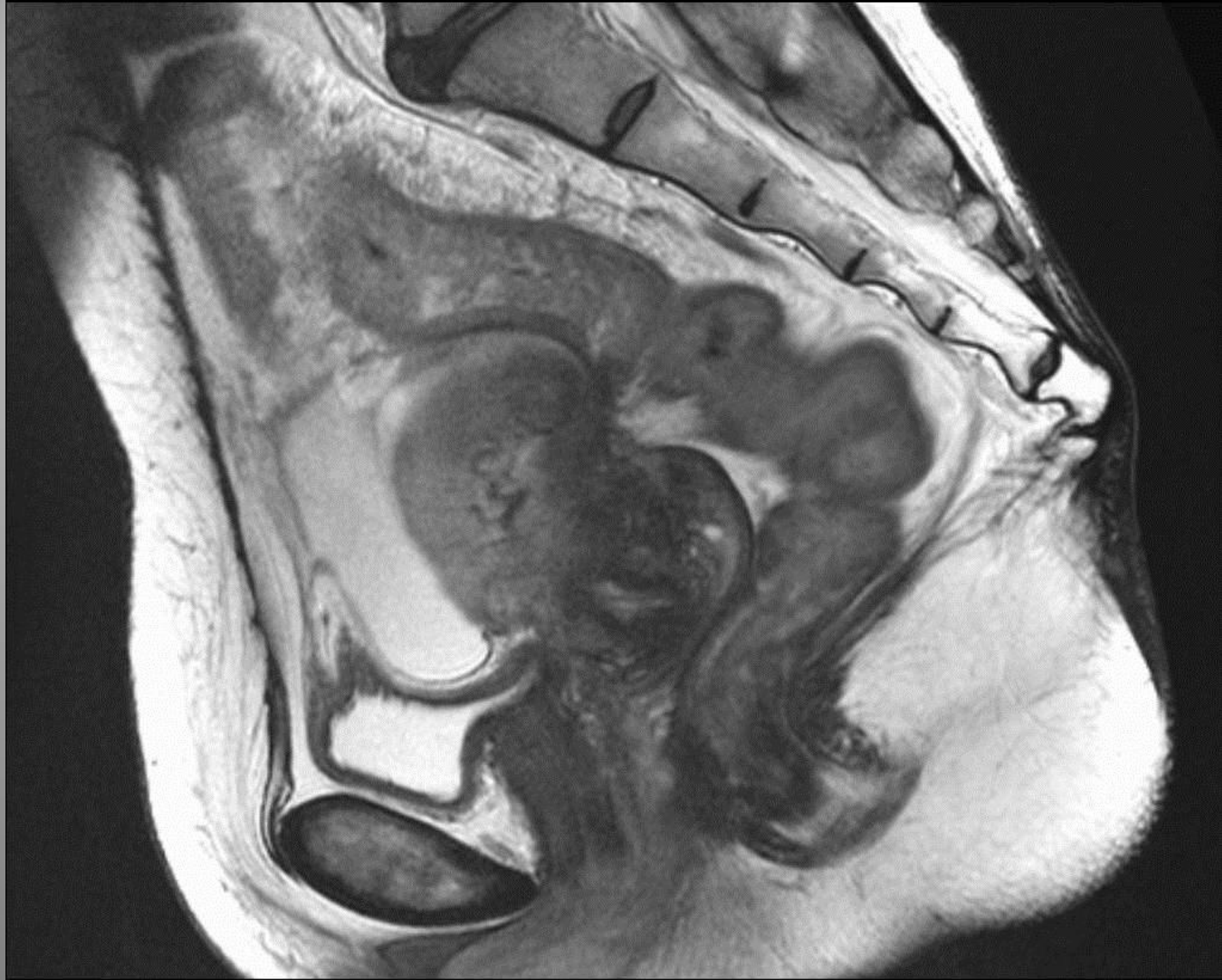


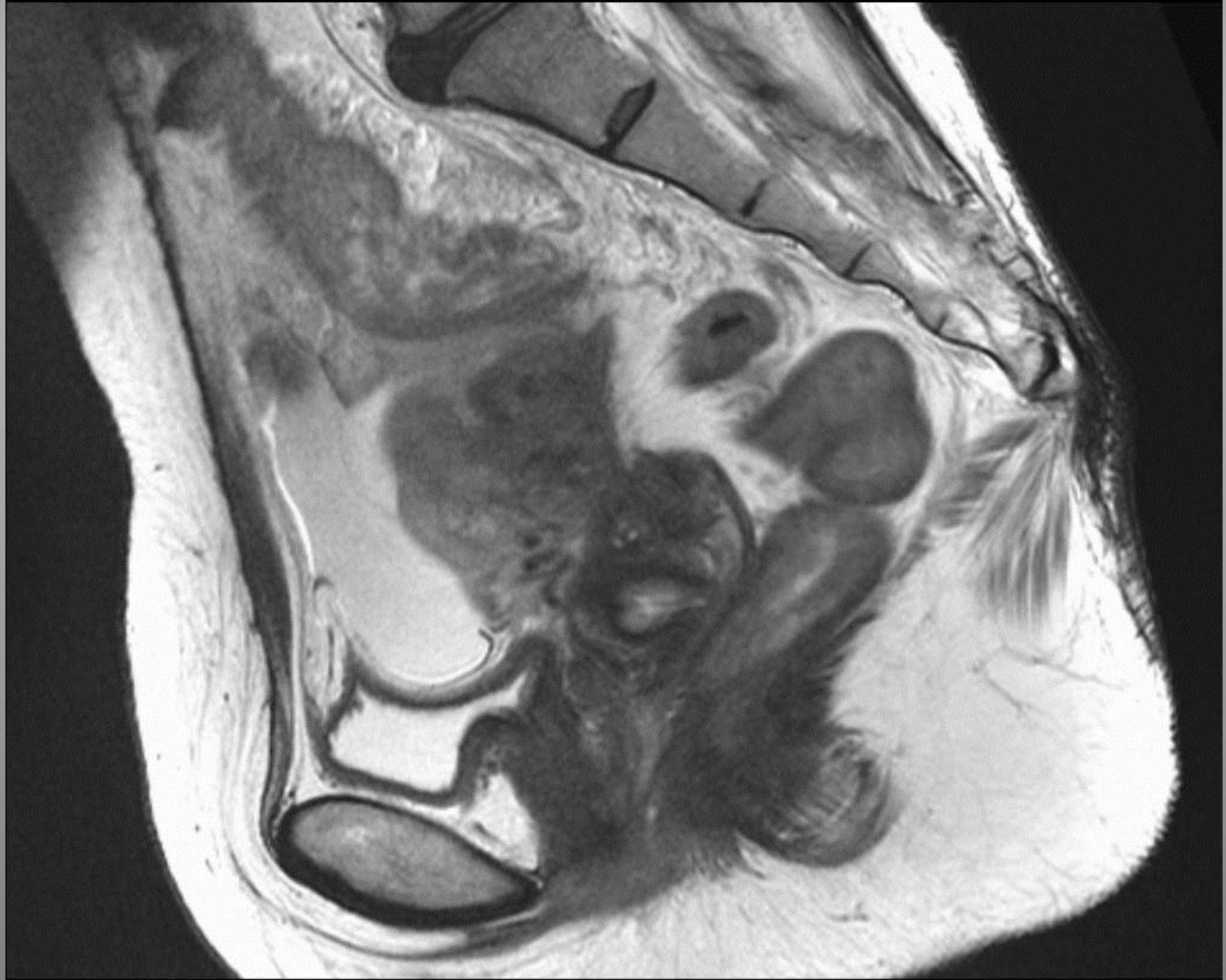


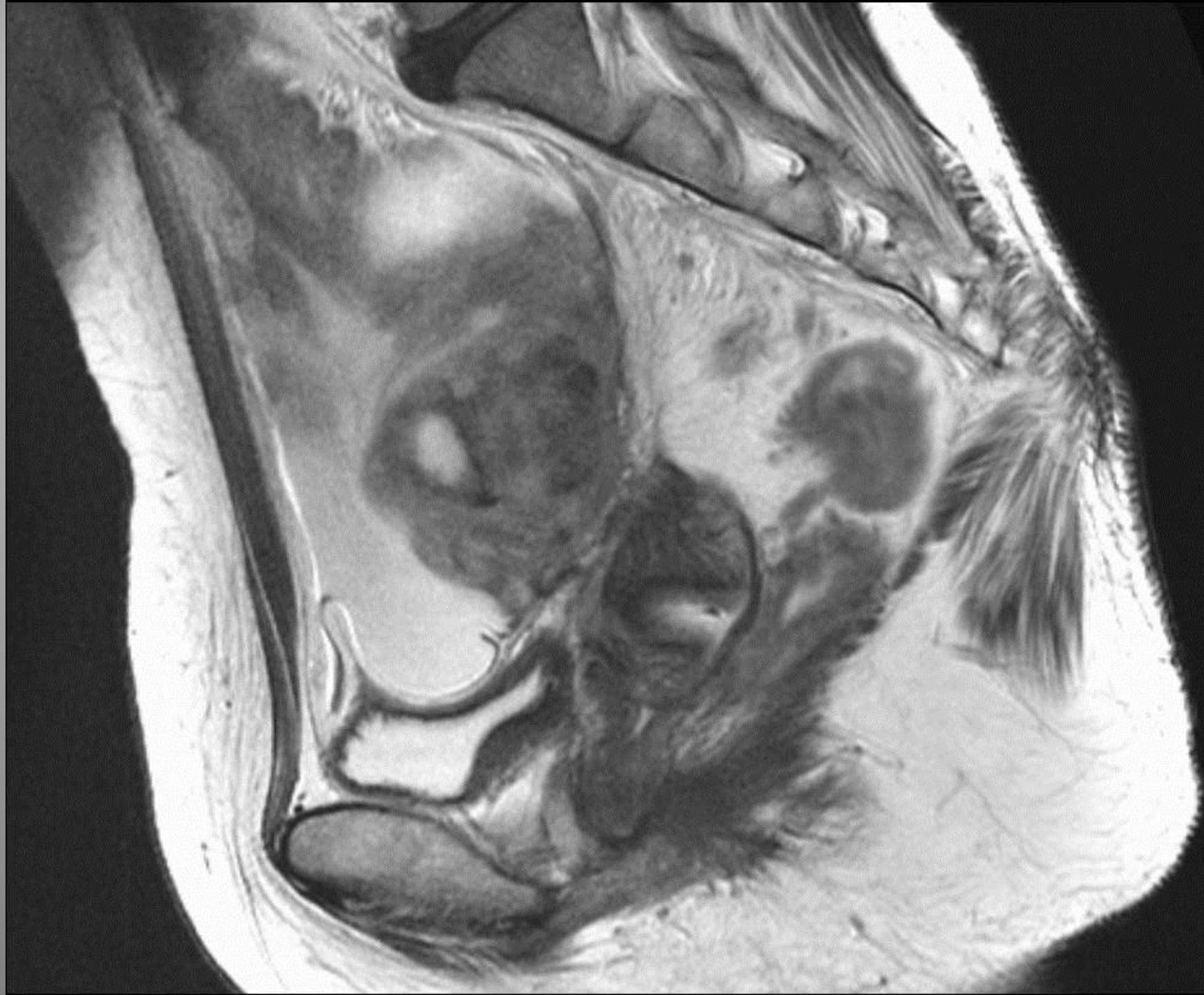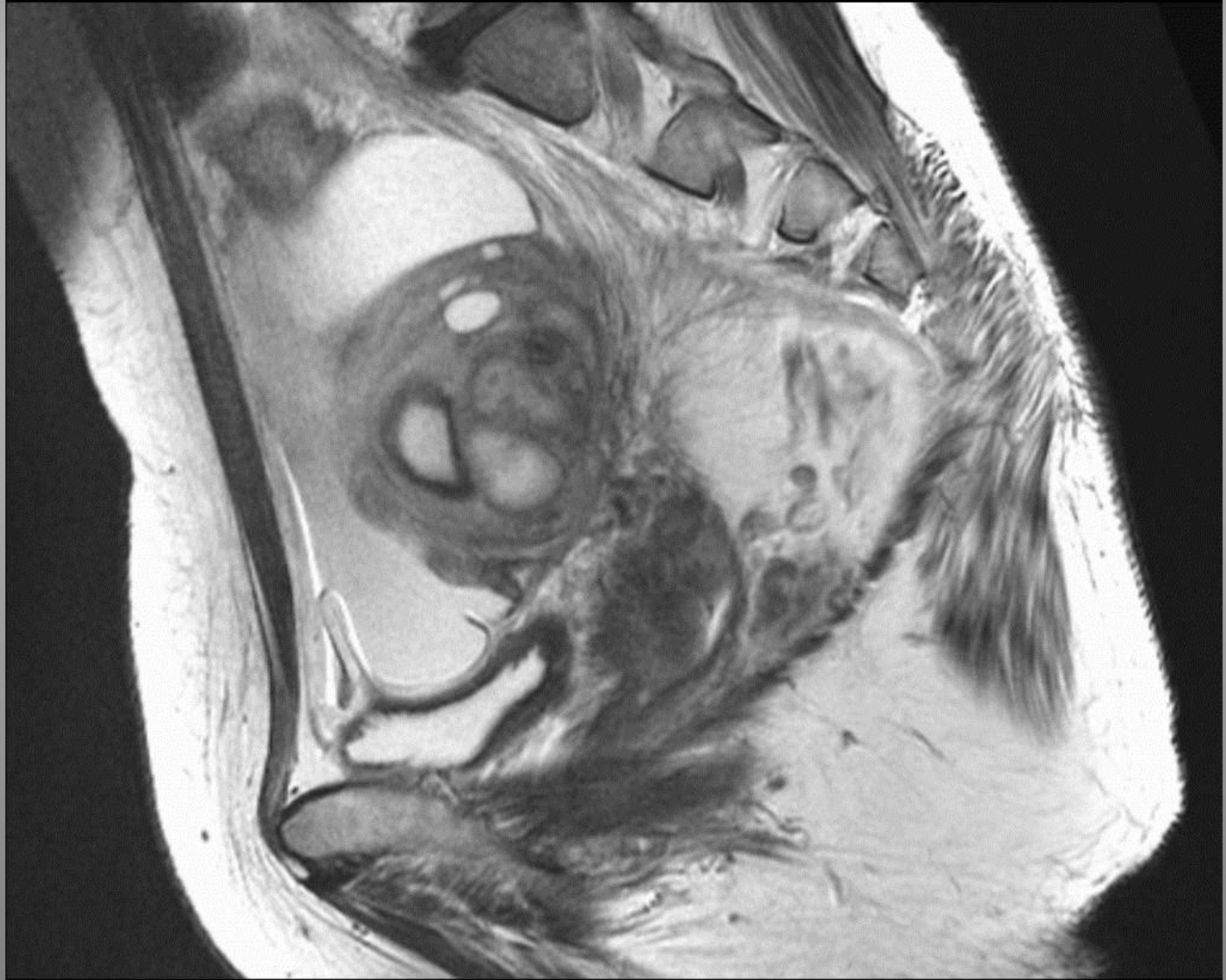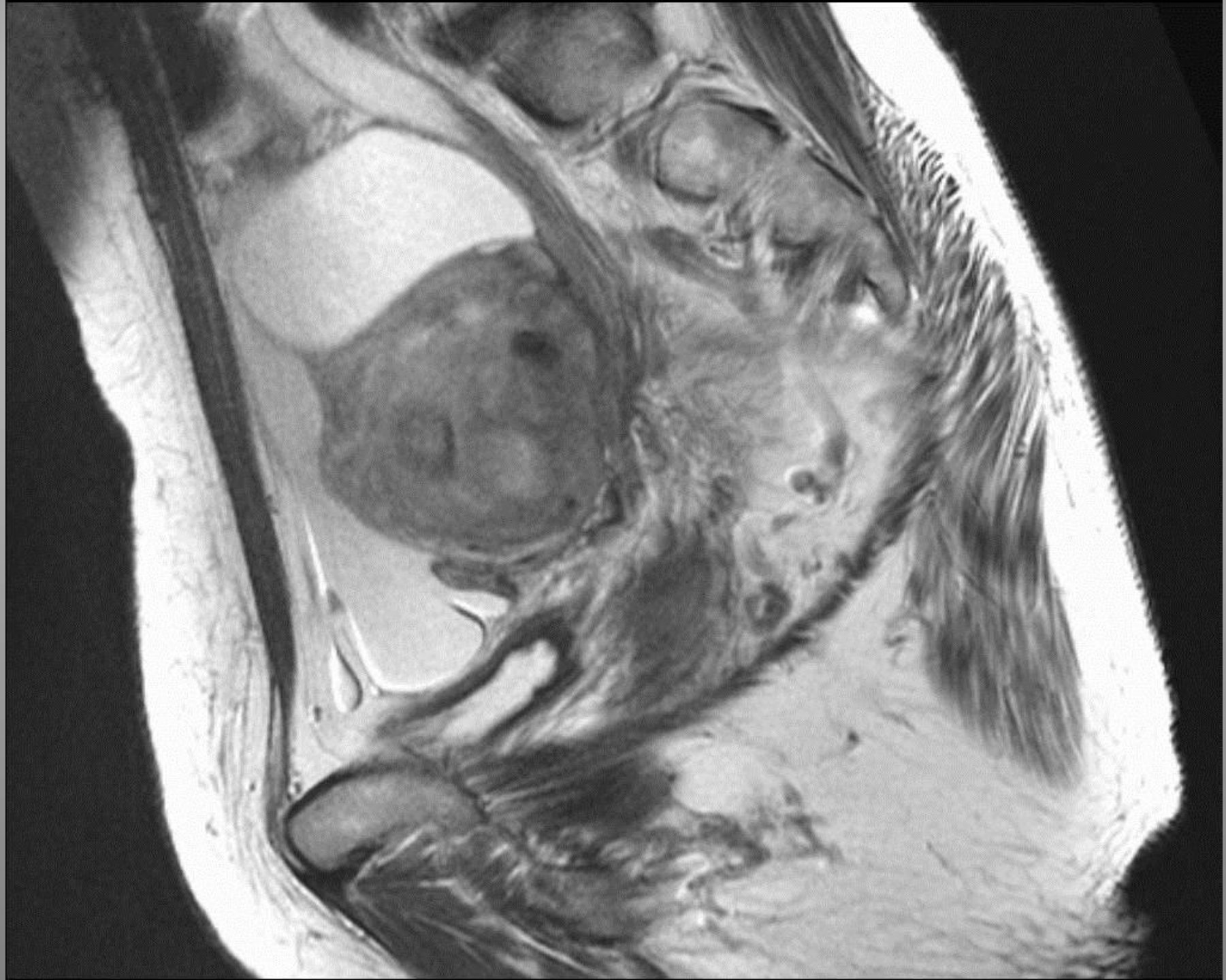








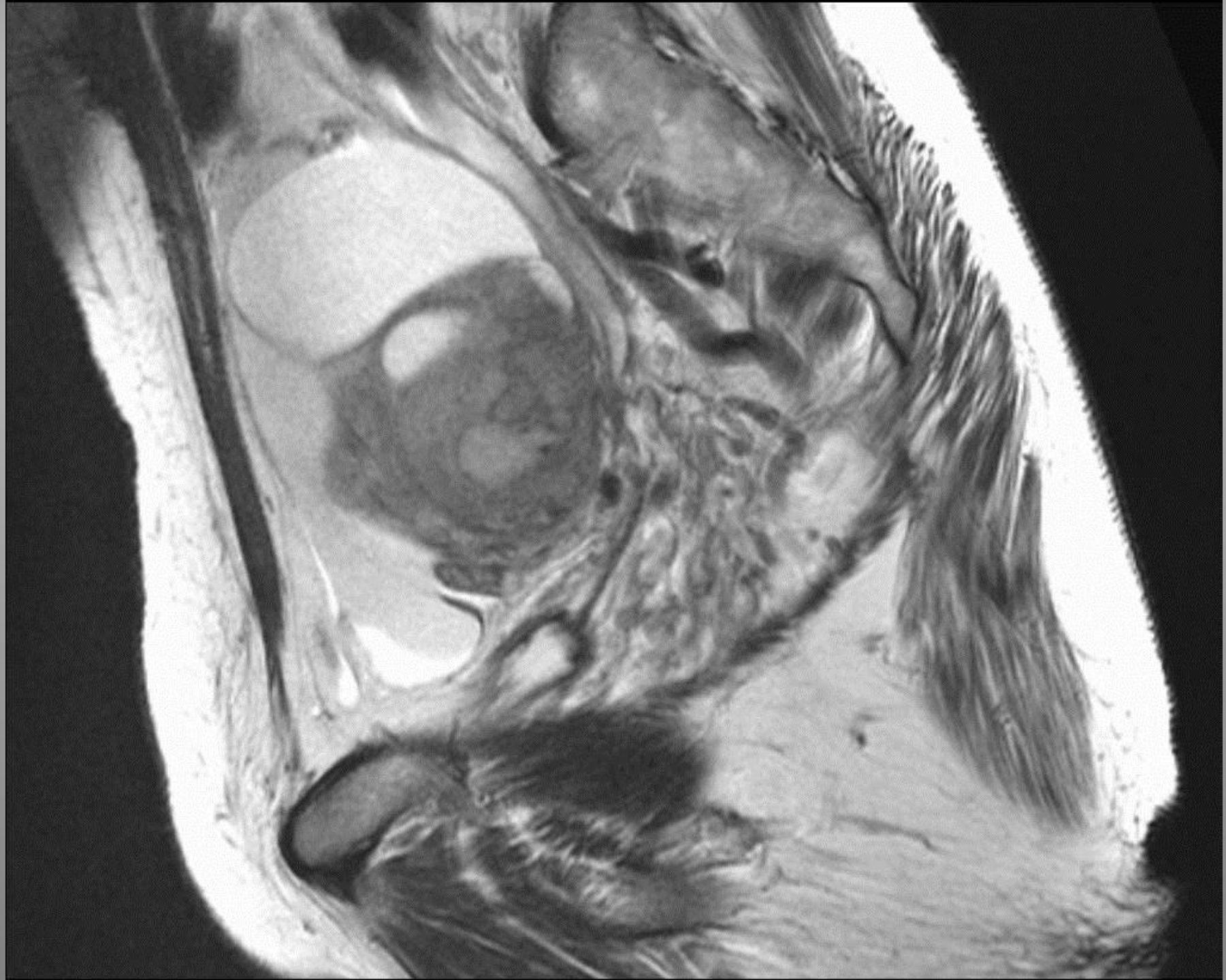
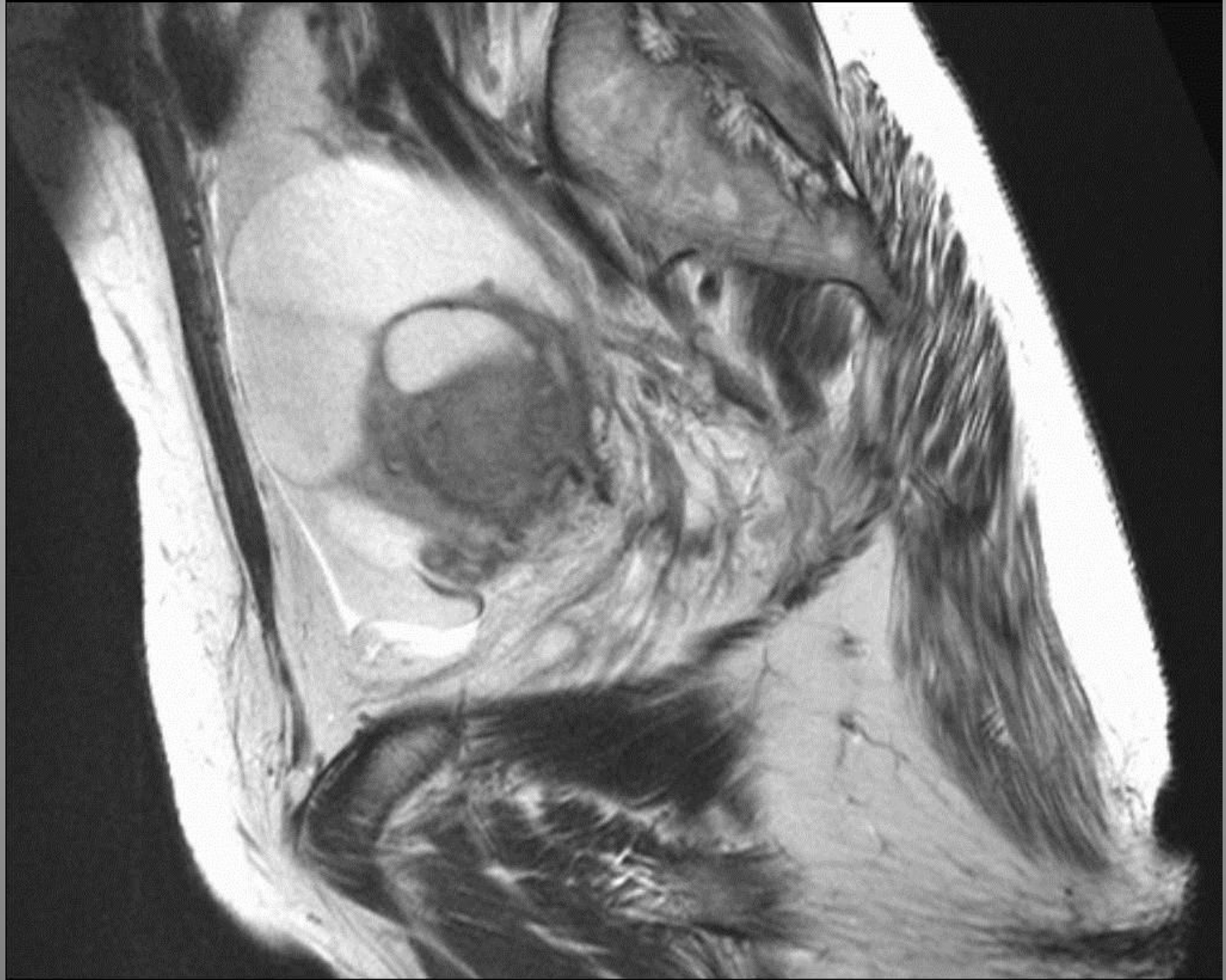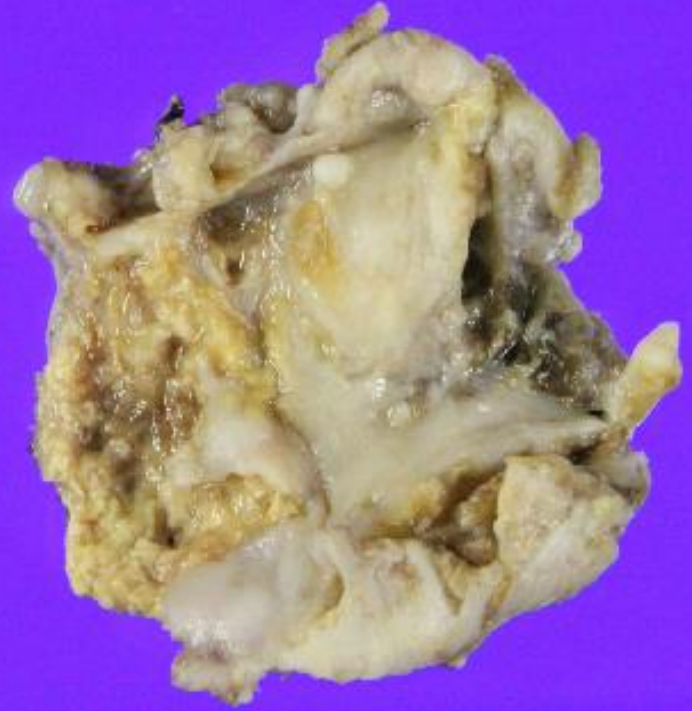




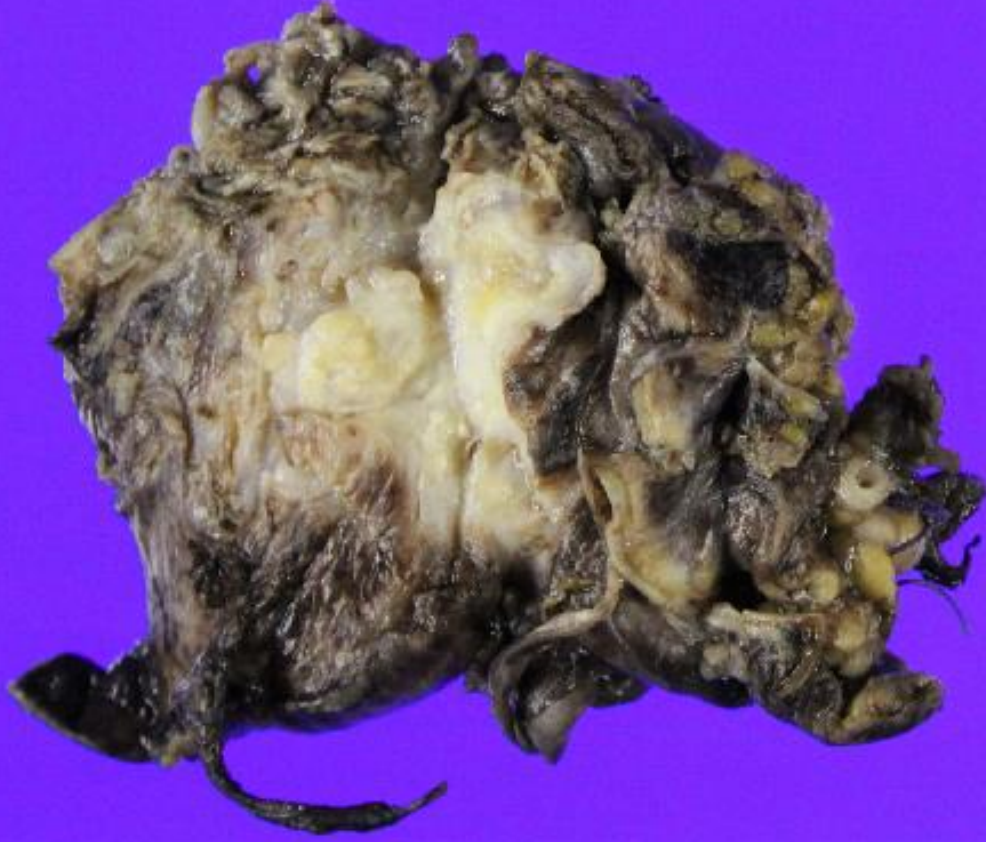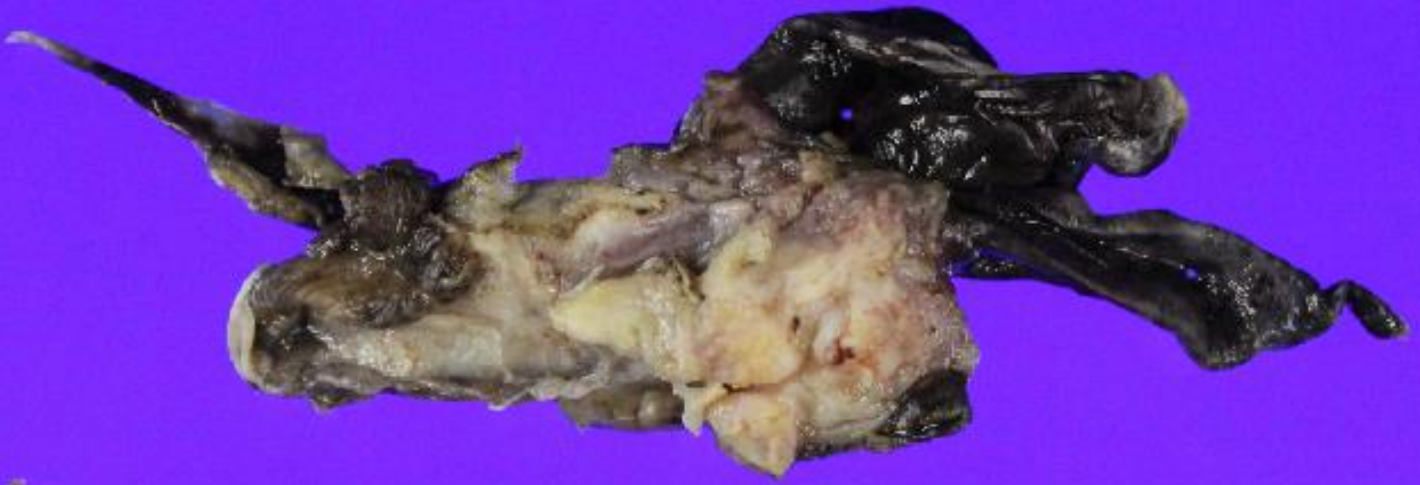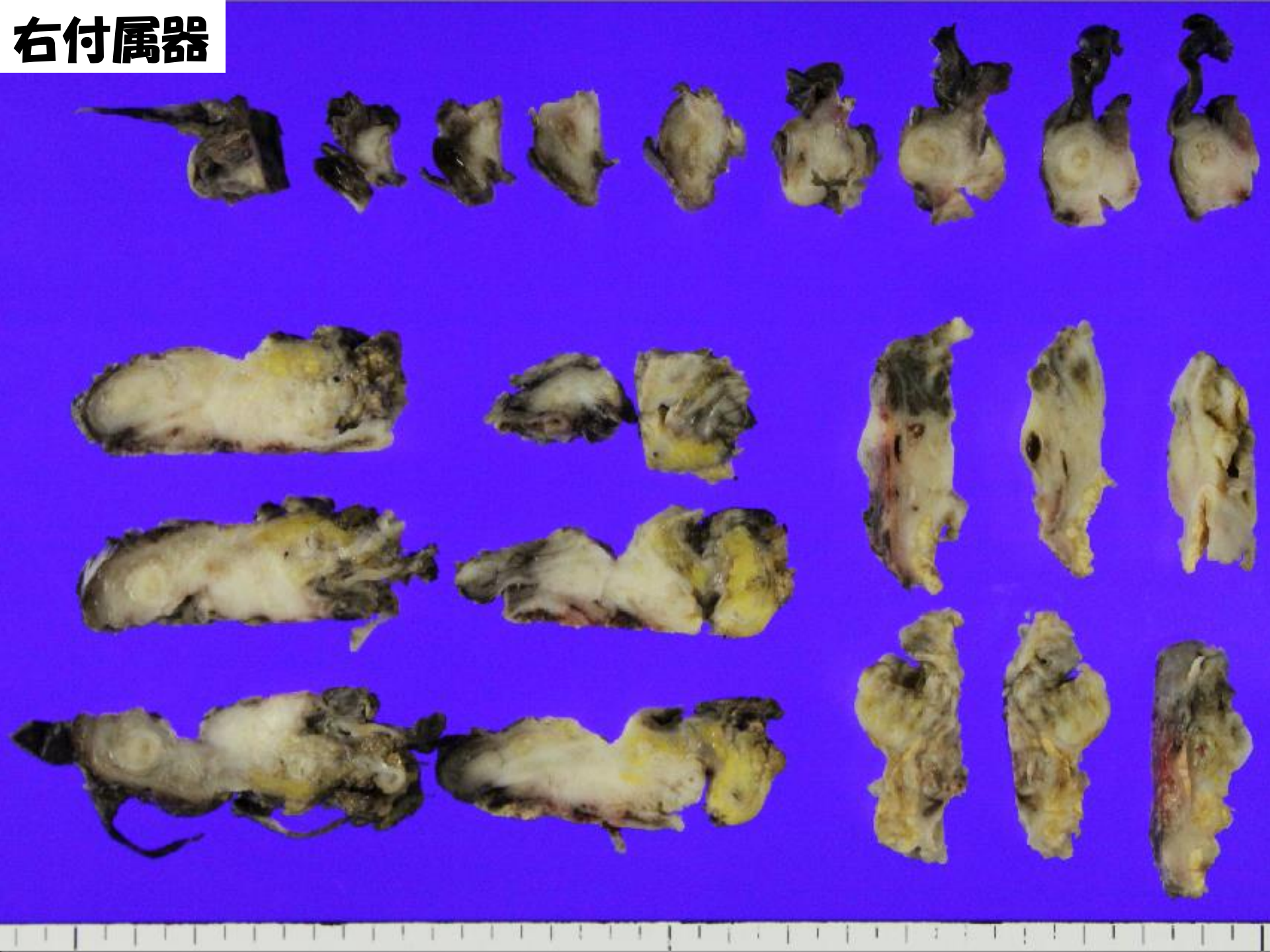




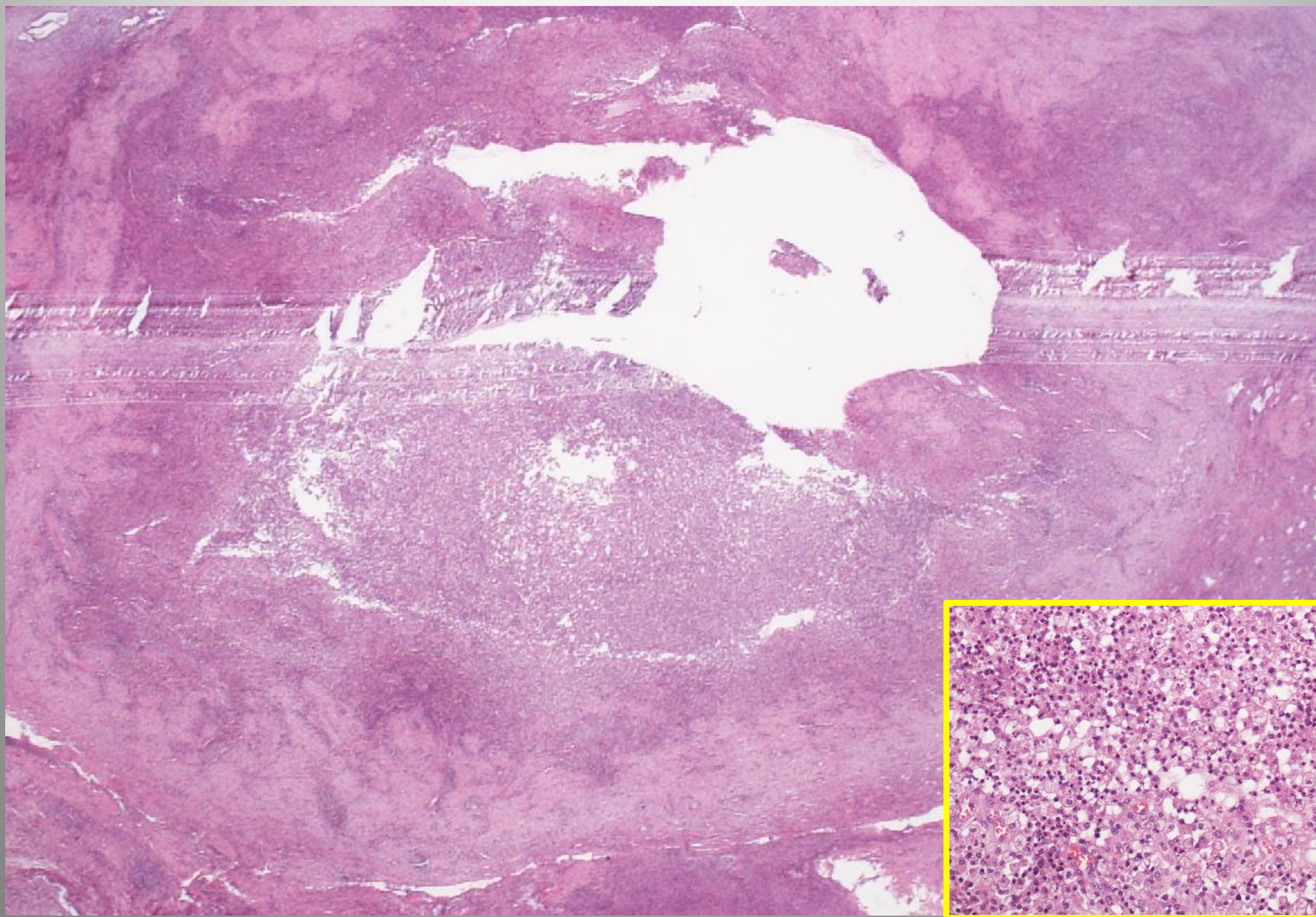
右付属器



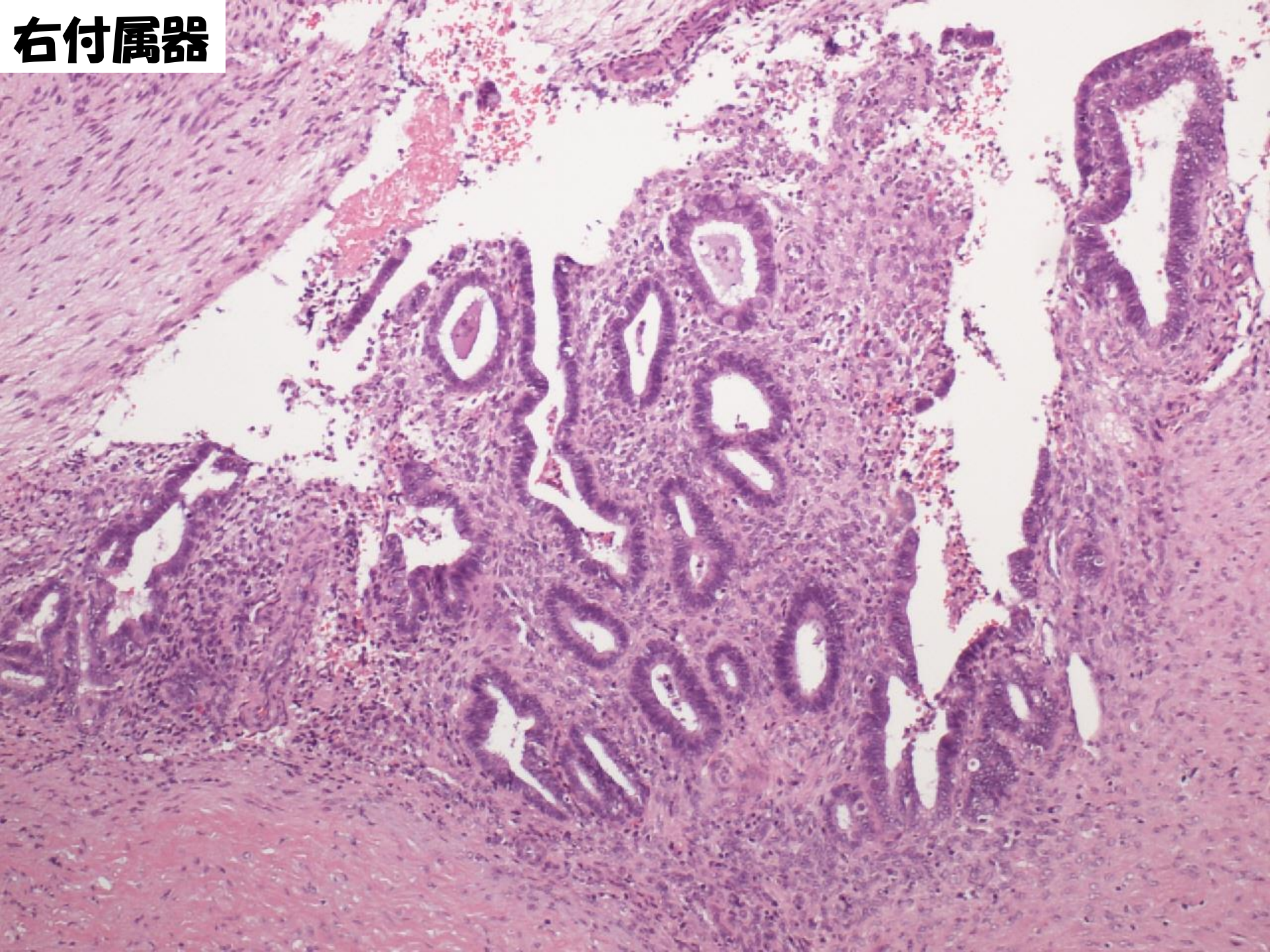
右付属器



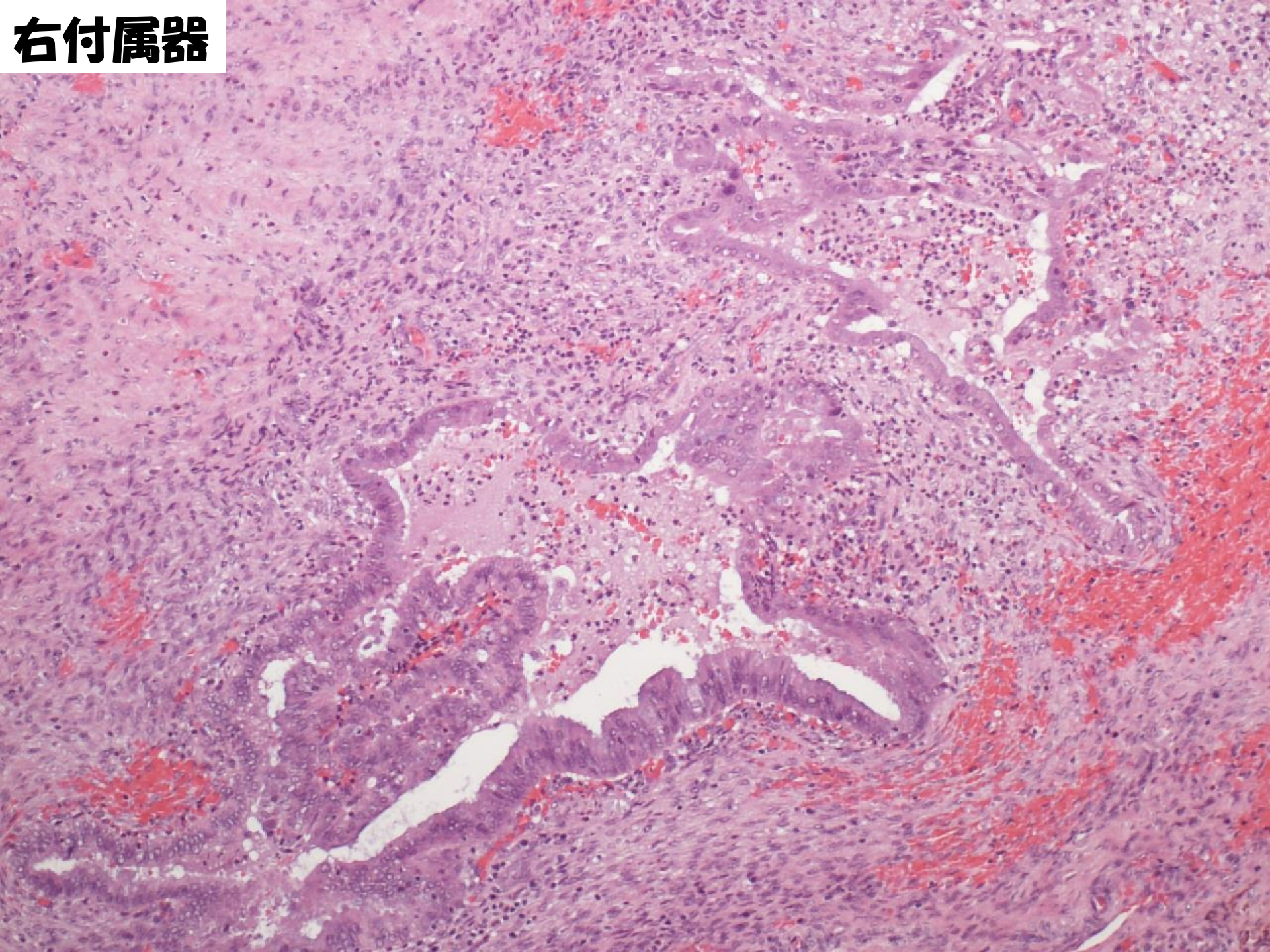
組織所見 右付属器



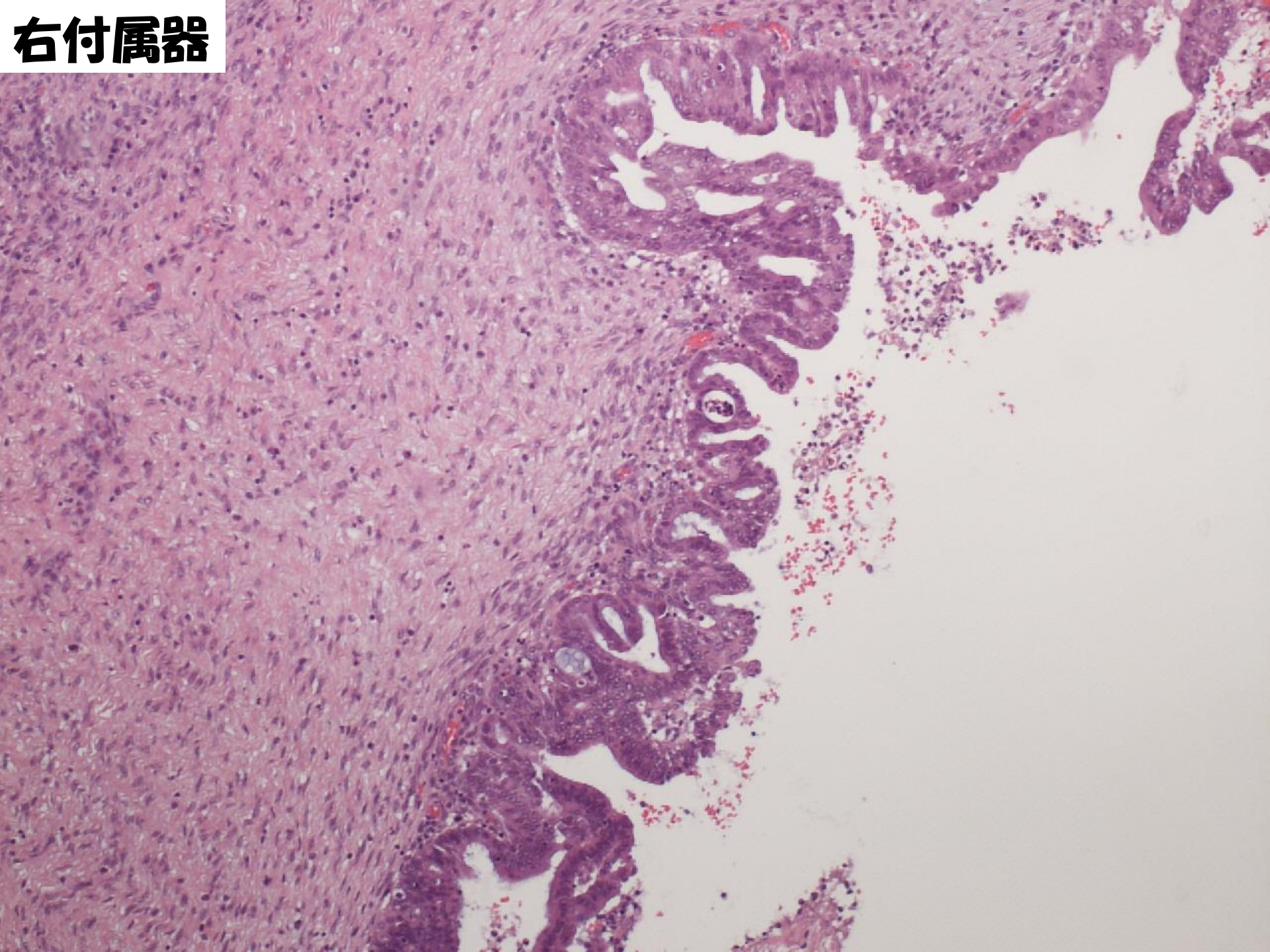
右付属器

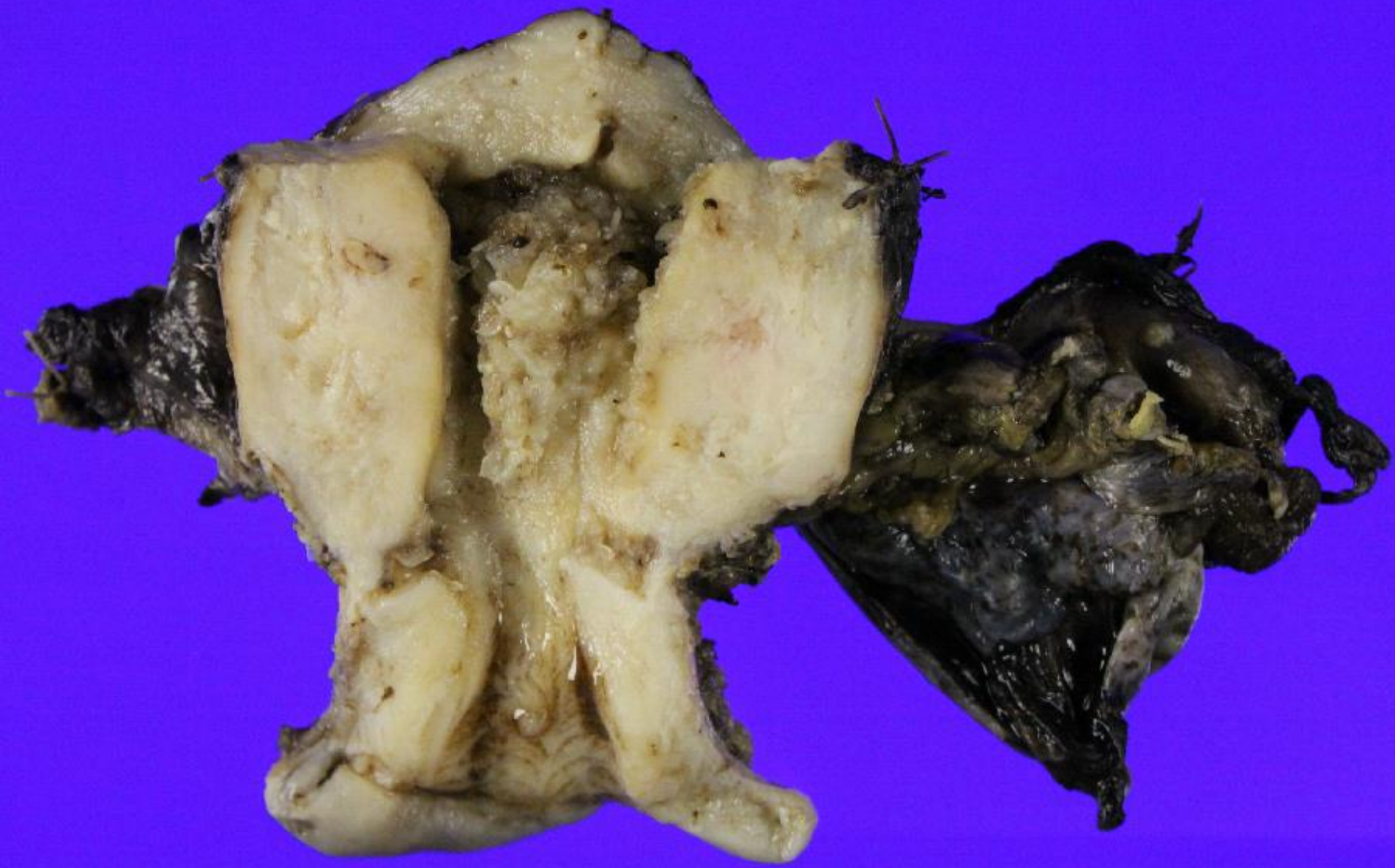


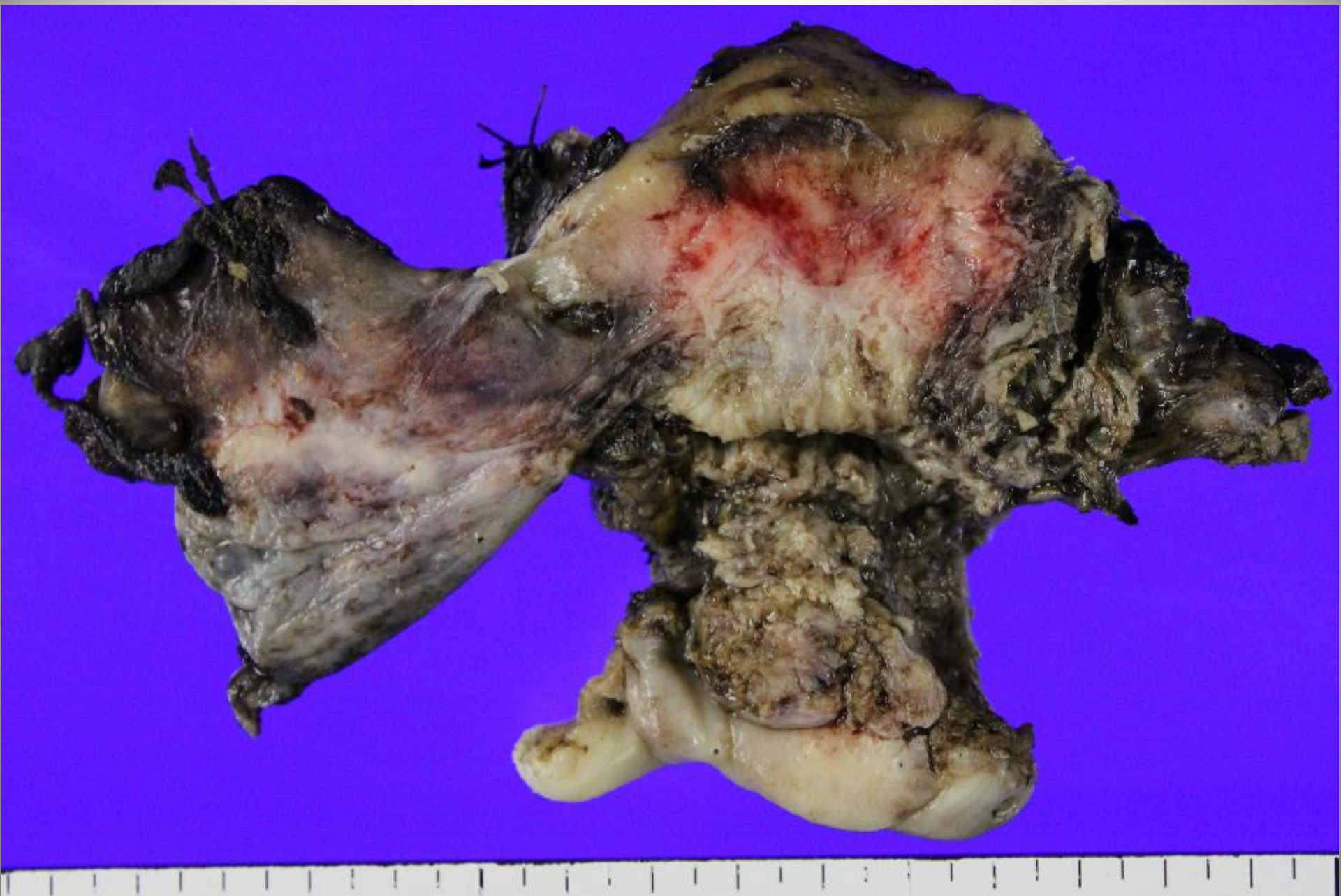右付属器

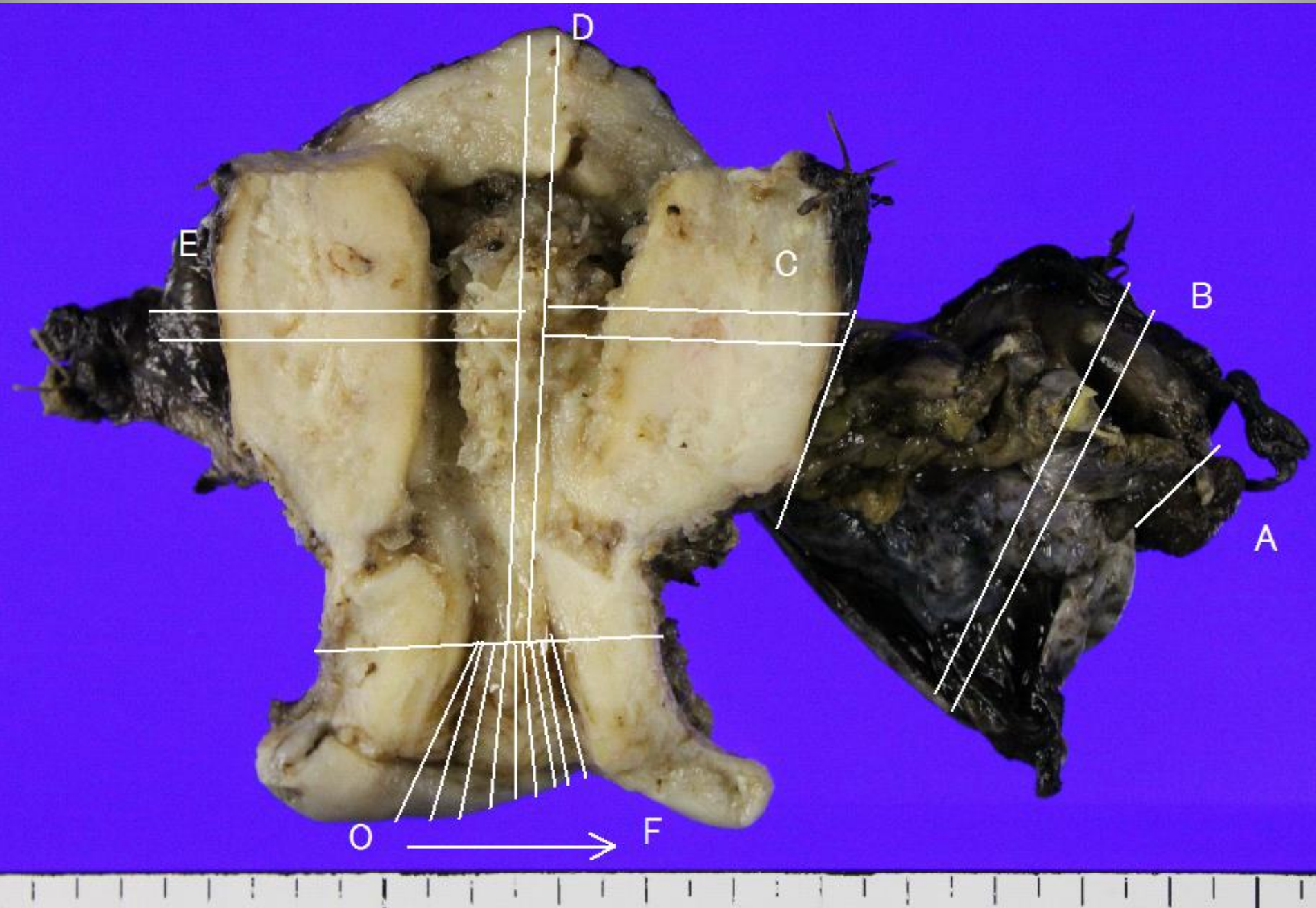


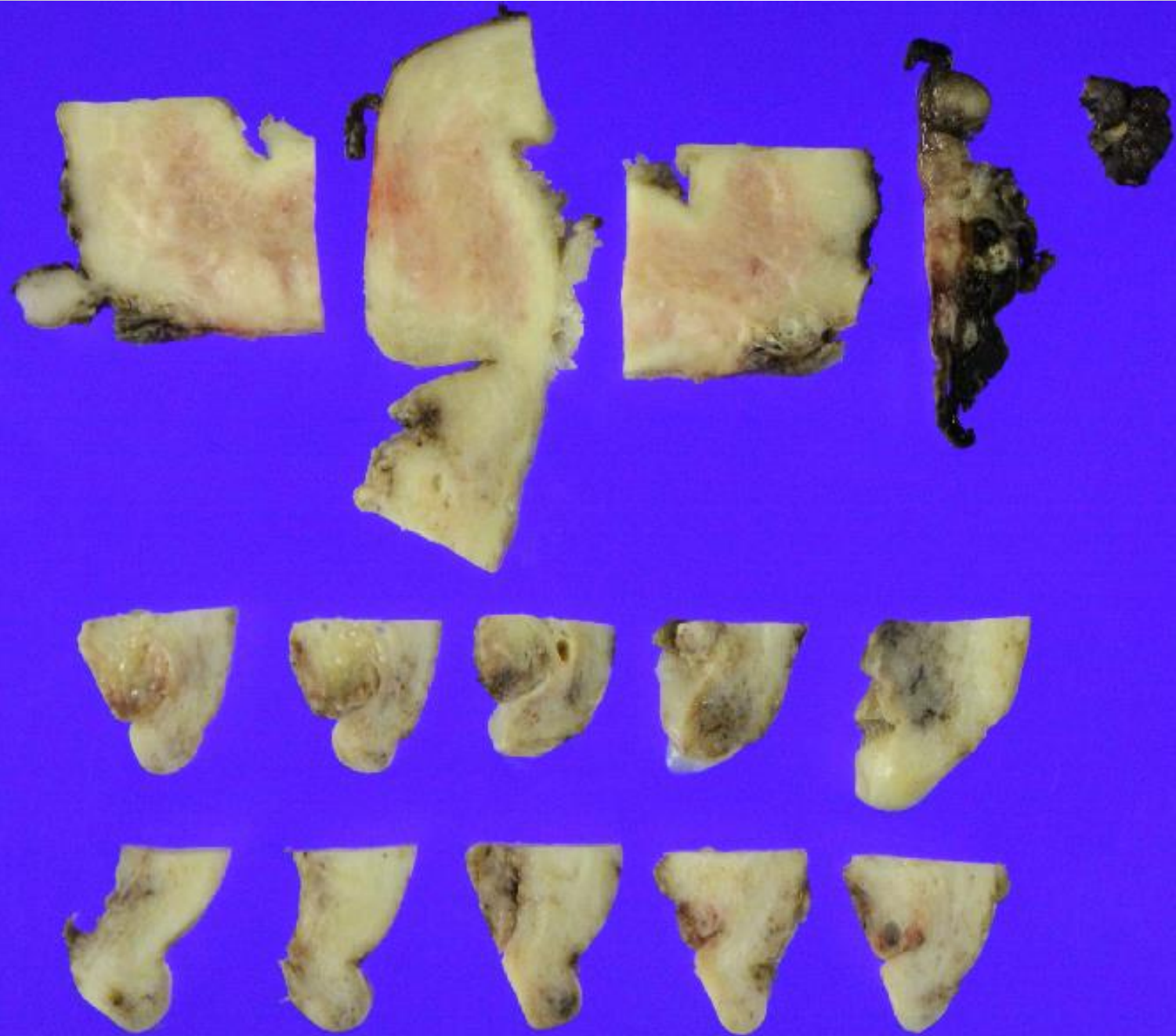
右付属器

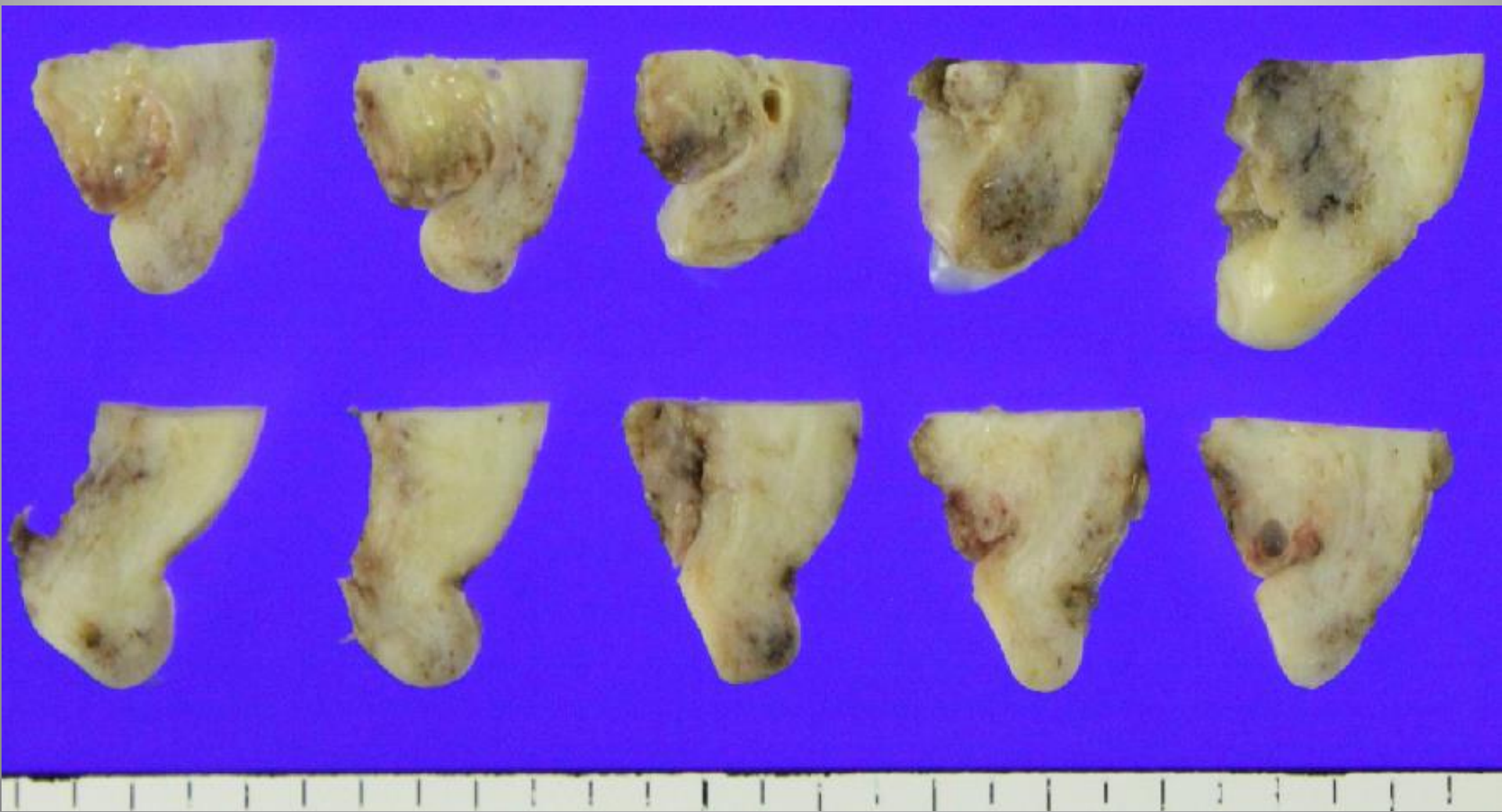




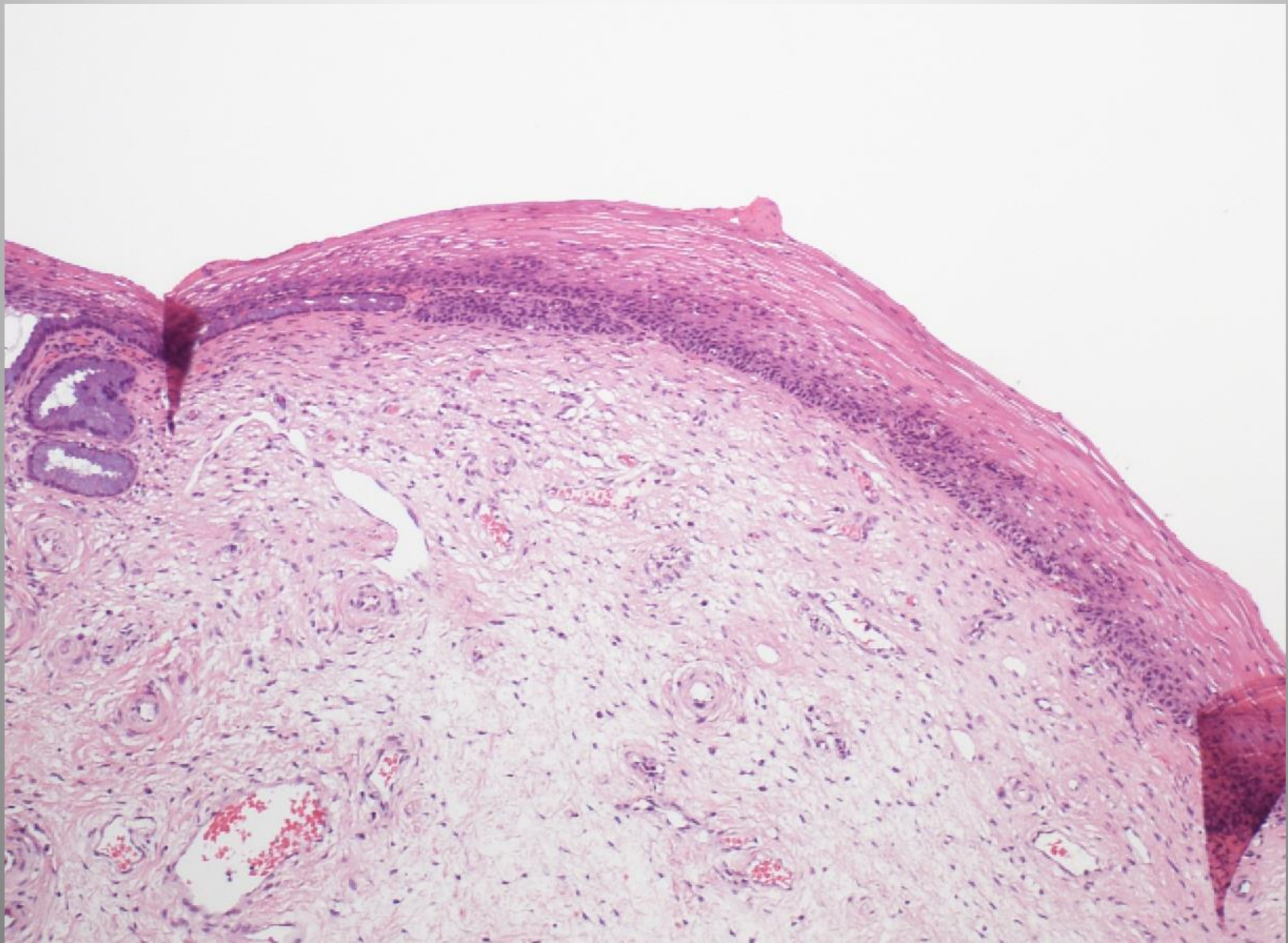




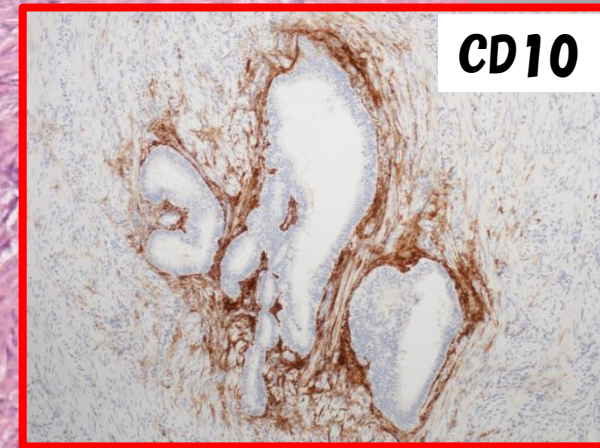
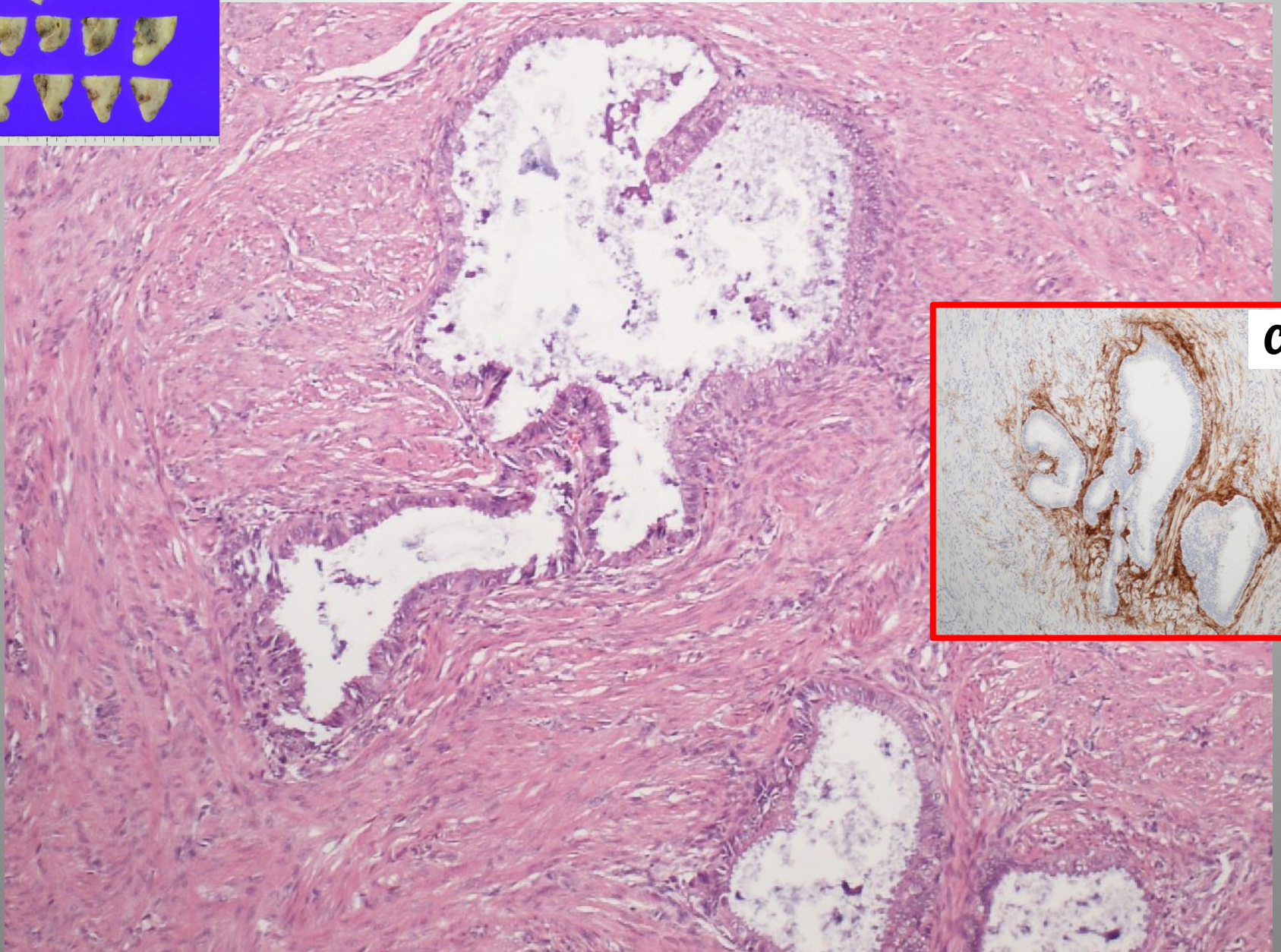
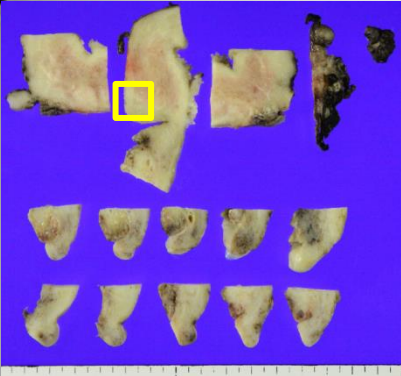




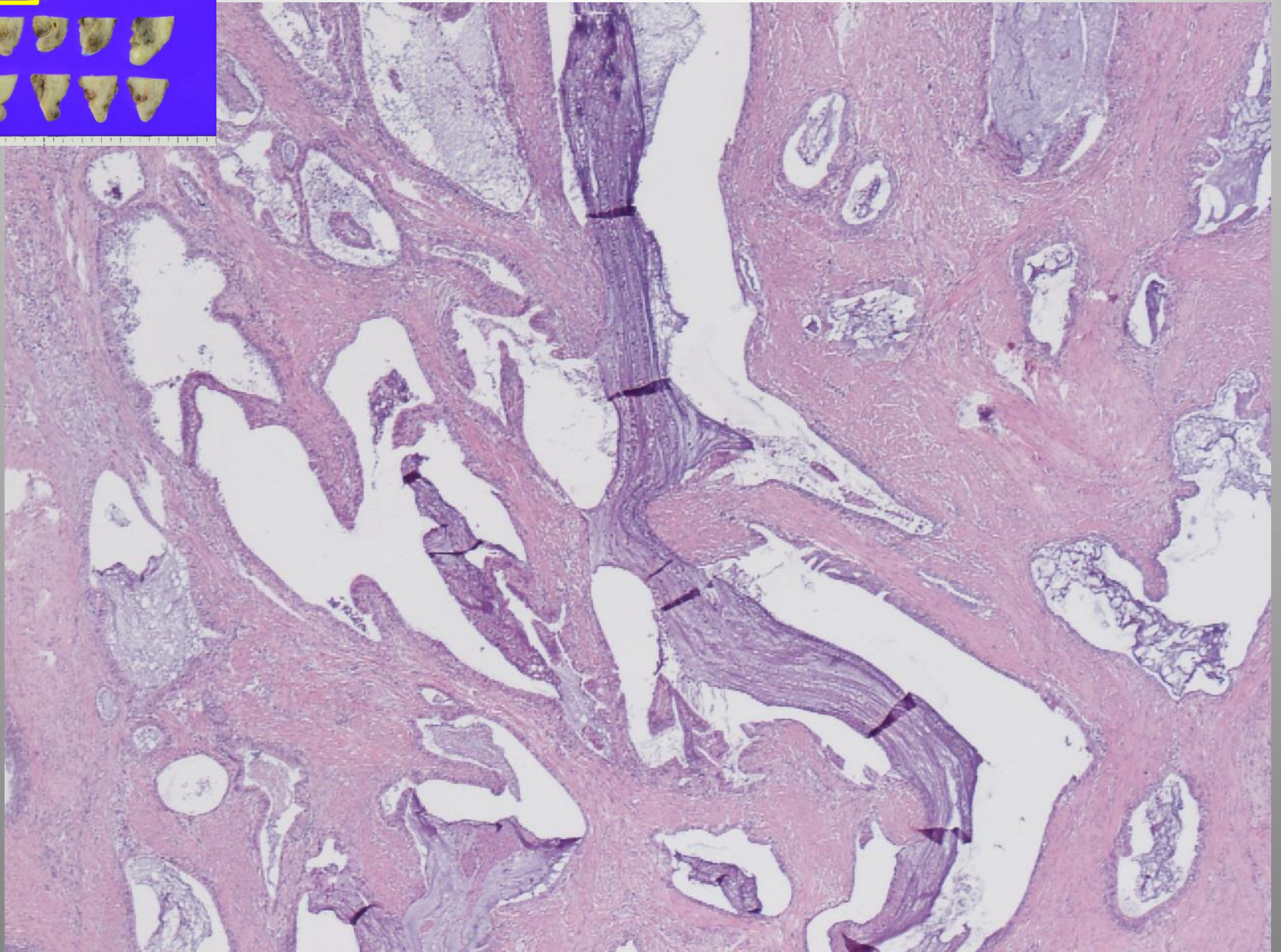
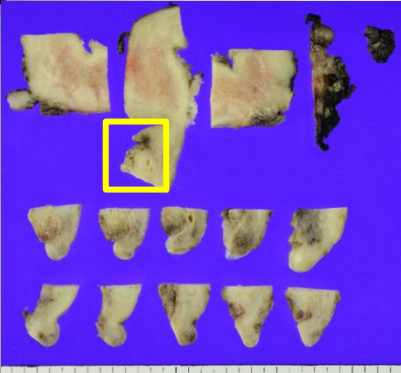
組織所見 子宮頸部



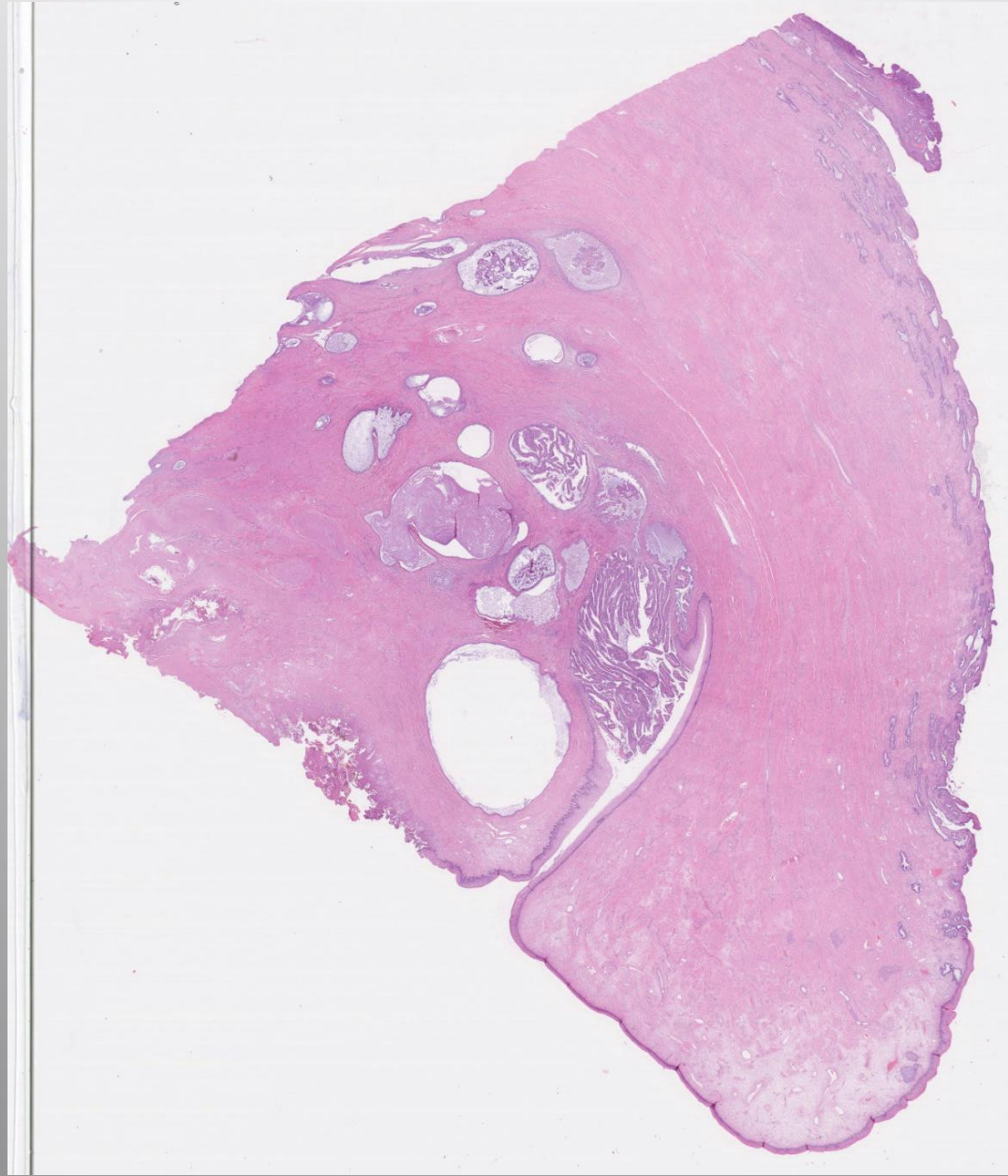
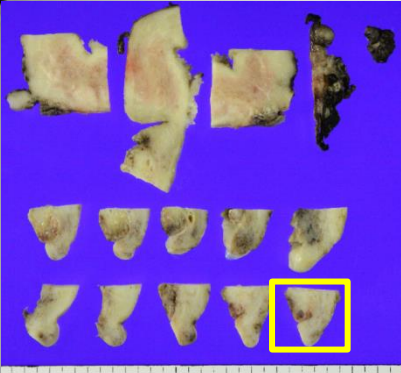
組織所見 子宮



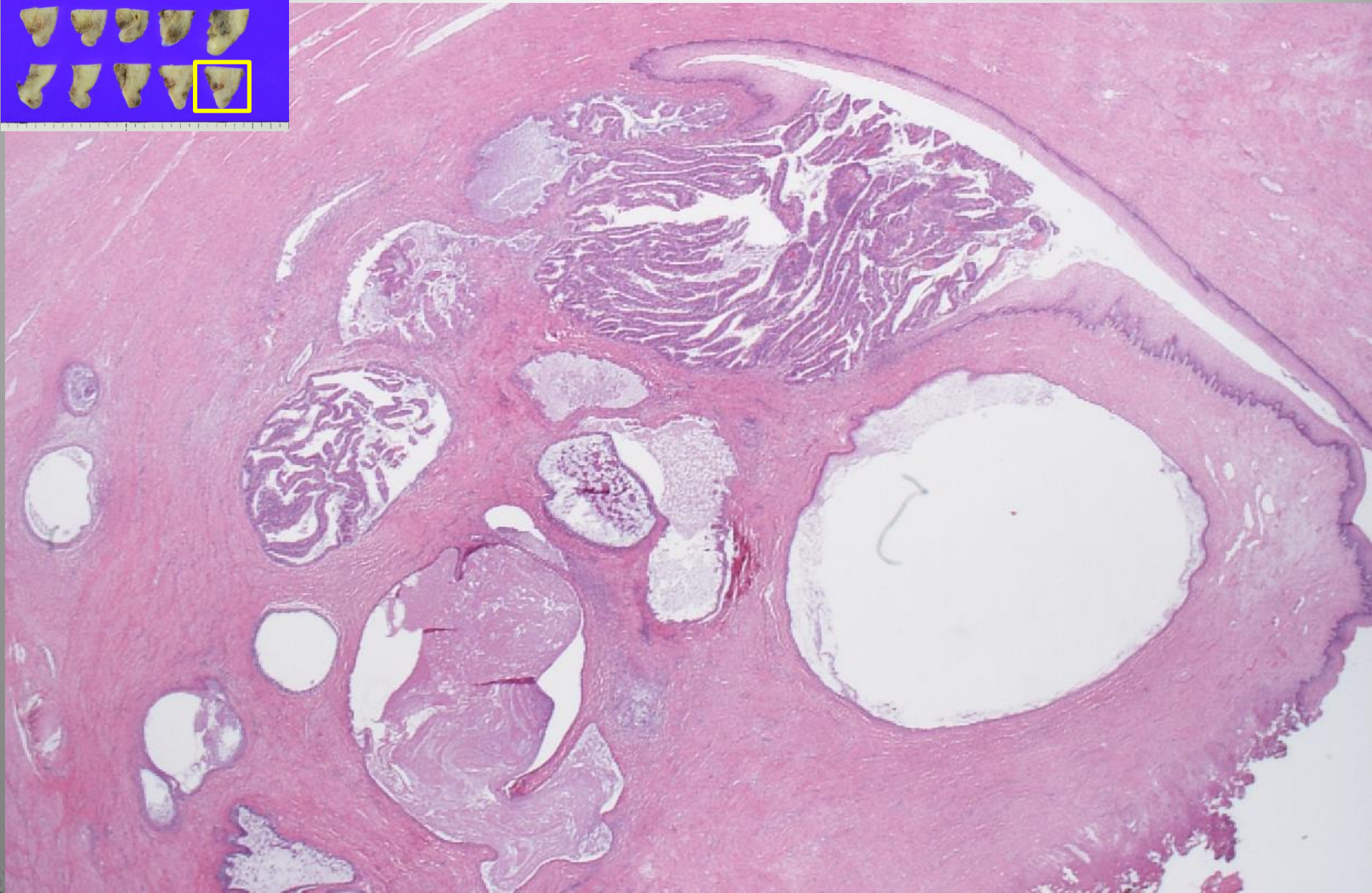
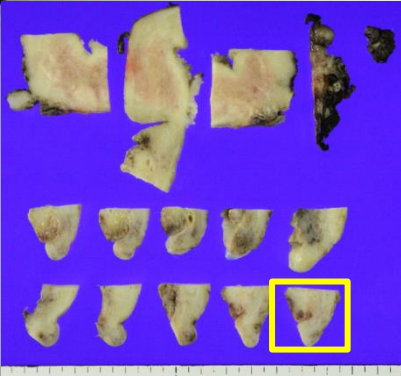
組織所見 子宮



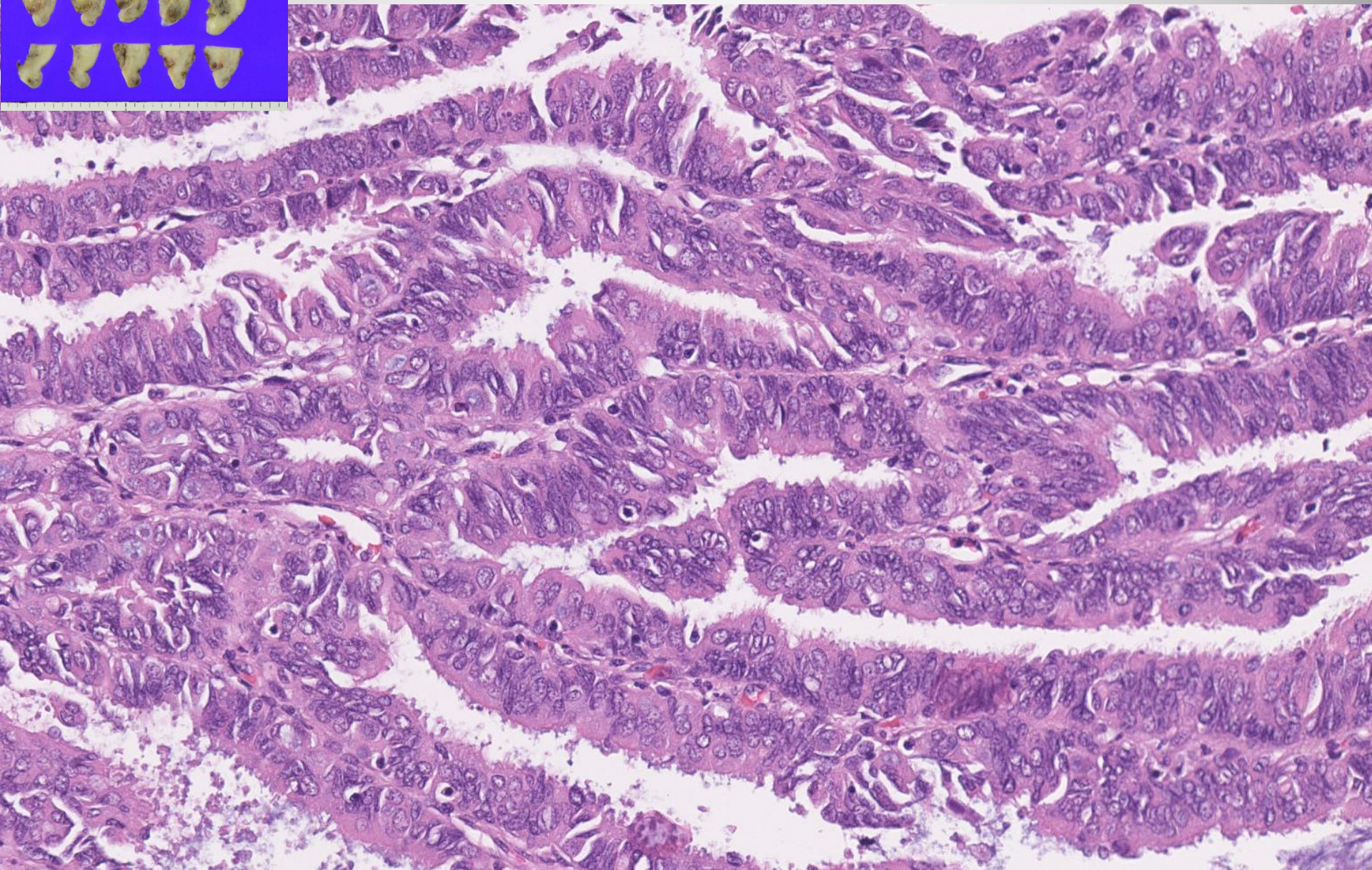
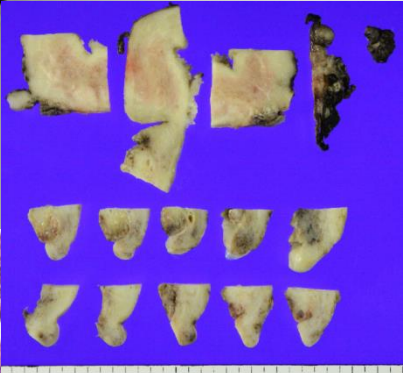
組織所見 子宮



組織所見 子宮



組織所見 子宮



組織所見 子宮

密な乳頭状増生、核異型あり



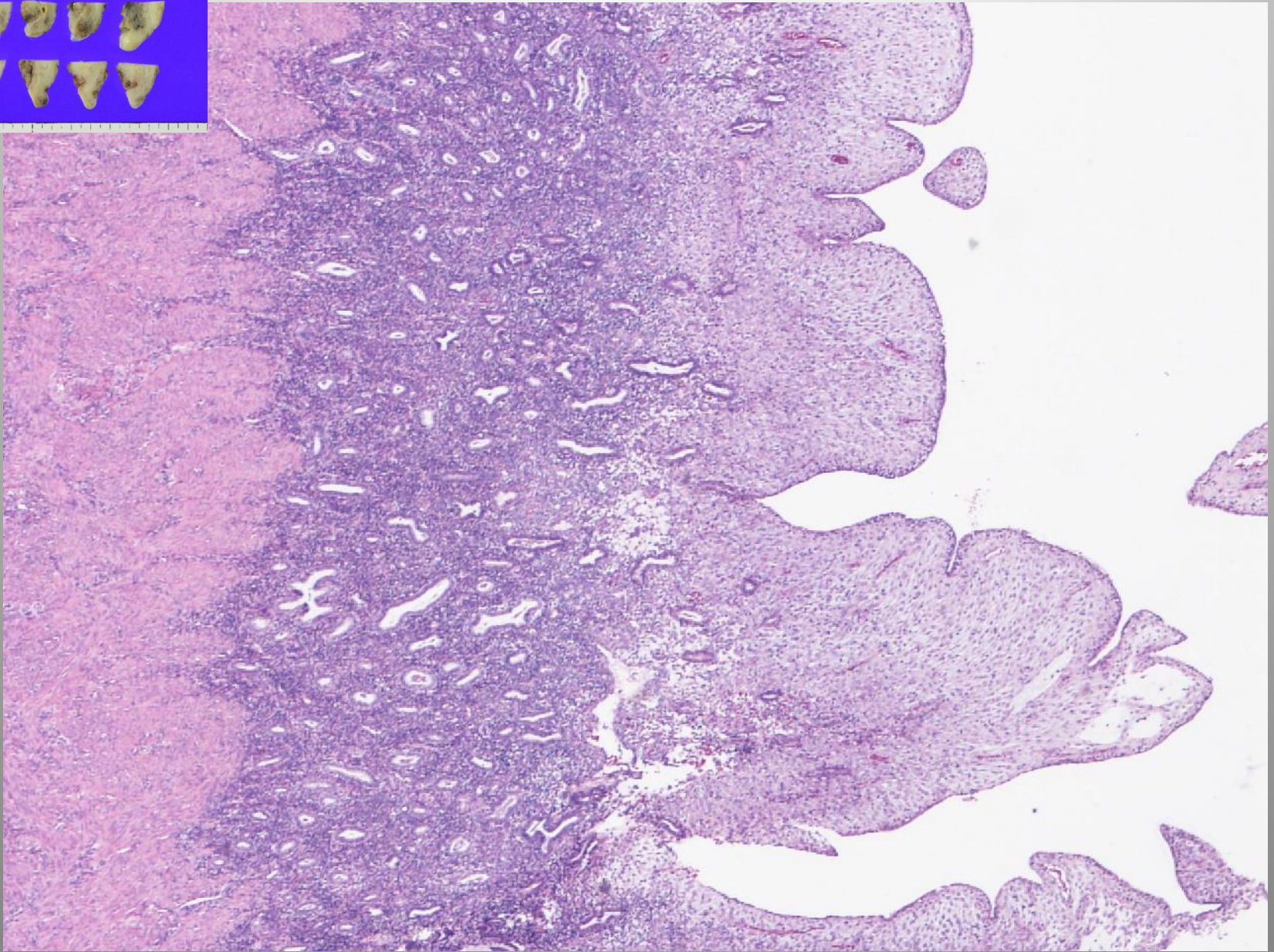
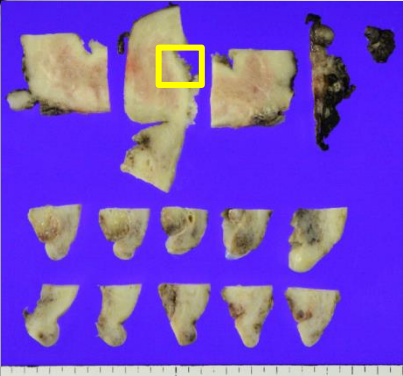
悪性腫瘍？



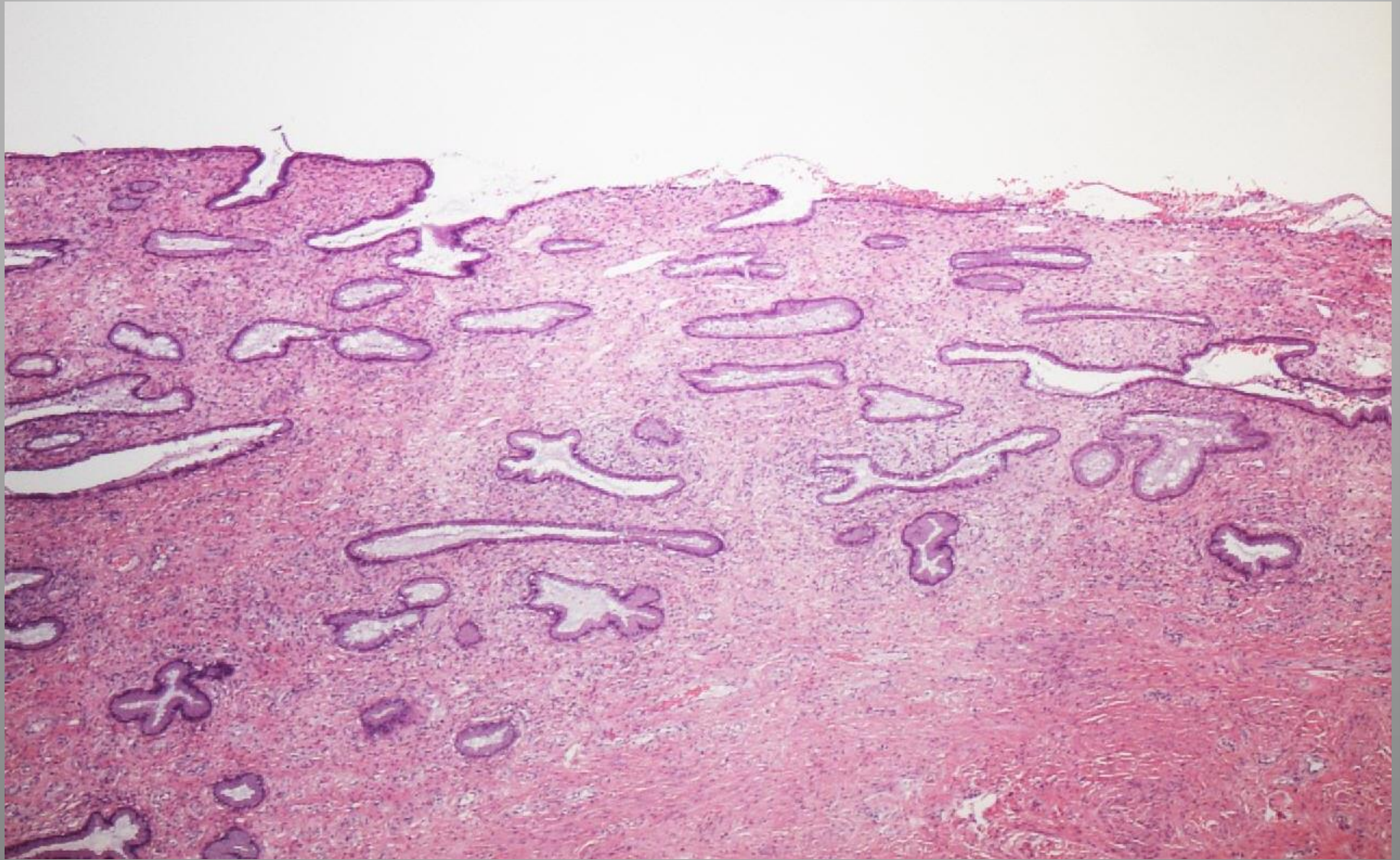
原発は？

- ・子宮内膜からの転移？
- ・頸部内膜からの転移？
- ・中腎管癌？
- ・その他臓器からの転移？
- ・頸部原発？

子宫内膜



子宮頸部



組織所見 子宮

密な乳頭状増生、核異型あり



悪性腫瘍？



原発は？

- ・子宮内膜からの転移？
- ・頸部内膜からの転移？
- ・中腎管癌？
- ・その他臓器からの転移？
- ・頸部原発？

組織所見 子宮

密な乳頭状増生、核異型あり

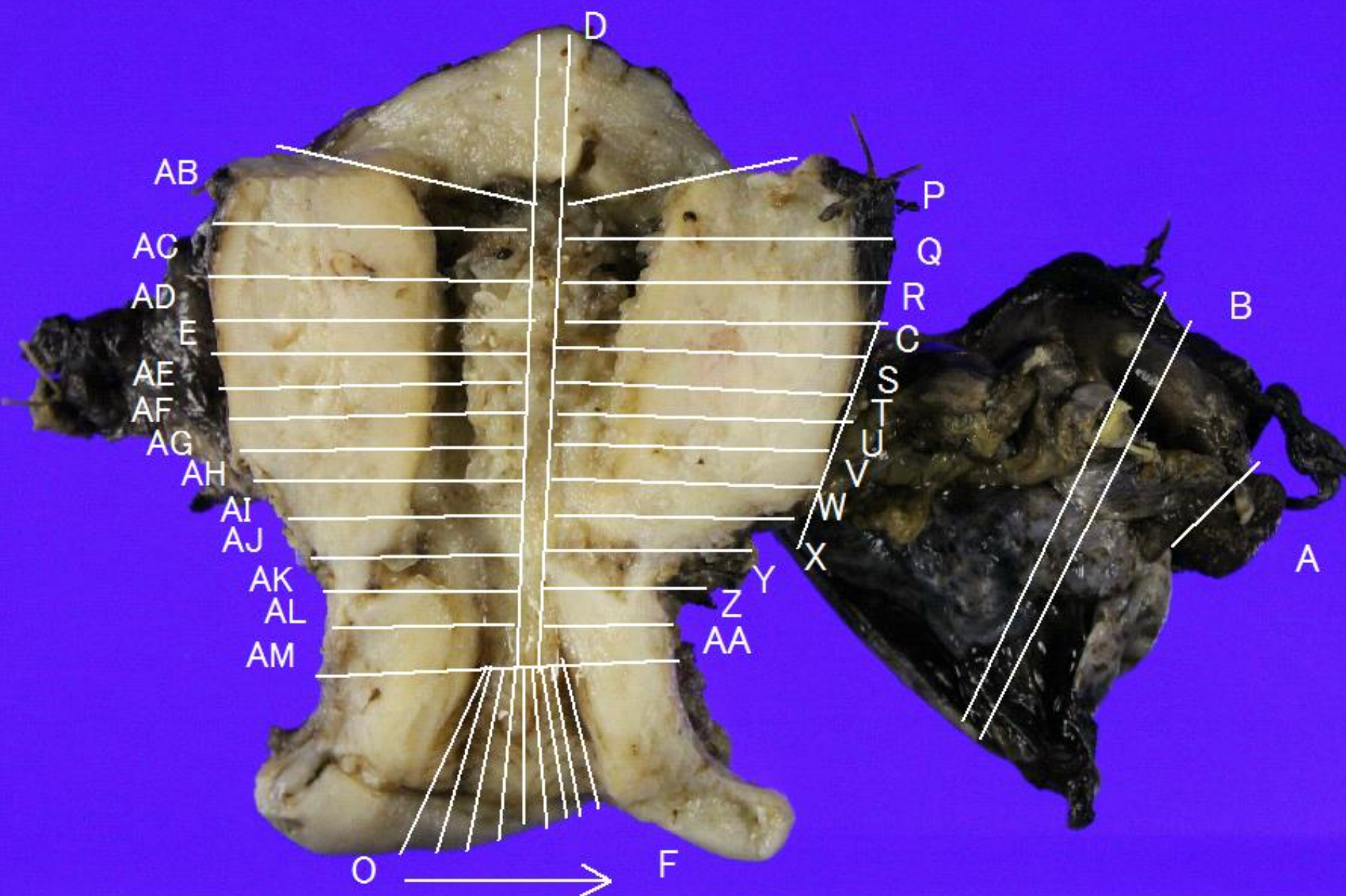


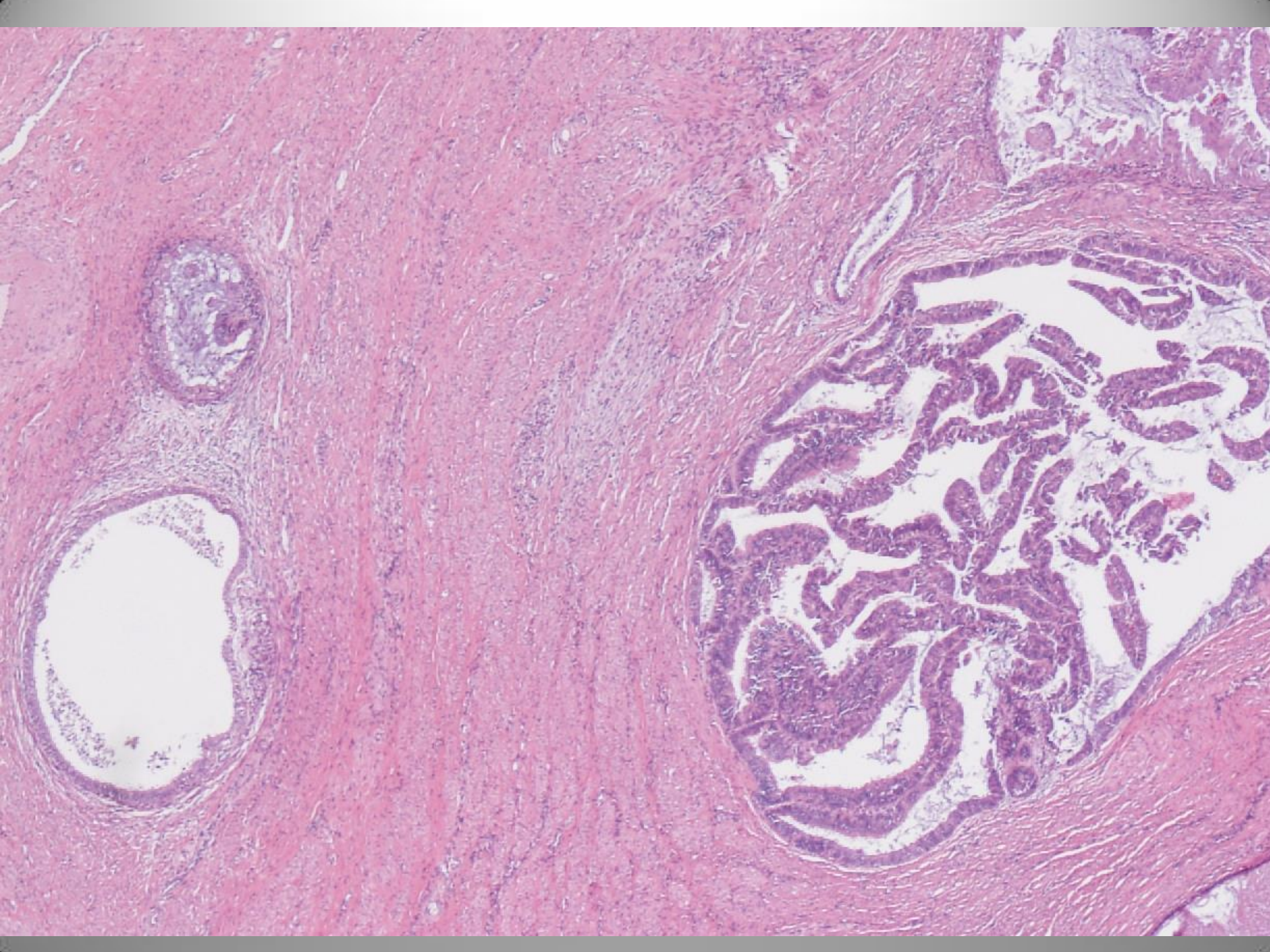
悪性腫瘍？

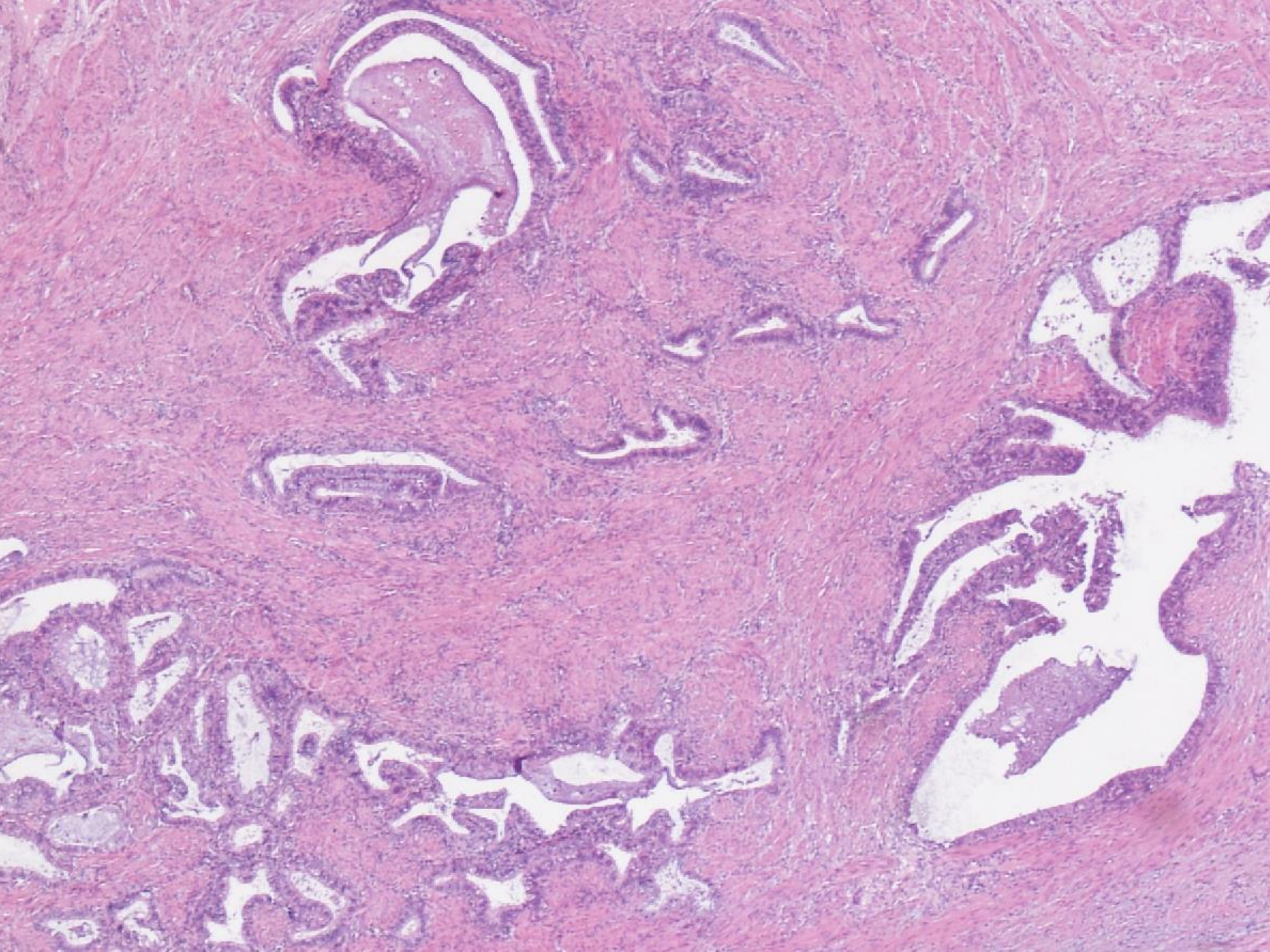


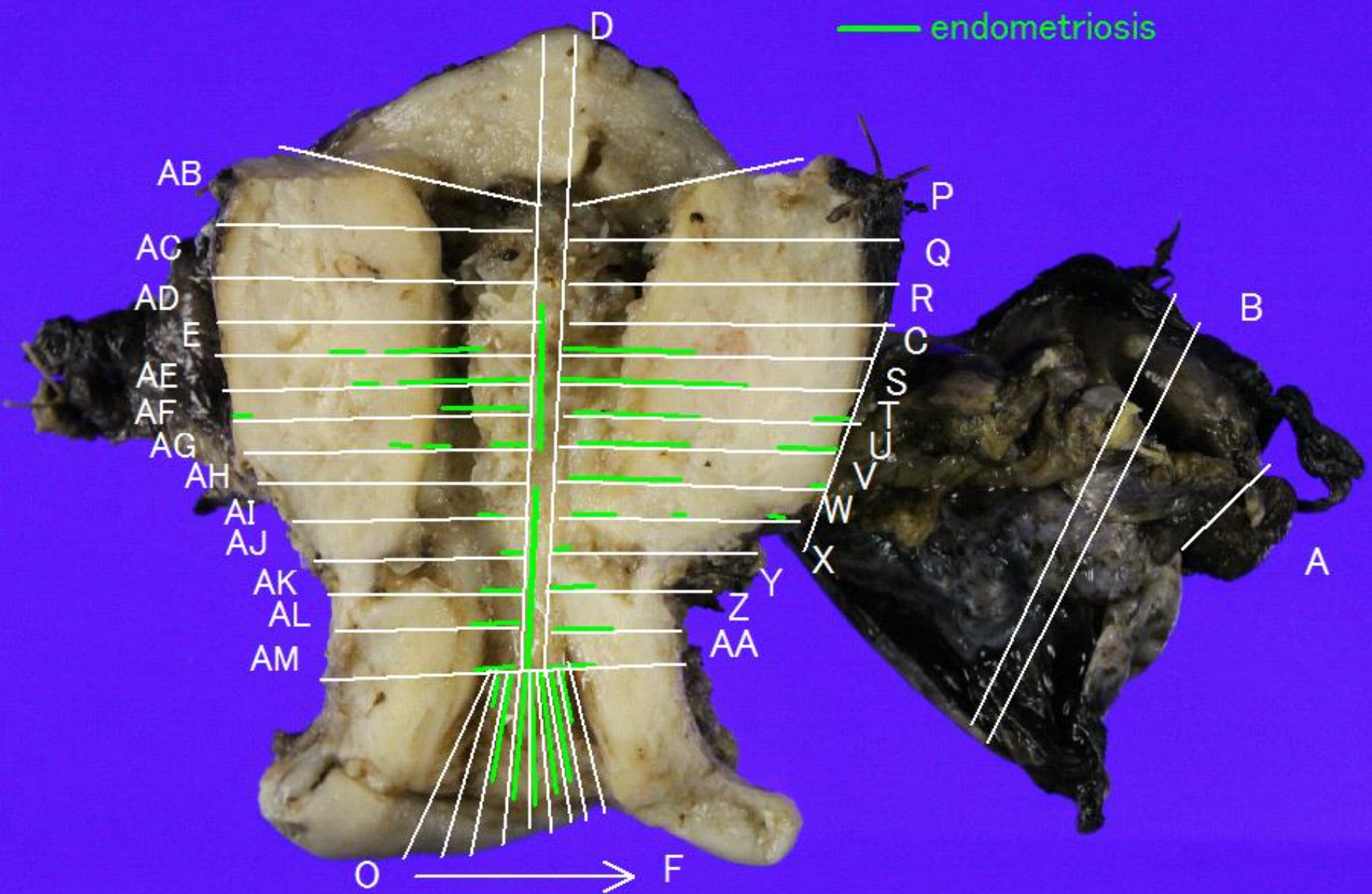
原発は？

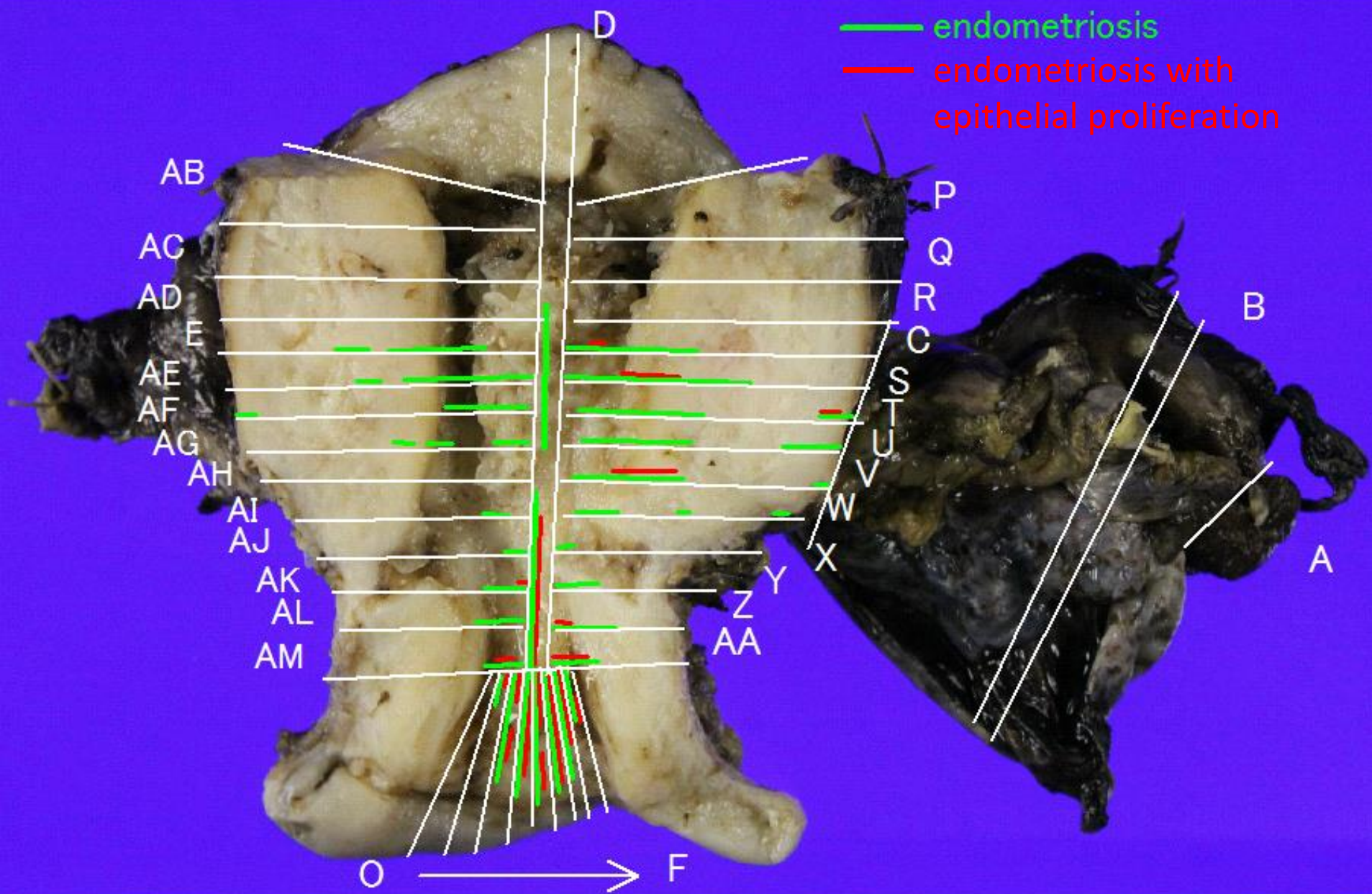
- ・子宮内膜からの転移？
- ・頸部内膜からの転移？
- ・中腎管癌？
- ・その他臓器からの転移？
- ・頸部原発？











組織所見 子宮

密な乳頭状増生、核異型あり

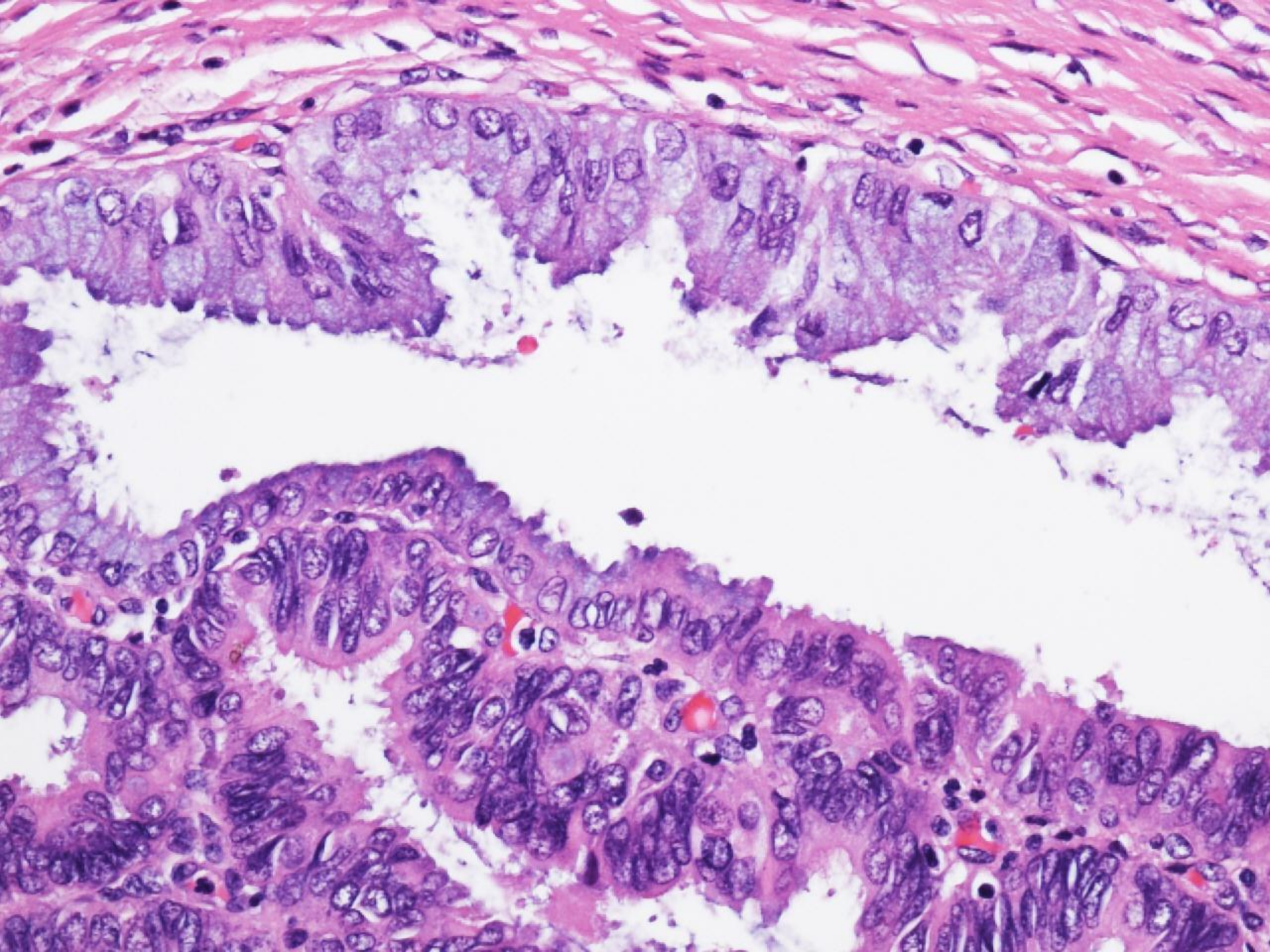


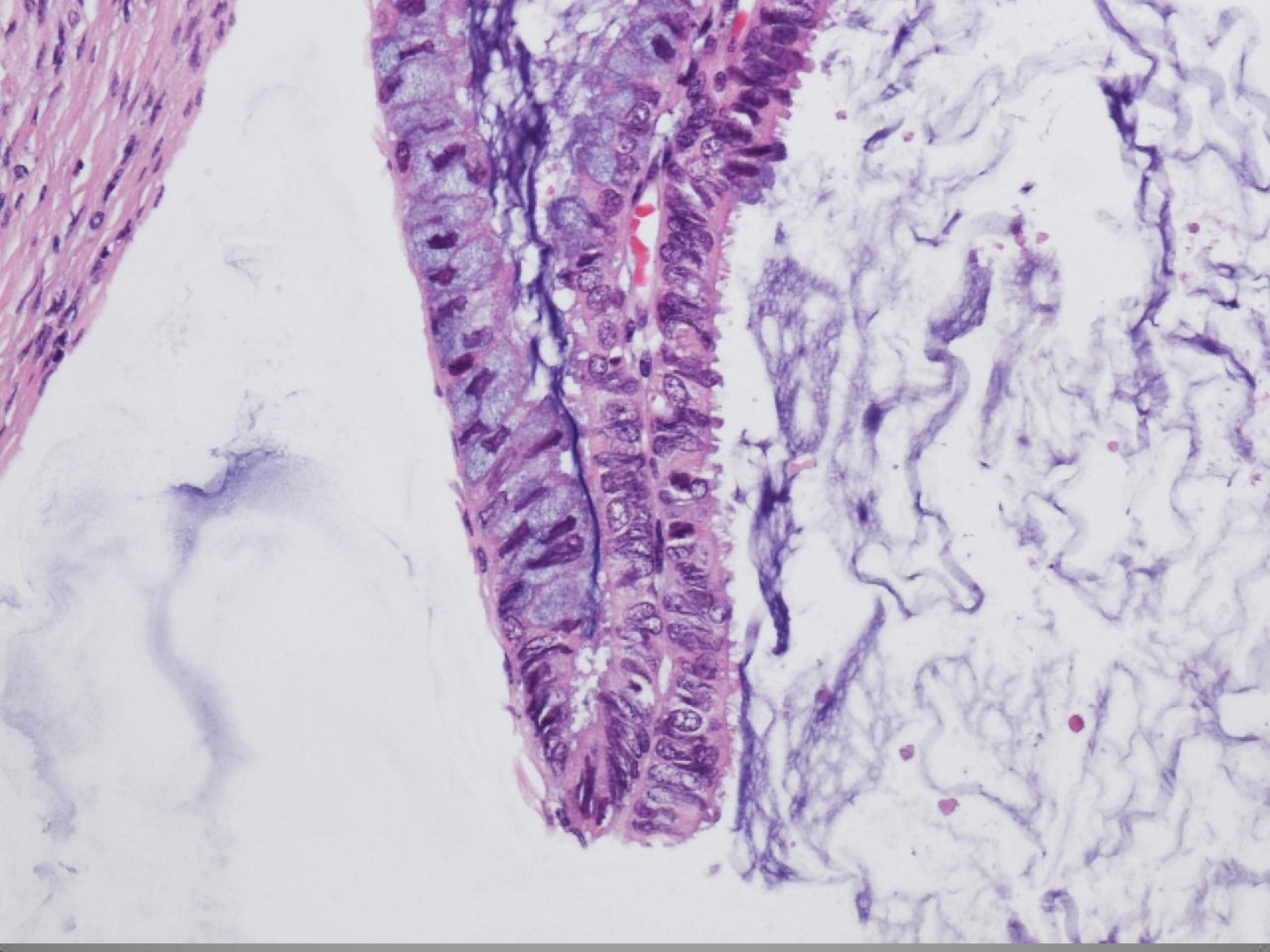
悪性腫瘍？

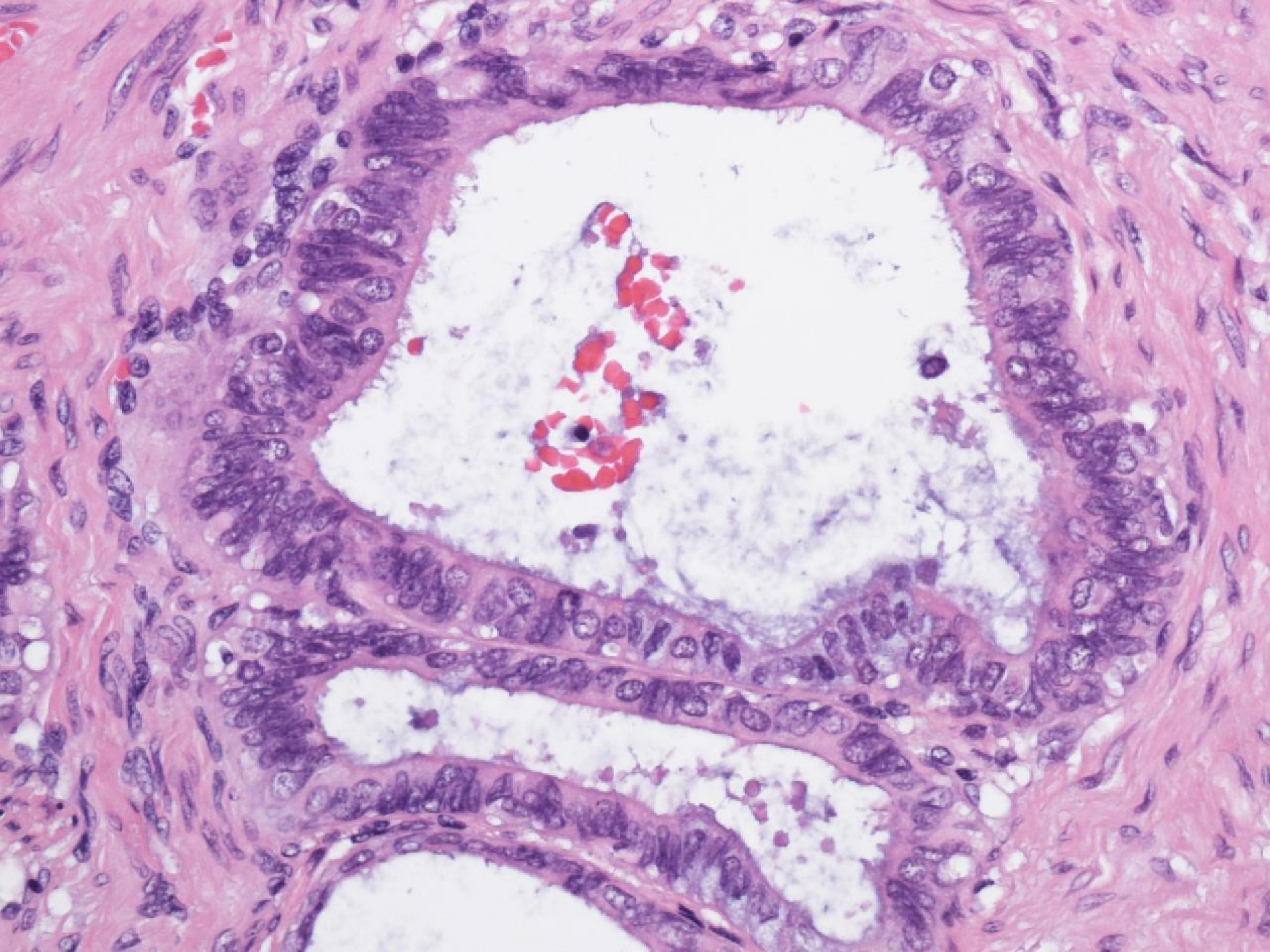


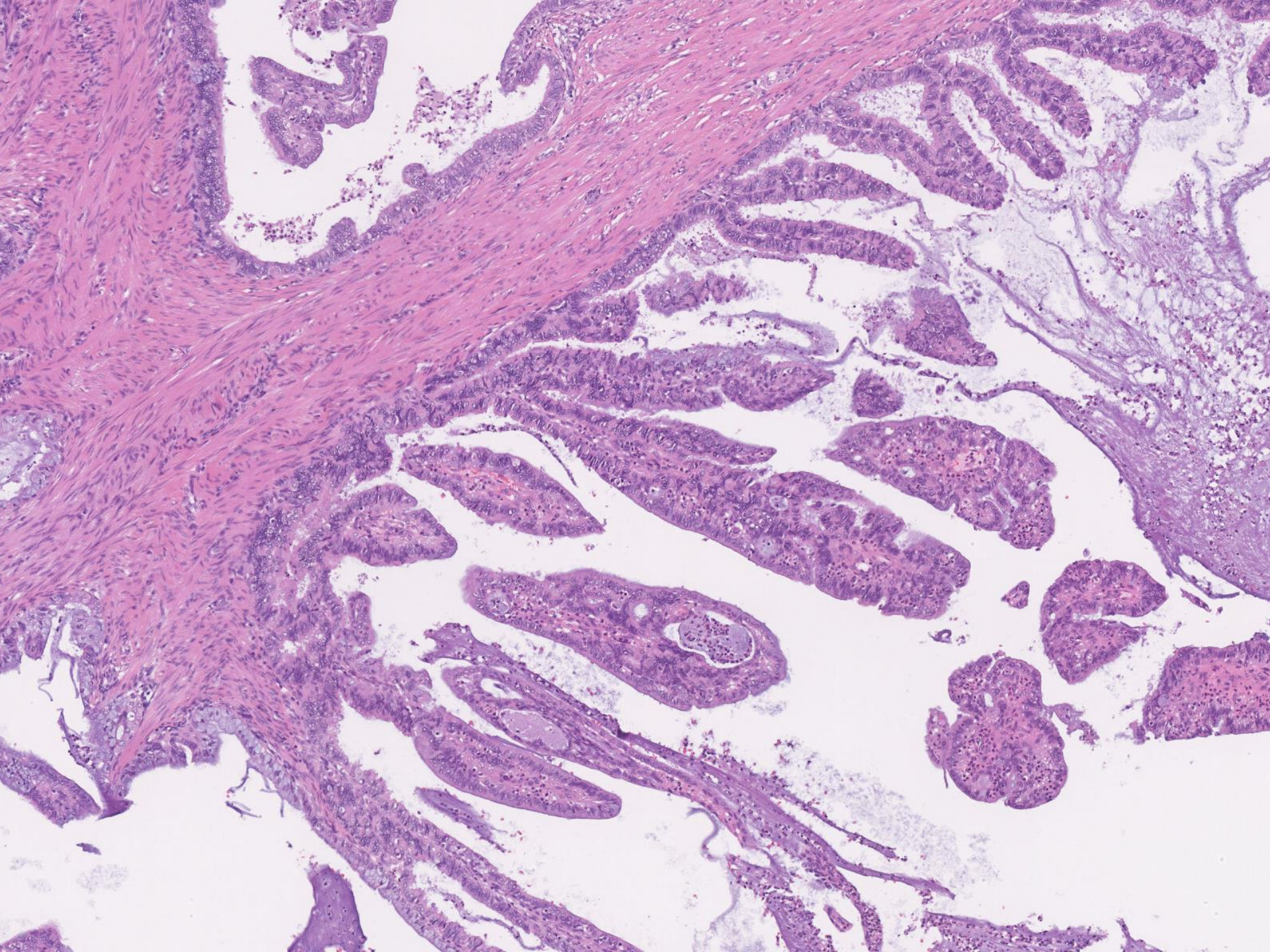
原発は？

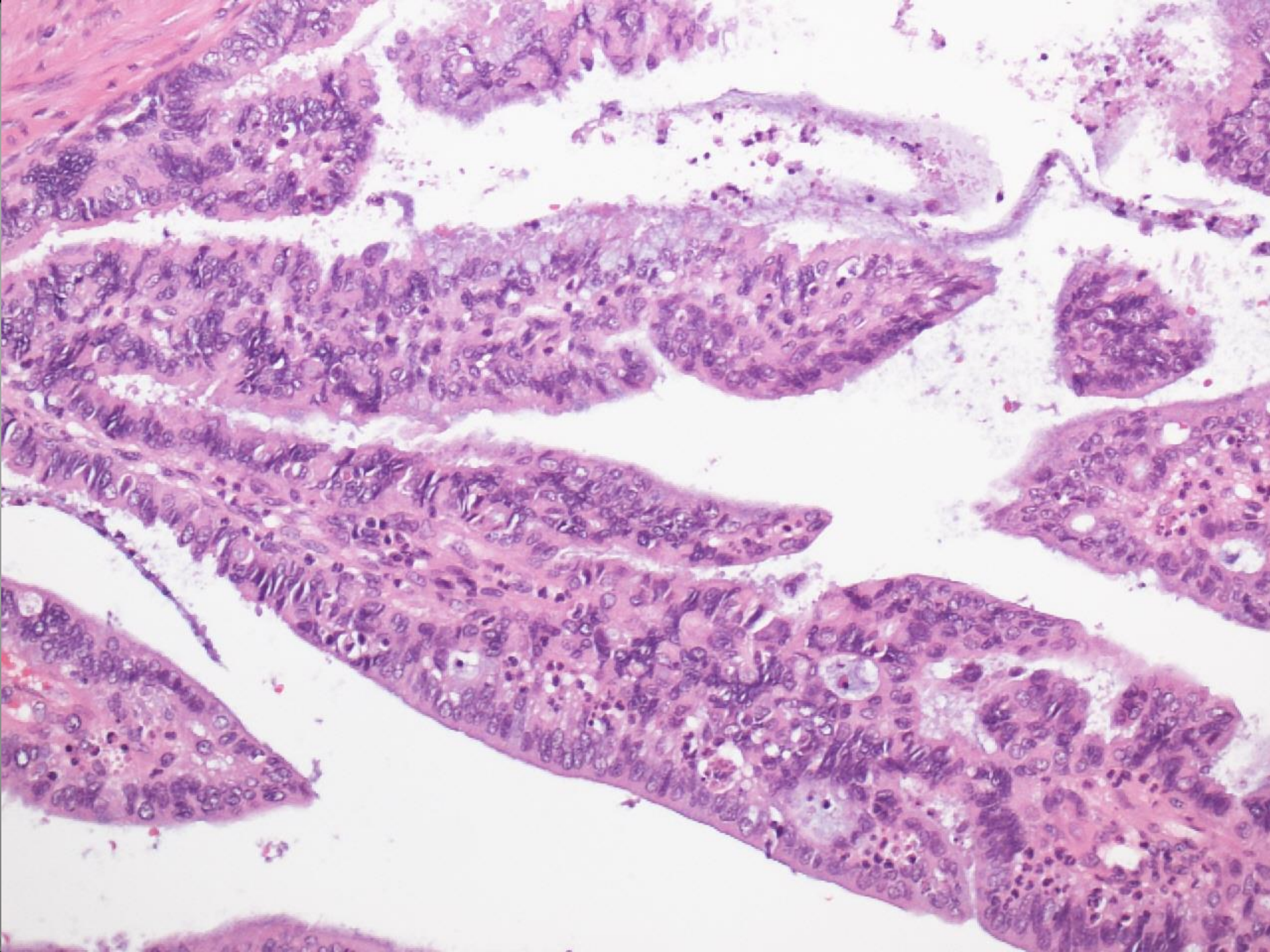
- ・子宮内膜からの転移？
- ・頸部内膜からの転移？
- ・中腎管癌？
- ・その他臓器からの転移？
- ・頸部原発？











Seromucinous borderline tumor

VS

Seromucinous carcinoma

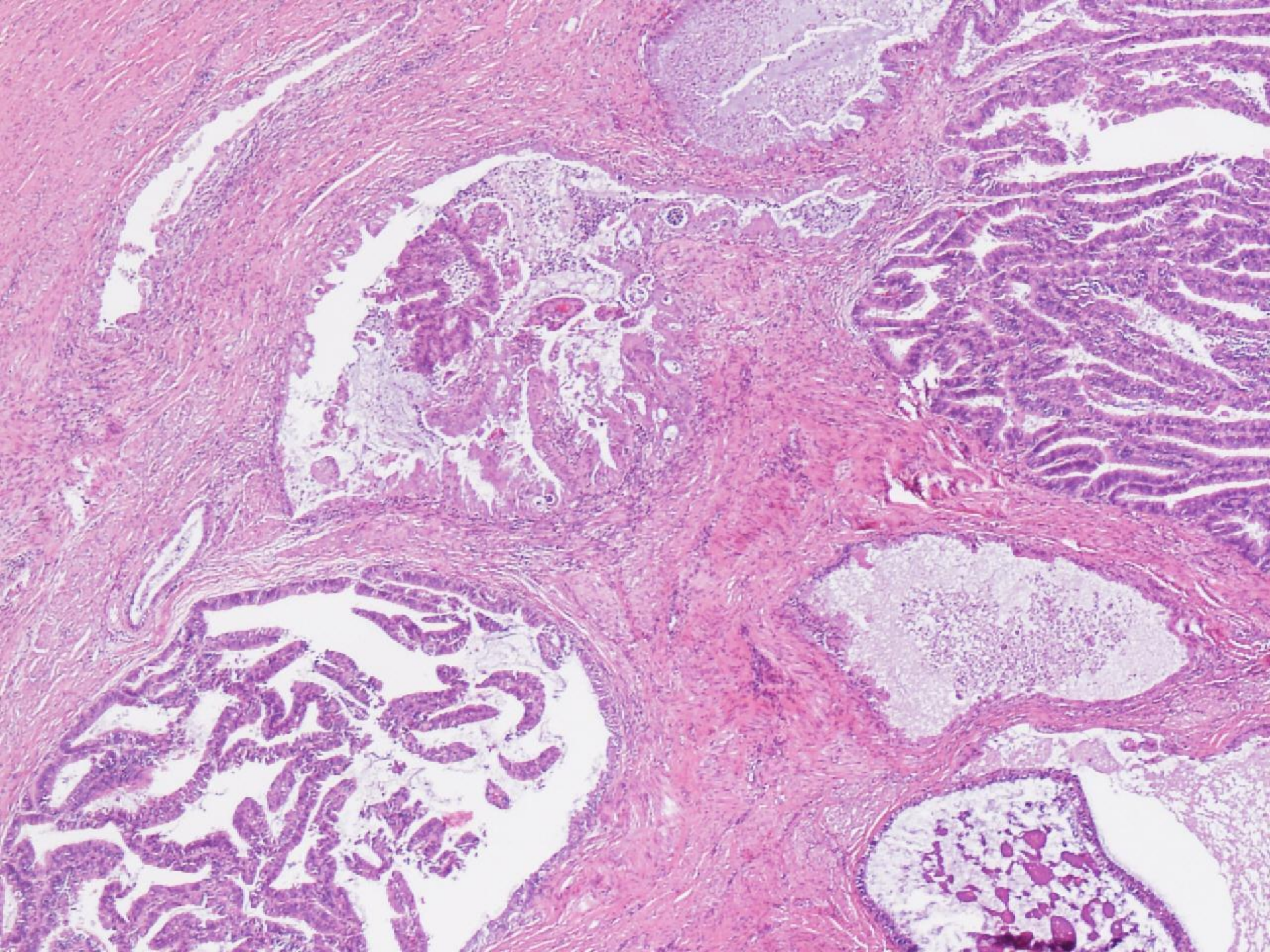
Seromucinous borderline tumor

VS

Seromucinous carcinoma

World Health Organization Classification of Tumors (WHO) 4th edition

“Tumors are generally papillary and display epithelial stratification closely resembling serous tumors. The most common pattern of invasion is cribriform and confluent (expansile), although destructive infiltrative growth also occurs. . . .”



Seromucinous borderline tumor

子宮頸部endometriosis発生^のadenocarcinoma

“Adenocarcinoma arising within cervical endometriosis and invading the adjacent vagina” [Am J Obstet Gynecol.](#) 1971 Aug 1;110(7):1015-7. [Chang SH](#)

頸部endometriosisから発生したendometrioid adenocarcinoma

“Endometriosis adenocarcinoma arising from endometriosis of the uterine cervix: A case report” [J Korean Med Sci.](#) 2009 Aug;24(4):767-71. [Park HM](#)

頸部endometriosisと連続したendometrioid adenocarcinoma

“Clear cell adenocarcinoma of the uterine cervix arising from a background of the cervical endometriosis” [Br J Radiol.](#) 2009 Jan;82(973):e20-2. [Hiromura T](#)

頸部endometriosisに隣接したClear cell carcinoma

“MR Imaging finding of extraovarian endocervical mucinous borderline tumors arising from pelvic endometriosis” [Korean J Radiol.](#) 2013 Nov-Dec;14(6):918-22. [Yeo DM](#)

(Pelvic) endometriosisに連続したmucinous borderline tumor

“Clear cell carcinoma of the uterine cervix presented as submucosal tumor arising from a background of cervical endometriosis” [Int J Gynecol Pathol.](#) 2017 Mar 8. [Hashiguchi M](#)

頸部endometriosisに隣接したClear cell carcinoma

子宮頸部endometriosis発生^のadenocarcinoma

“Adenocarcinoma arising within cervical endometriosis and invading the adjacent vagina” [Am J Obstet Gynecol.](#) 1971 Aug 1;110(7):1015-7. [Chang SH](#)

頸部endometriosisから発生したendometrioid adenocarcinoma

“Endometriosis adenocarcinoma arising from endometriosis of the uterine cervix: A case report” [J Korean Med Sci.](#) 2009 Aug;24(4):767-71. [Park HM](#)

頸部endometriosisと連続したendometrioid adenocarcinoma

“Clear cell adenocarcinoma of the uterine cervix arising from a background of the cervical endometriosis” [Br J Radiol.](#) 2009 Jan;82(973):e20-2. [Hiromura T](#)

頸部endometriosisに隣接したClear cell carcinoma

“MR Imaging finding of extraovarian endocervical mucinous borderline tumors arising from pelvic endometriosis” [Korean J Radiol.](#) 2013 Nov-Dec;14(6):918-22. [Yeo DM](#)

(Pelvic) endometriosisに連続したmucinous borderline tumor

“Clear cell carcinoma of the uterine cervix presented as submucosal tumor arising from a background of cervical endometriosis” [Int J Gynecol Pathol.](#) 2017 Mar 8. [Hashiguchi M](#)

頸部endometriosisに隣接したClear cell carcinoma

子宮頸部 endometriosis 発生 の adenocarcinoma

MR Imaging Findings of Extraovarian Endocervical Mucinous Borderline Tumors Arising from Pelvic Endometriosis

Dong Myung Yeo, MD¹, Sung Eun Rha, MD¹, Jae Young Byun, MD¹, Ahwon Lee, MD², Mee-Ran Kim, MD³

Departments of ¹Radiology, ²Hospital Pathology, and ³Obstetrics and Gynecology, Seoul St. Mary's Hospital, The Catholic University of Korea, Seoul 137-701, Korea

※卵巣腫瘍の場合

- 癌と内膜症の両者が存在
- 内膜症由来の組織型 (endometrioid, clear cell)
- 他に原発がない
- *dysplastic phase* があること → *Atypical endometriosis*
- 両者の移行像があること (36-42%)

子宮頸部endometriosis発生のadenocarcinoma

MR Imaging Findings of Extraovarian Endocervical Mucinous Borderline Tumors Arising from Pelvic Endometriosis

Dong Myung Yeo, MD¹, Sung Eun Rha, MD¹, Jae Young Byun, MD¹, Ahwon Lee, MD², Mee-Ran Kim, MD³

Departments of ¹Radiology, ²Hospital Pathology, and ³Obstetrics and Gynecology, Seoul St. Mary's Hospital, The Catholic University of Korea, Seoul 137-701, Korea

※卵巣腫瘍の場合

- 癌と内膜症の両者が存在
- 内膜症由来の組織型 (endometrioid, clear cell)
- 他に原発がない
- *dysplastic phase*があること → *Atypical endometriosis*
- 両者の移行像があること (36 - 42%)



Endometriosisから発生した腫瘍

最終診断

***Seromucinous borderline tumor,
arising from endometriosis
of the uterine cervix.***