

症例 60歳代 女性

【現病歴】

約4年前から左耳下部に腫瘍を自覚し、徐々に増大した。

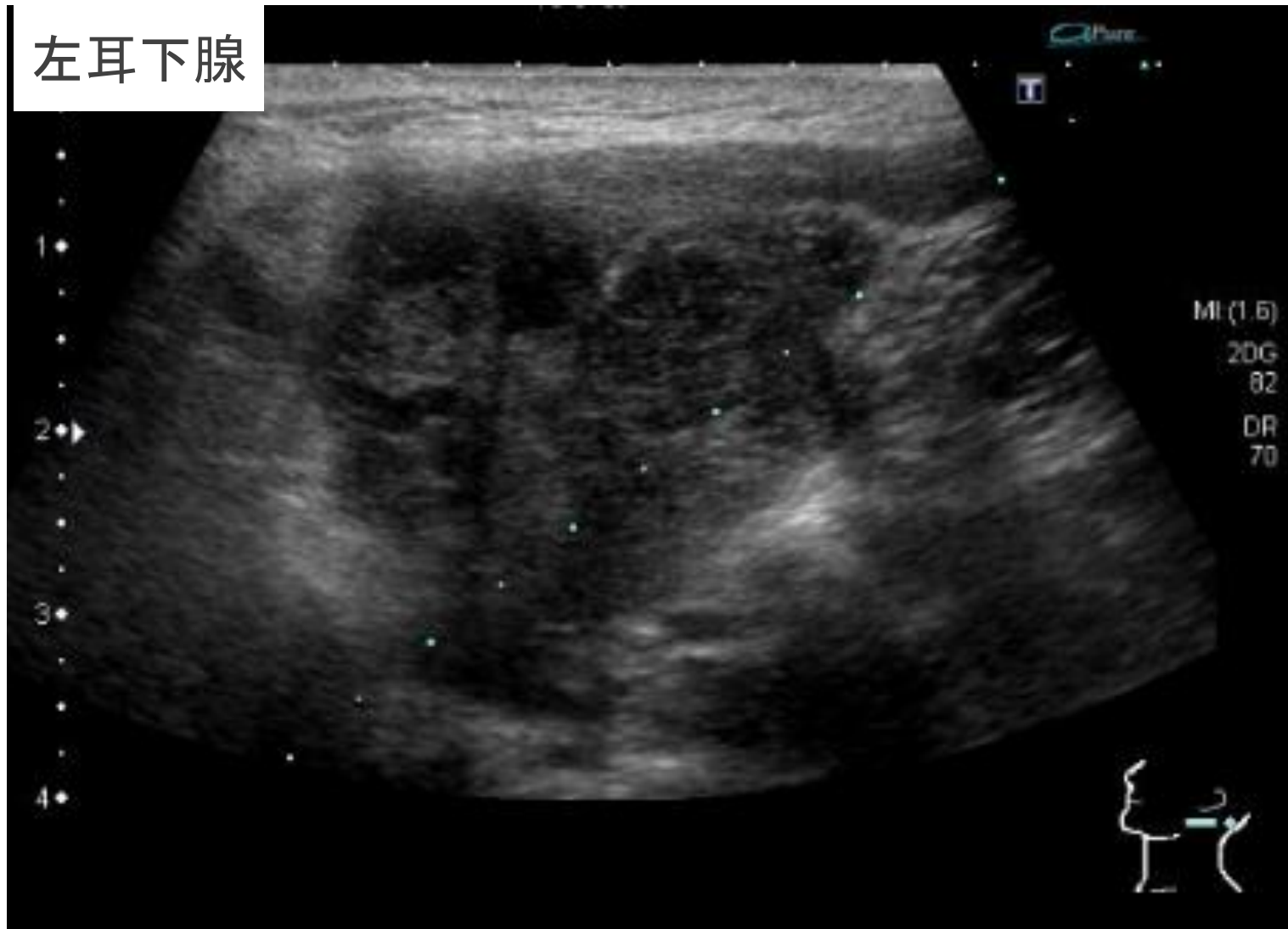【既往歴】 特記なし

【生活歴】 喫煙歴なし、飲酒歴なし

【自覚症状】 疼痛スケール1/10のチクチクする痛み

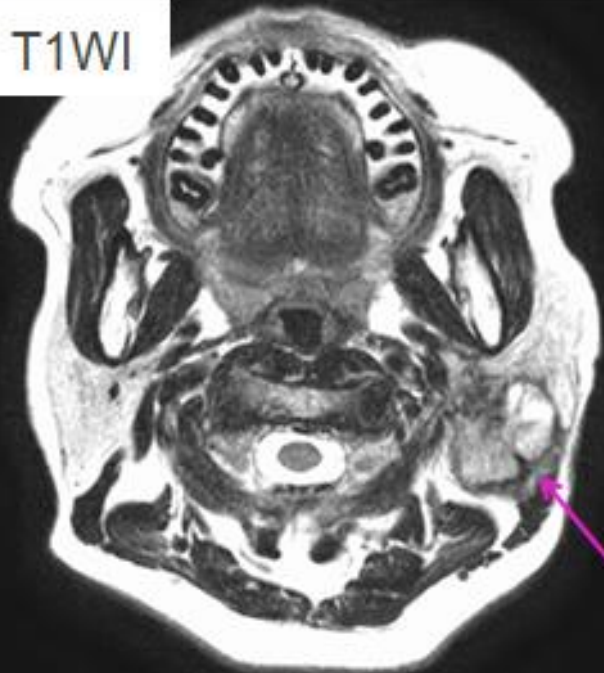
超音波検査

左耳下腺

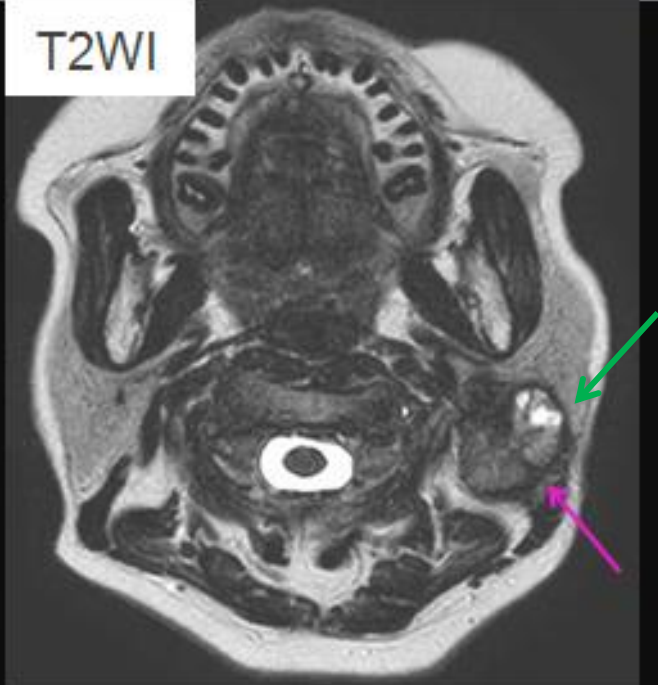

MRI検査

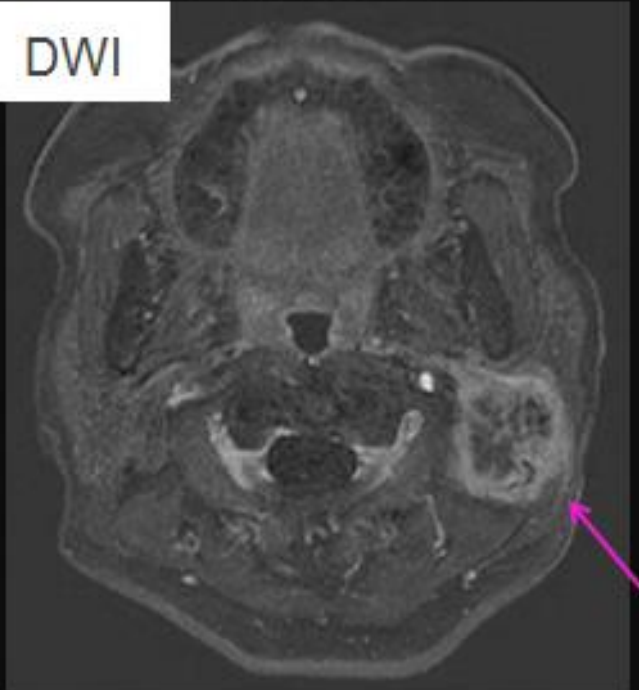
T1WI



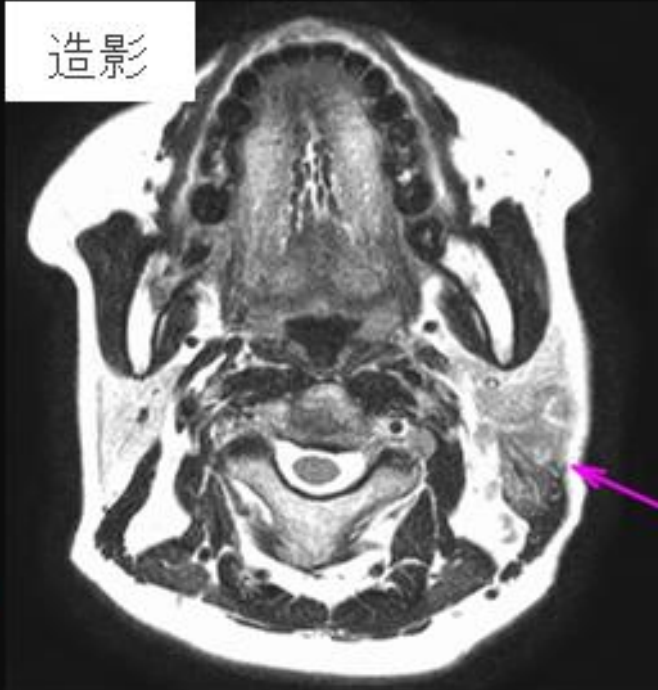T2WI



DWI



造影

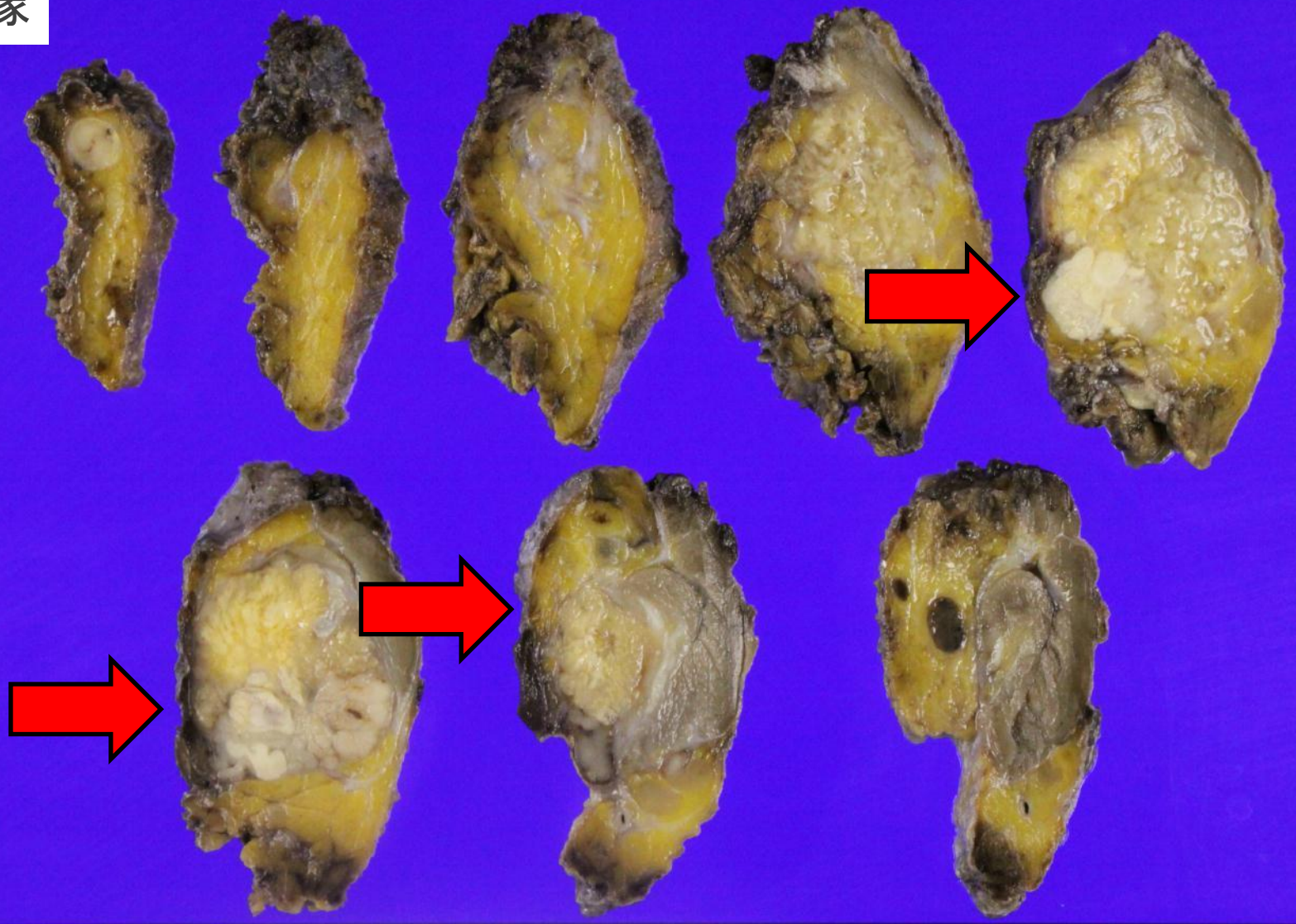


左耳下腺全摘術＋頸部郭清術施行

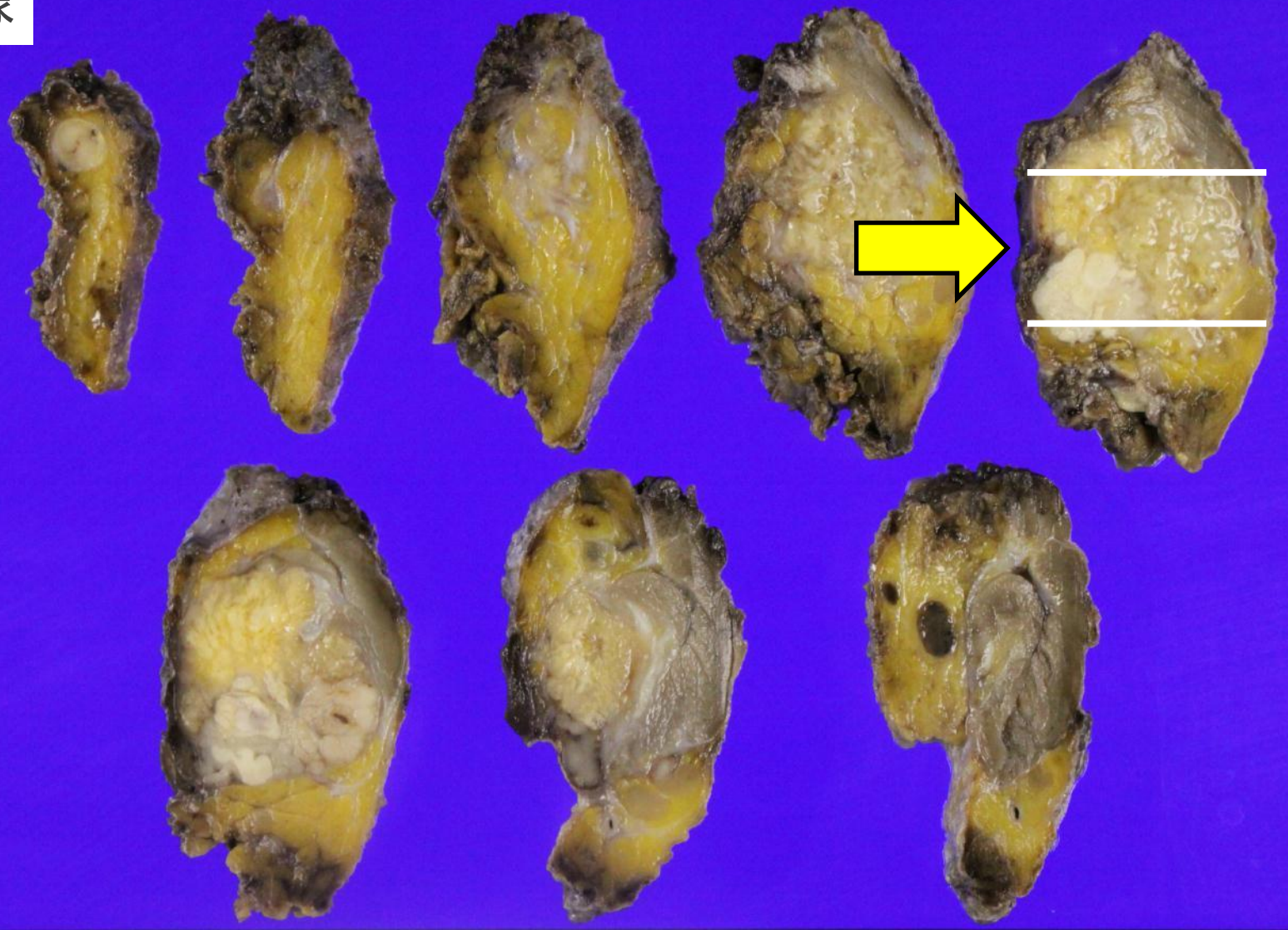
肉眼像



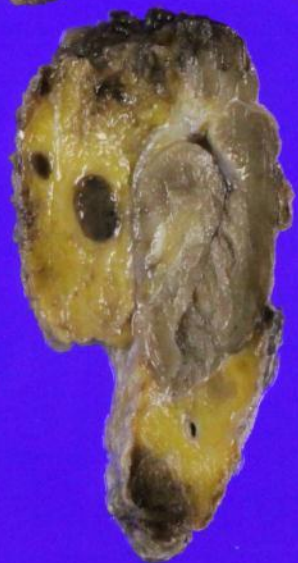
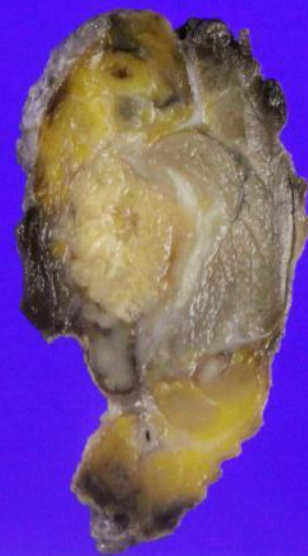
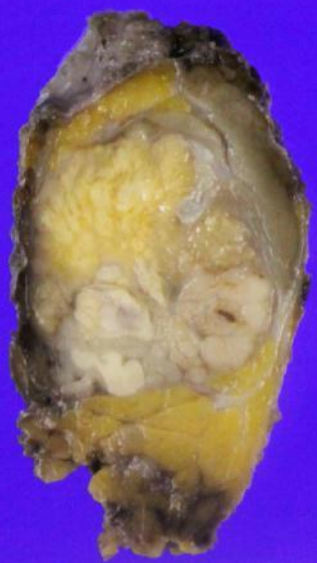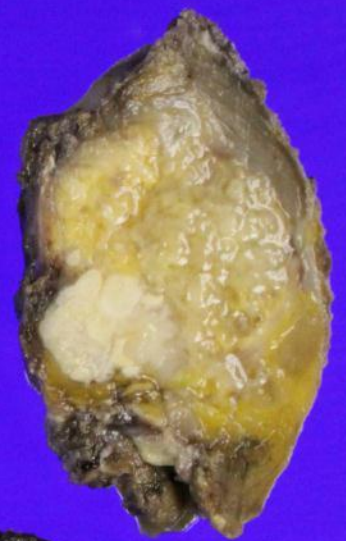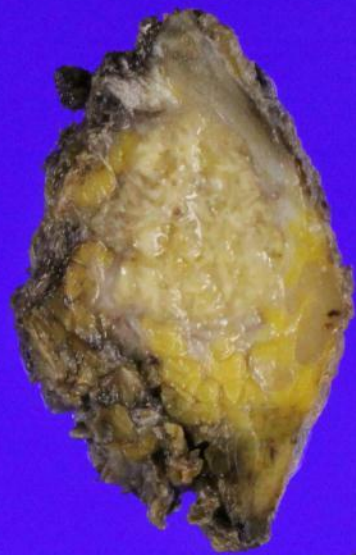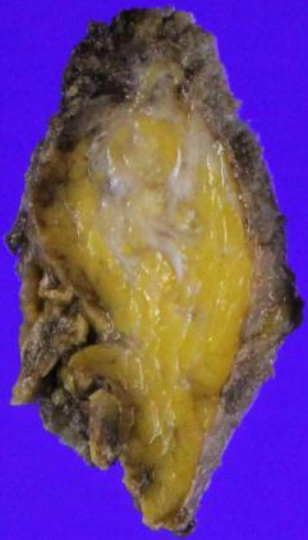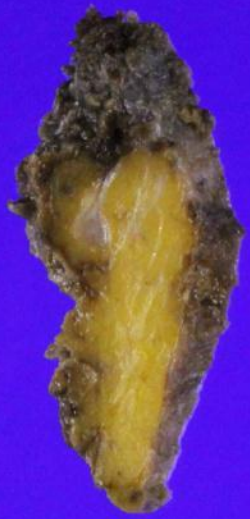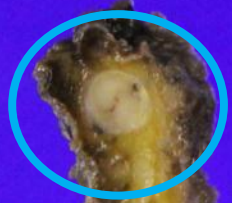肉眼像



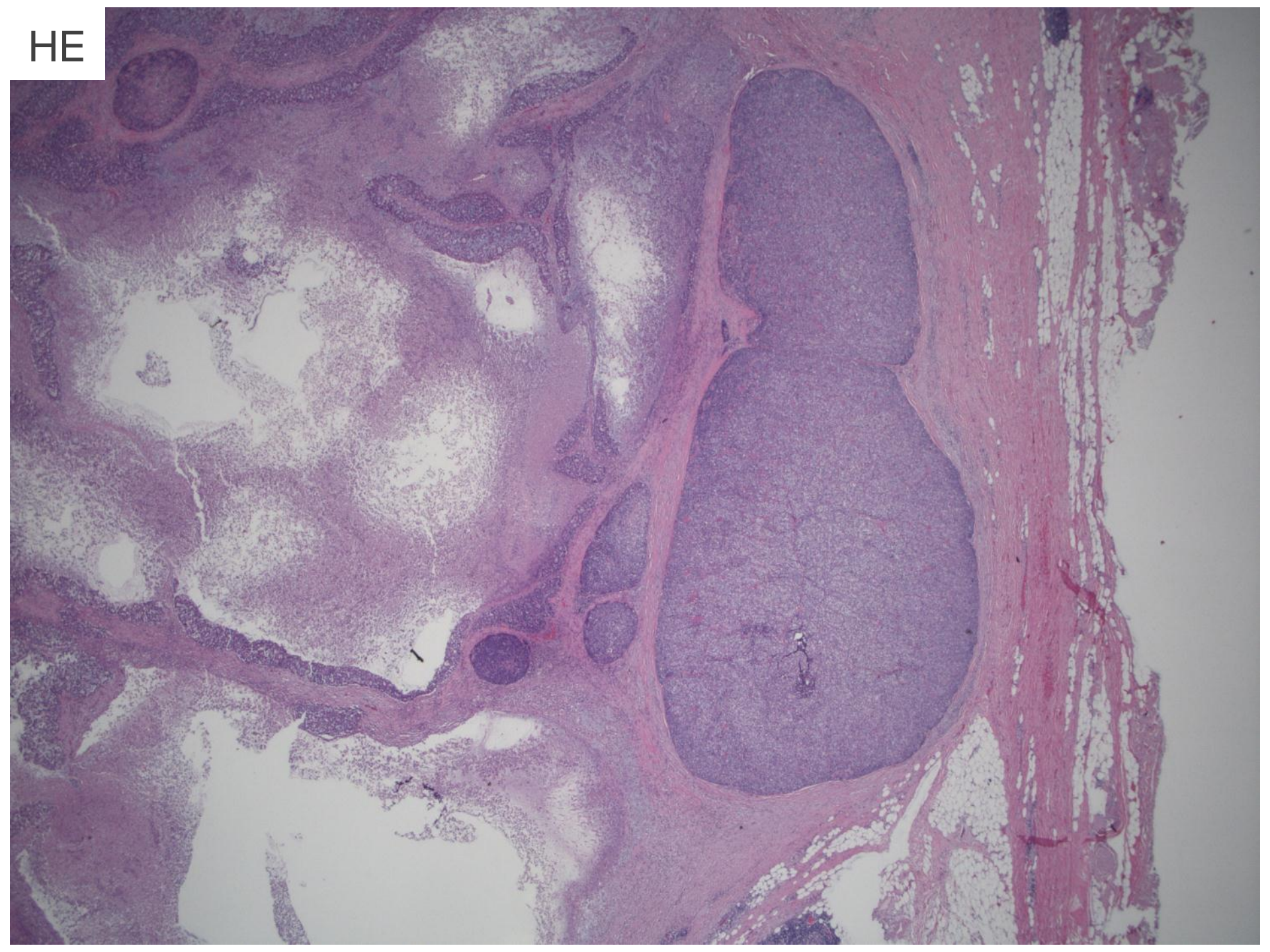
肉眼像



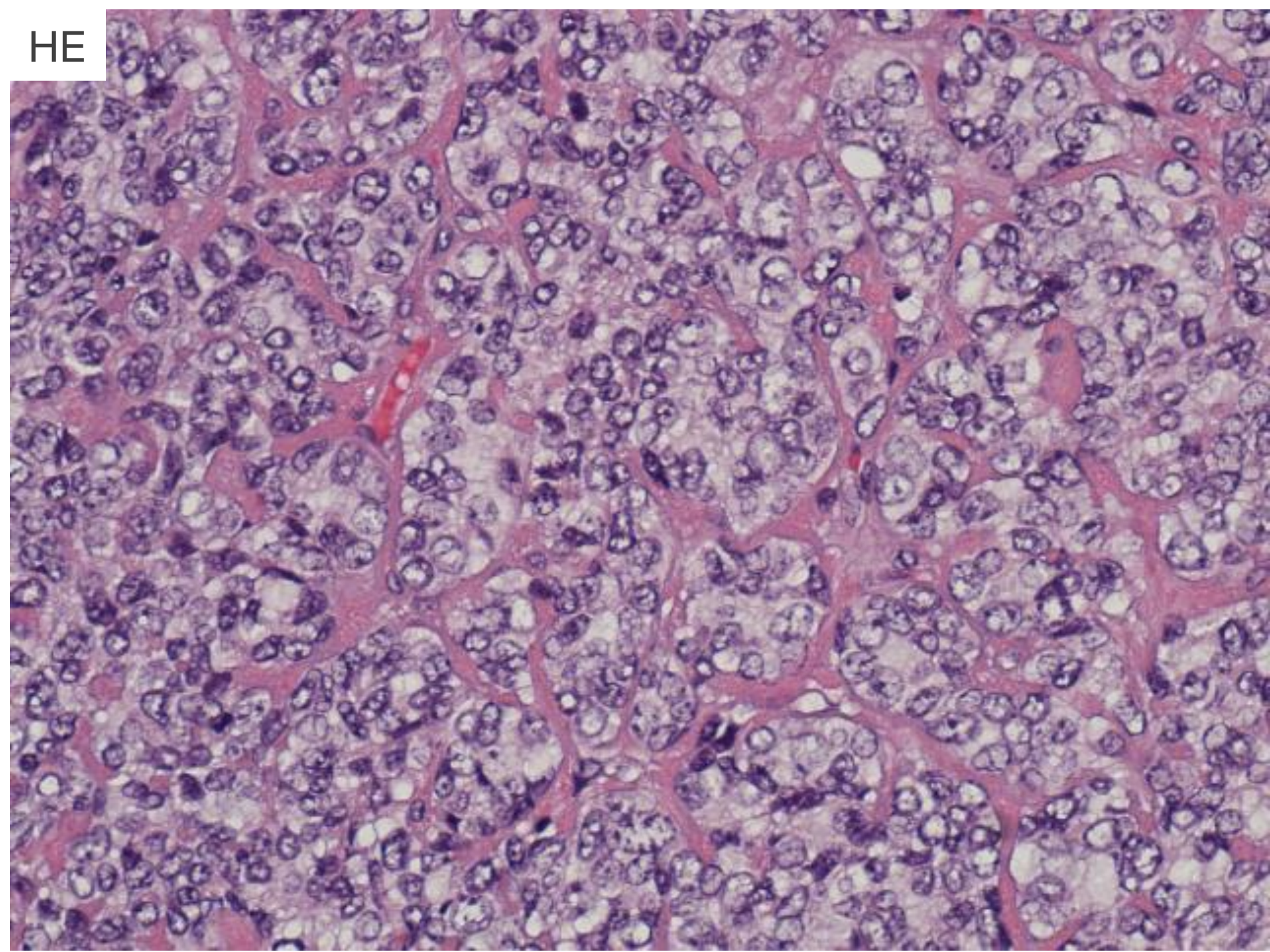
肉眼像



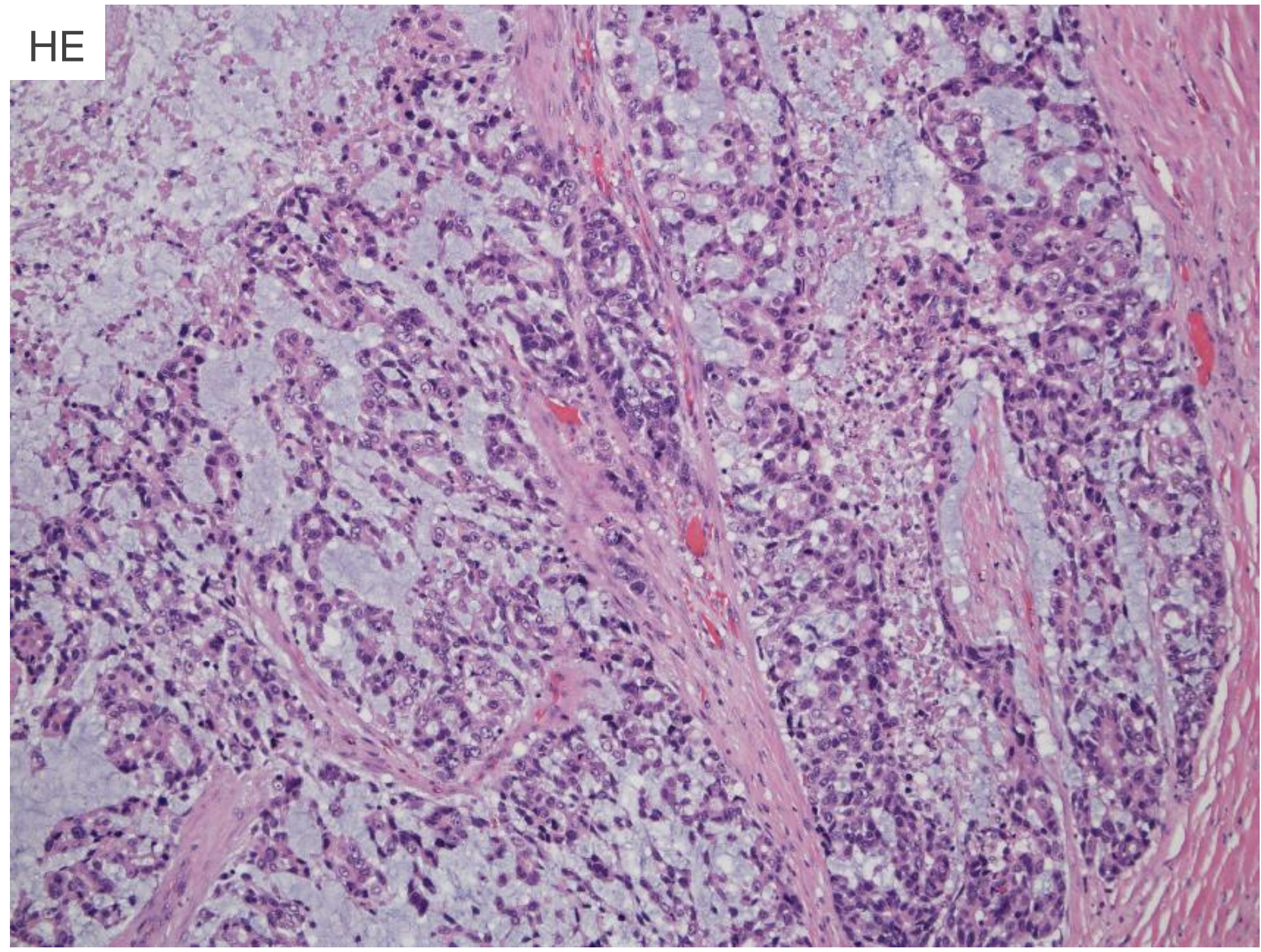
HE



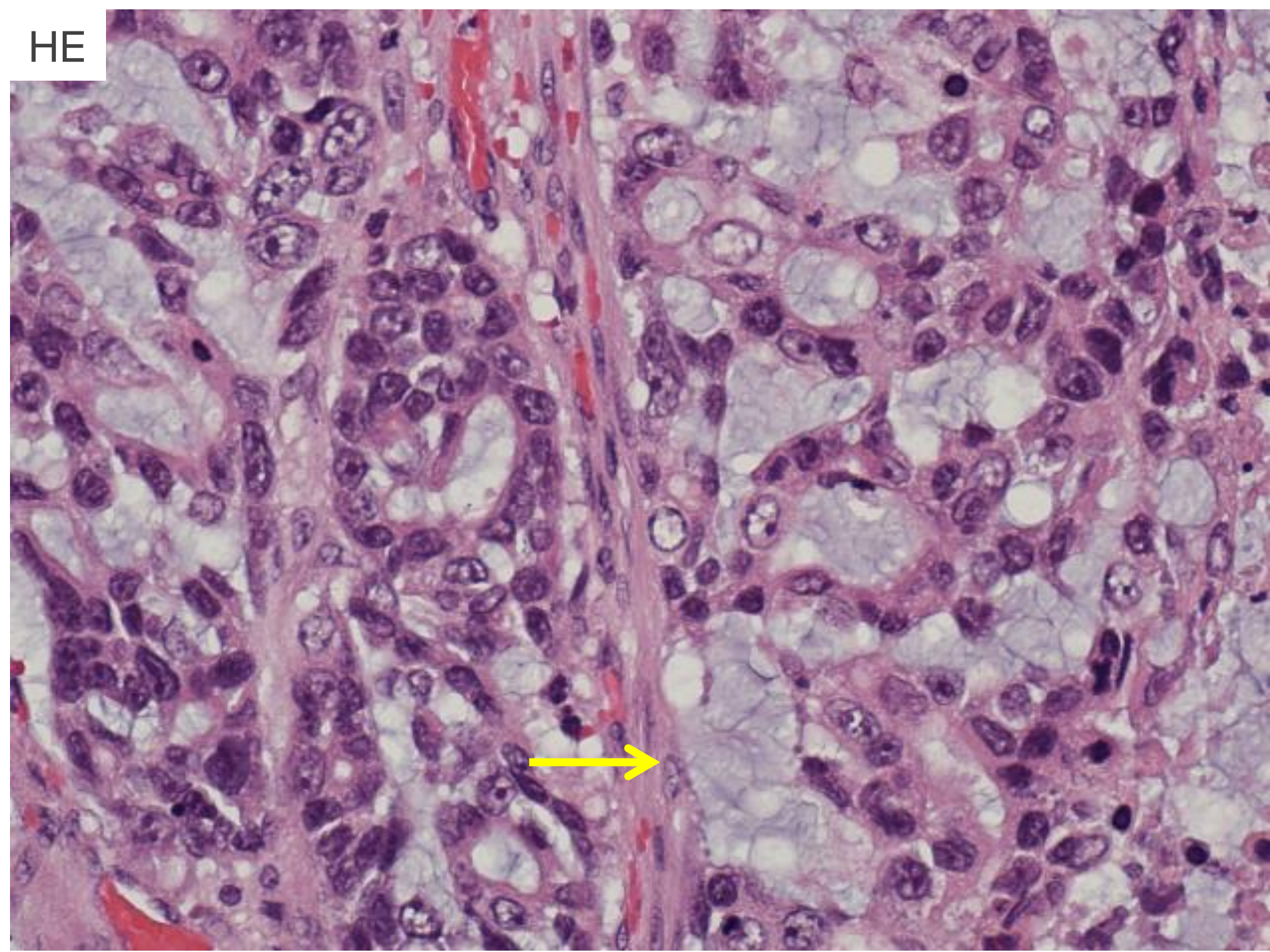
HE



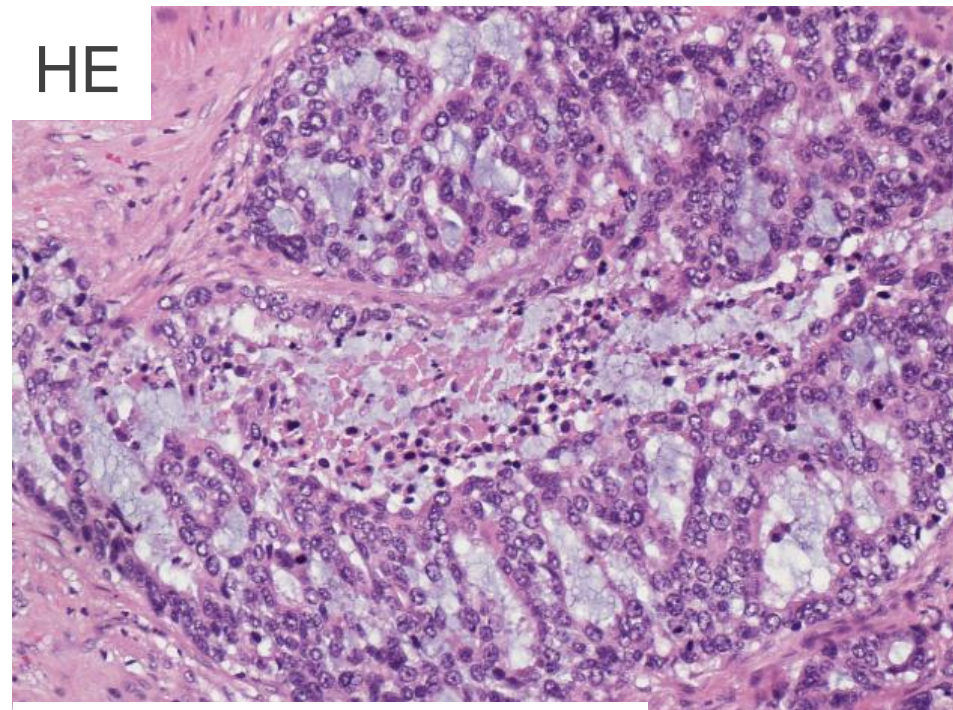
HE



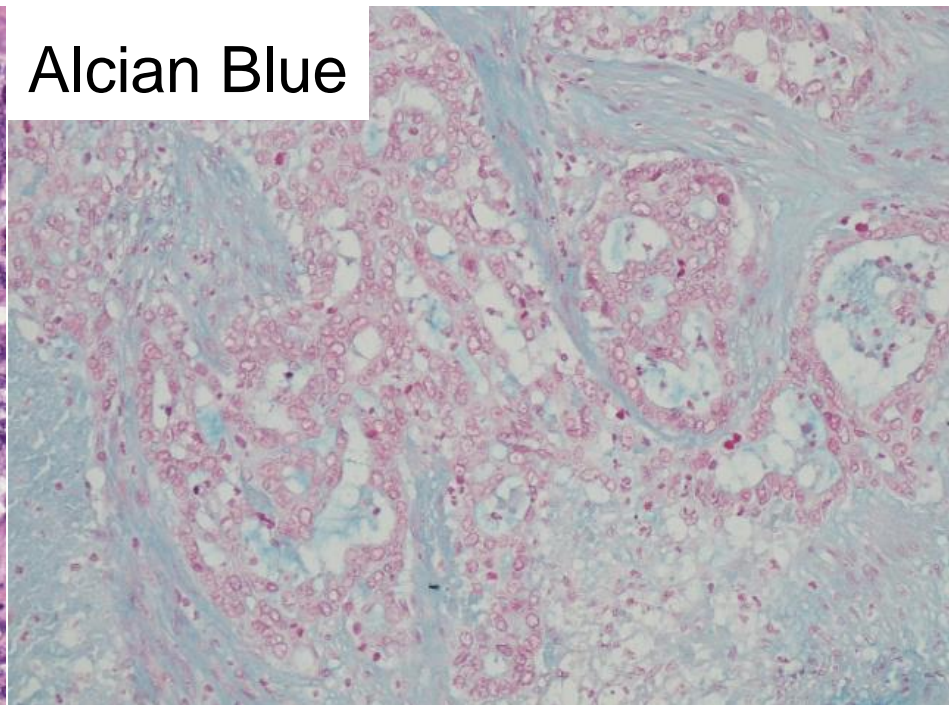
HE



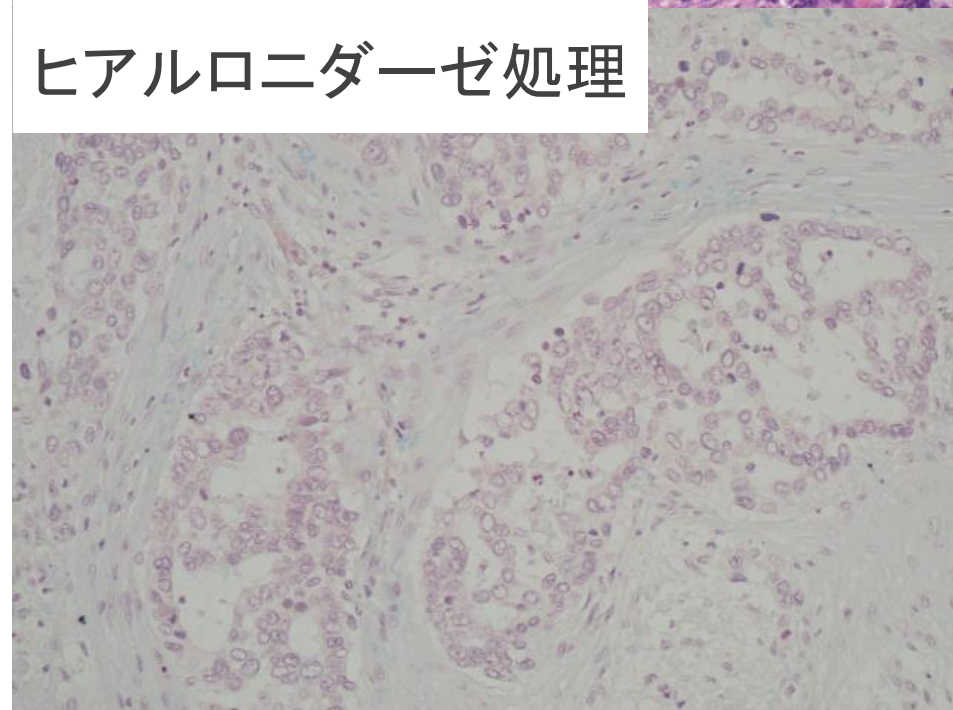
HE



Alcian Blue



ヒアルロニダーゼ処理



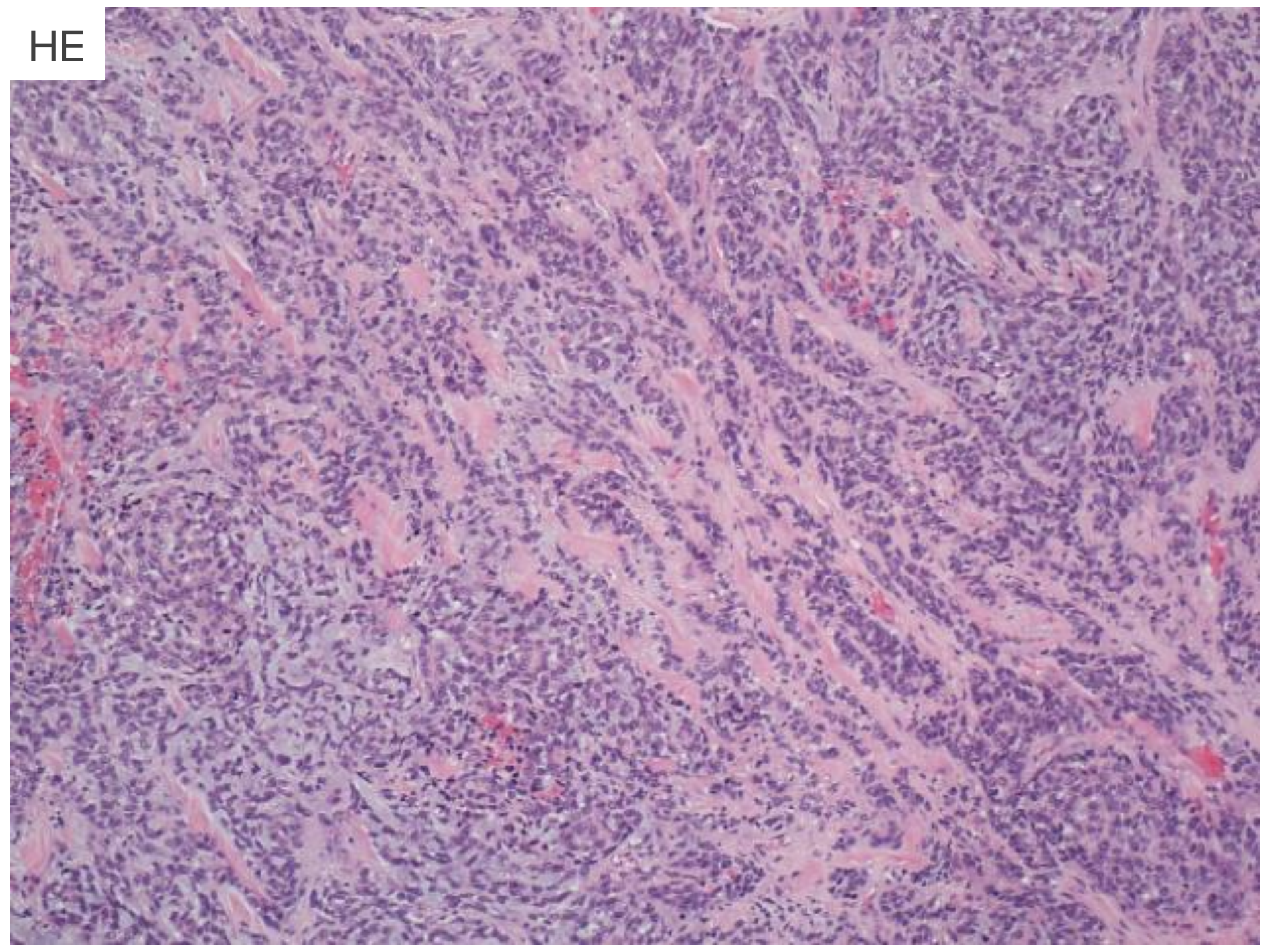
粘液はヒアルロニダーゼ

処理で消化される

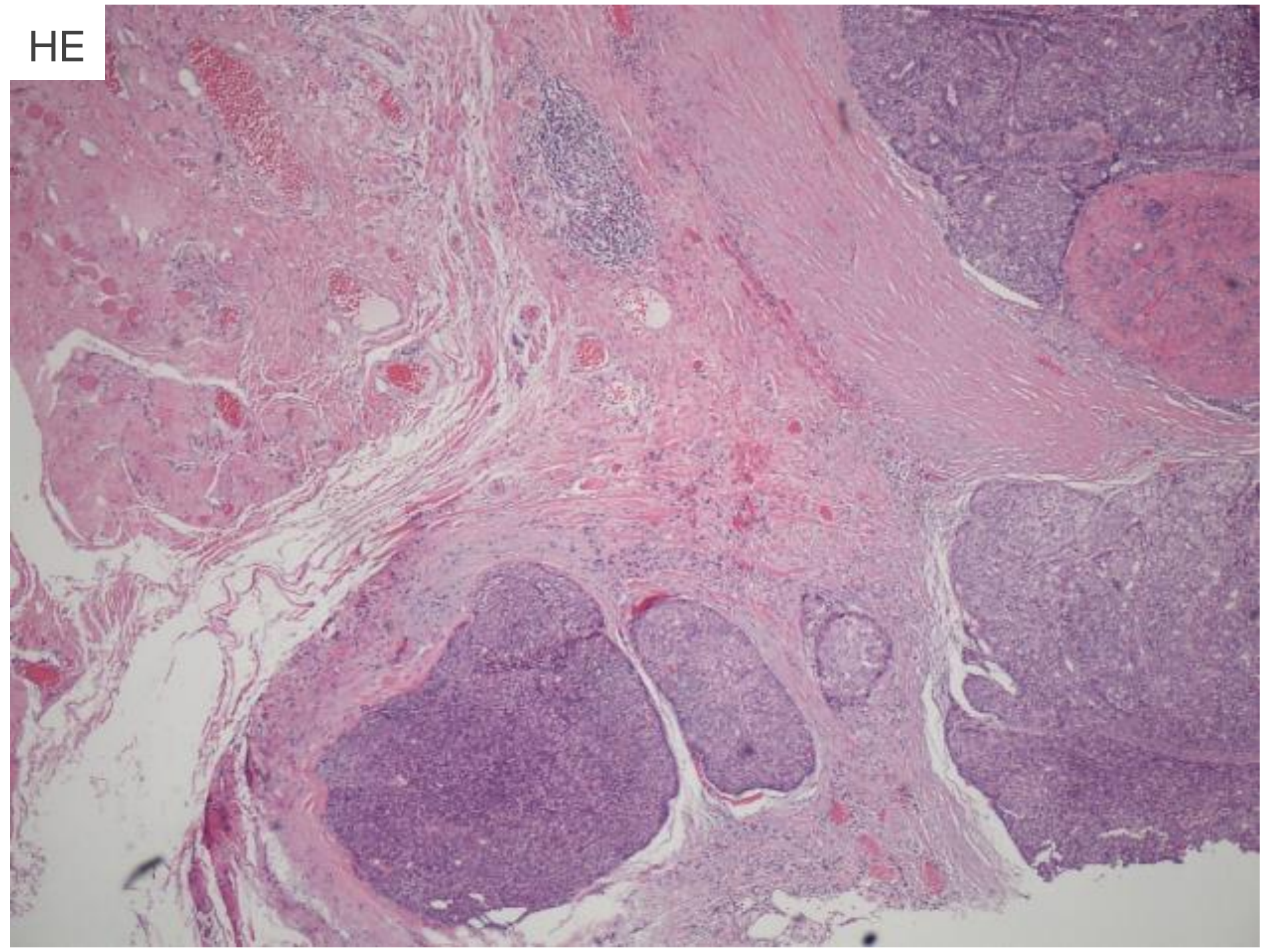


非上皮性の粘液

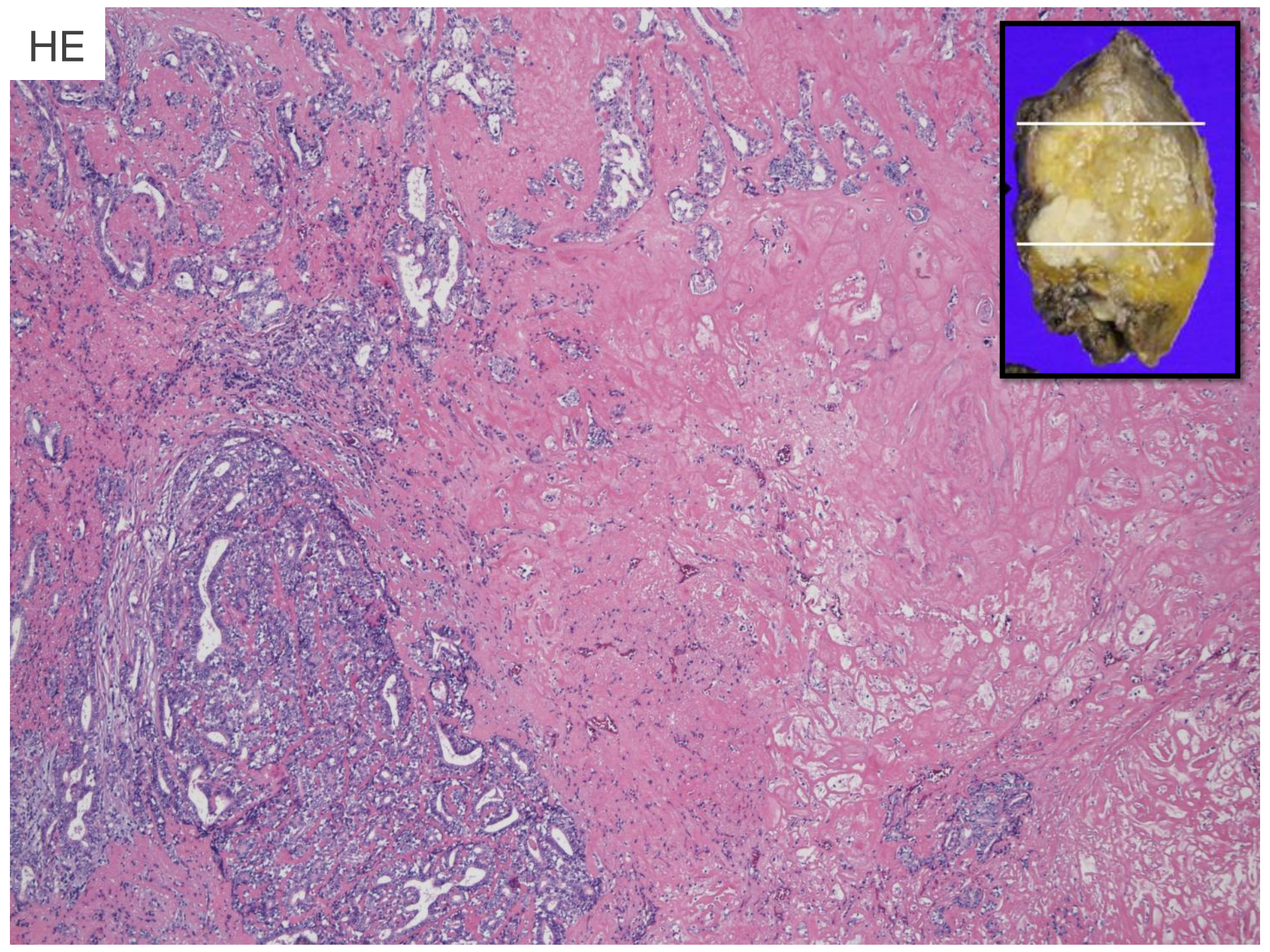
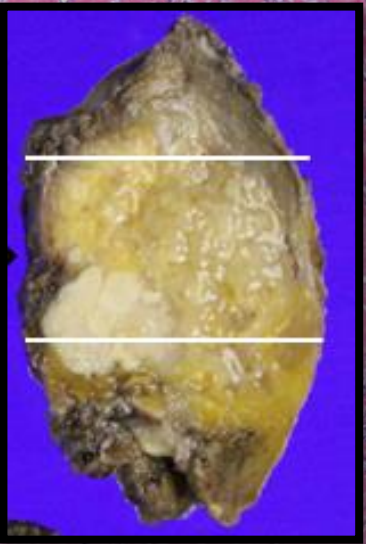
HE



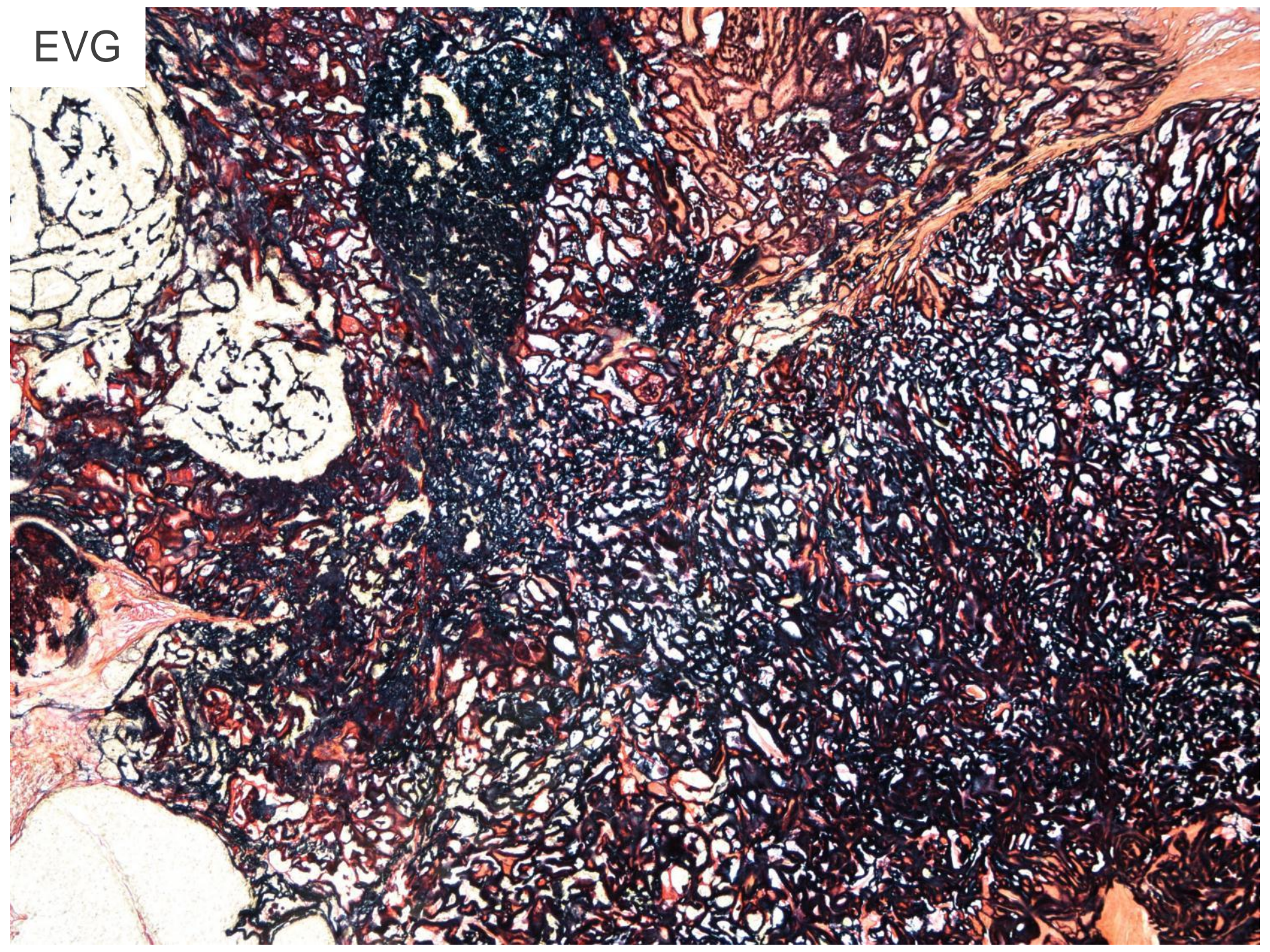
HE



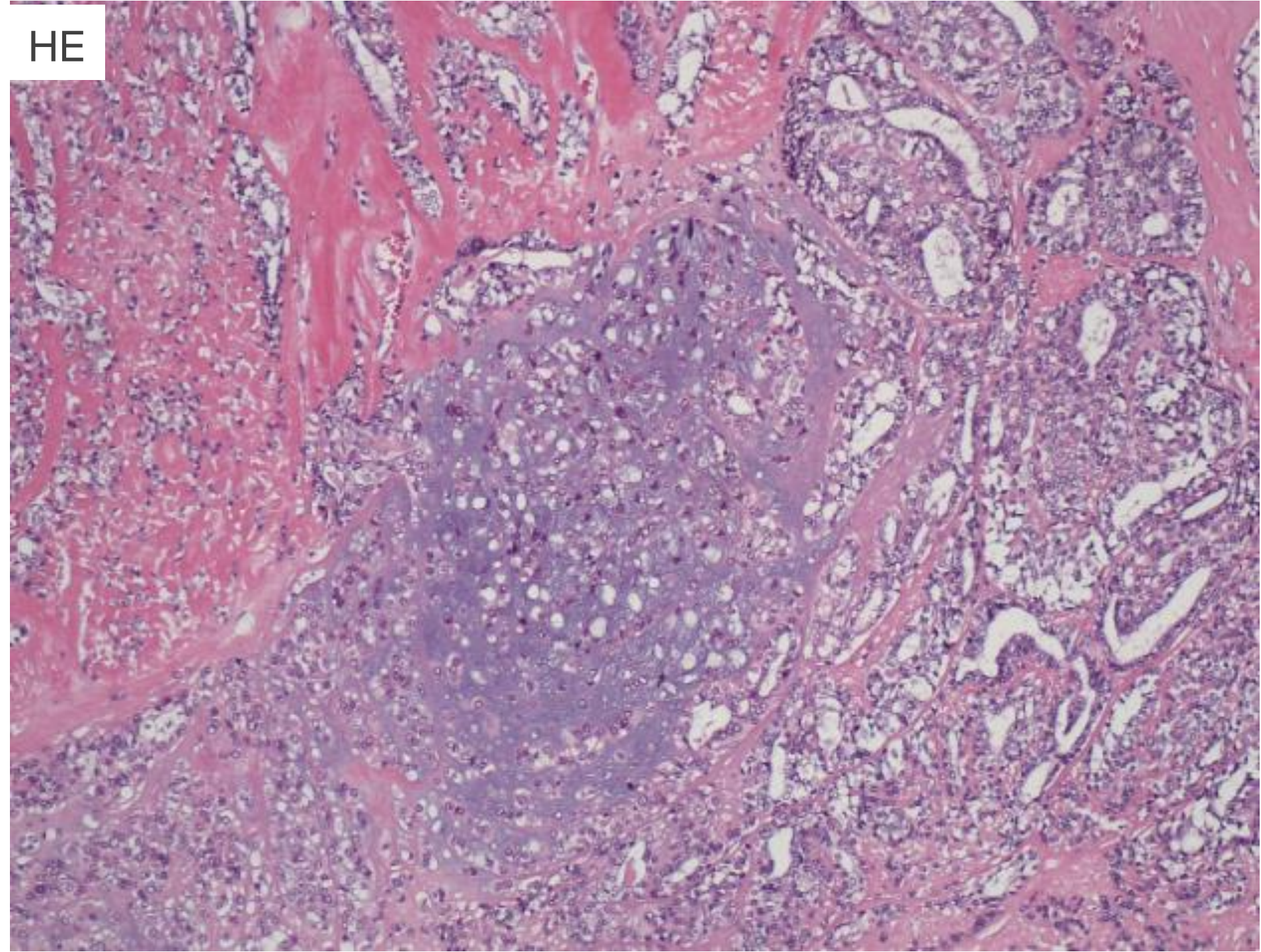
HE



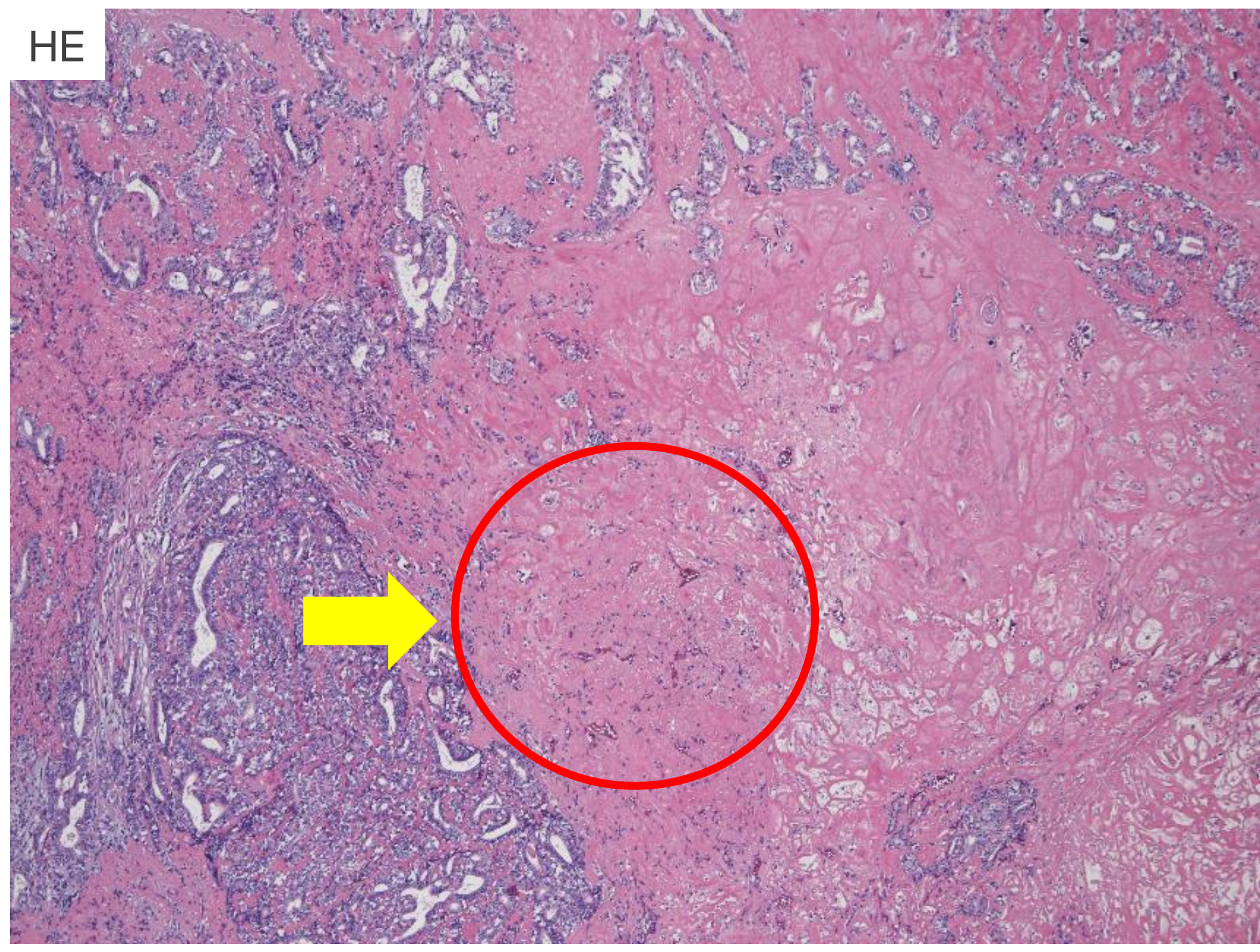
EVG



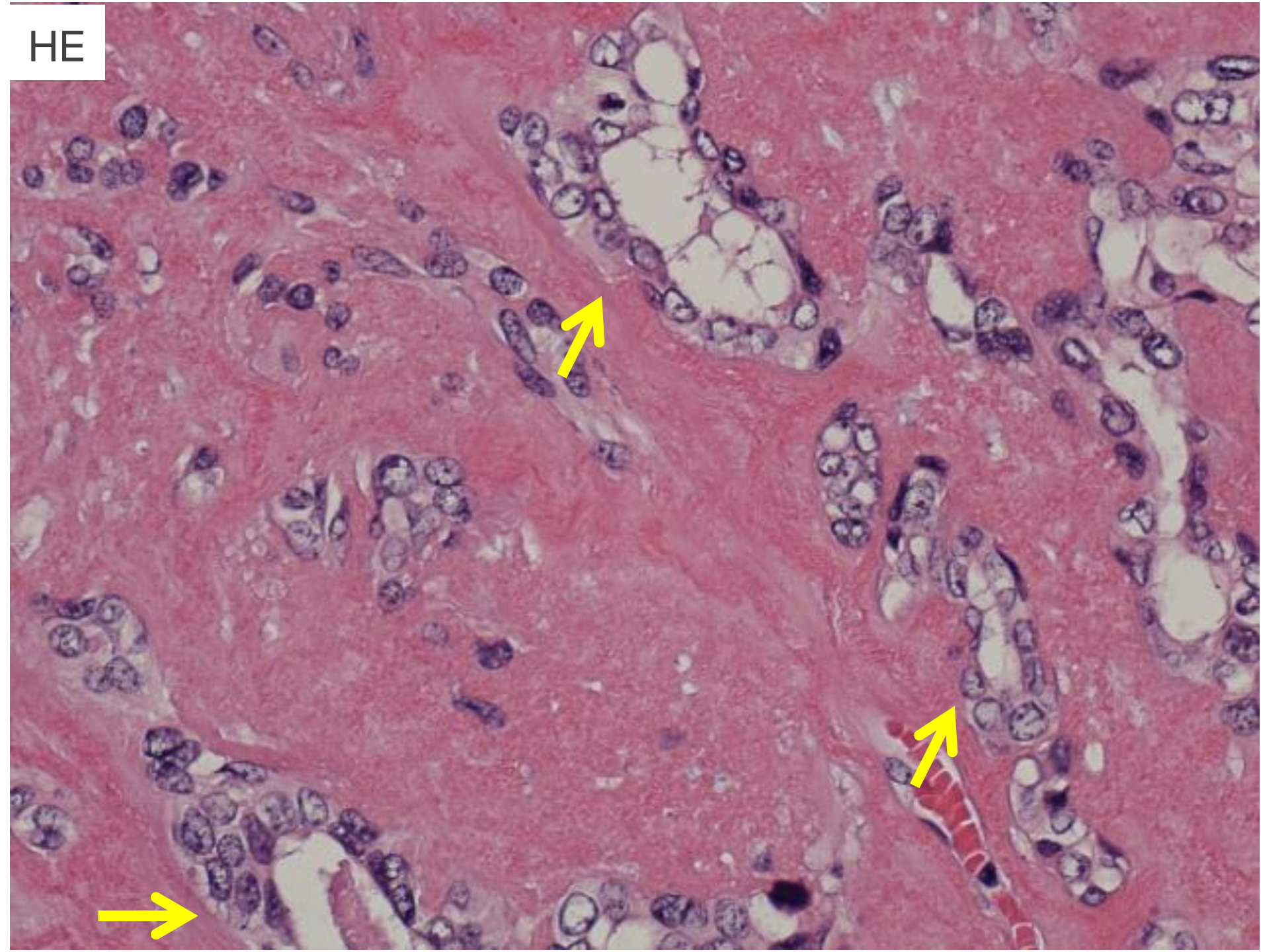
HE



HE



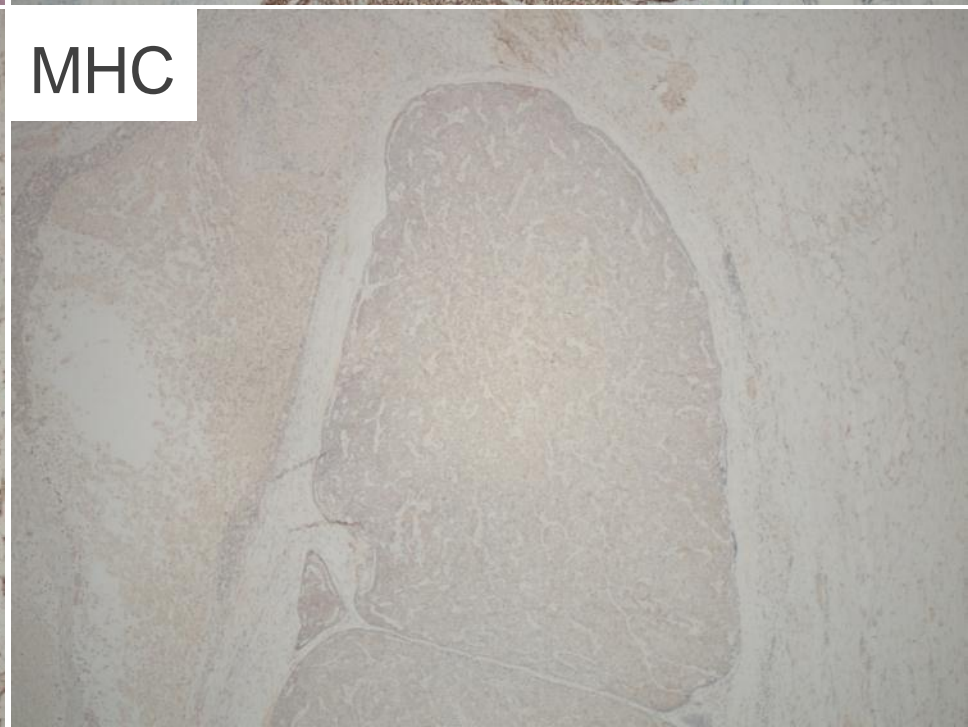
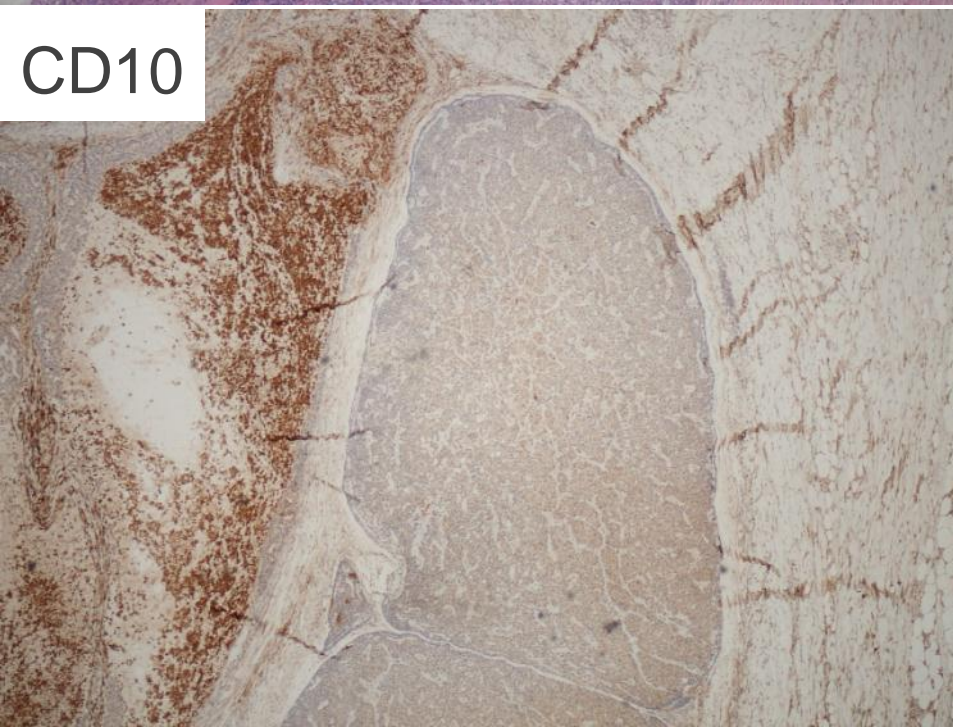
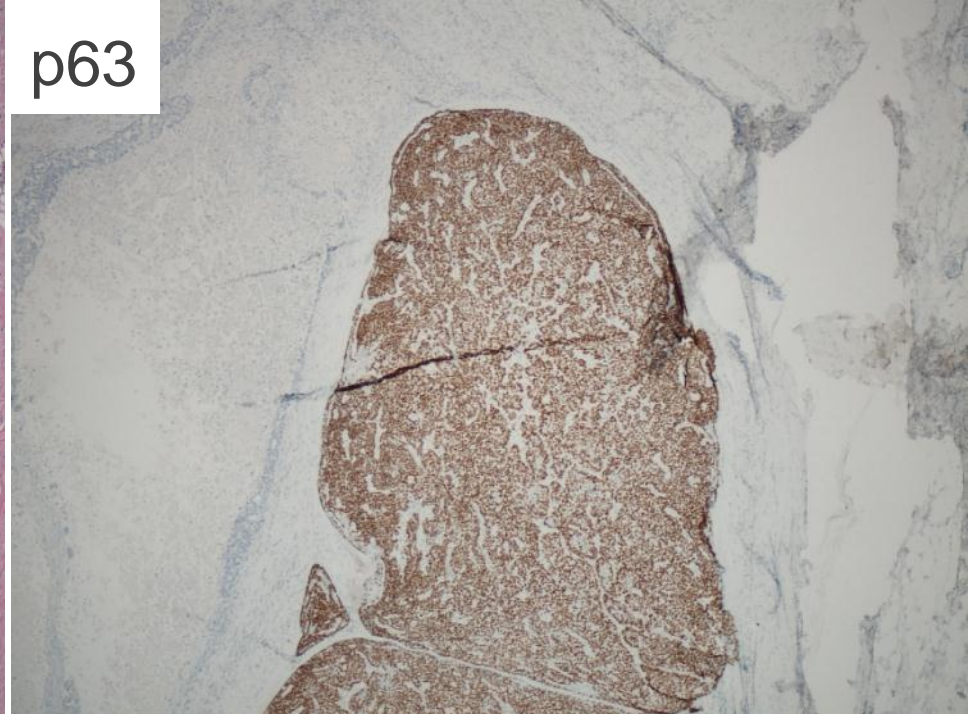
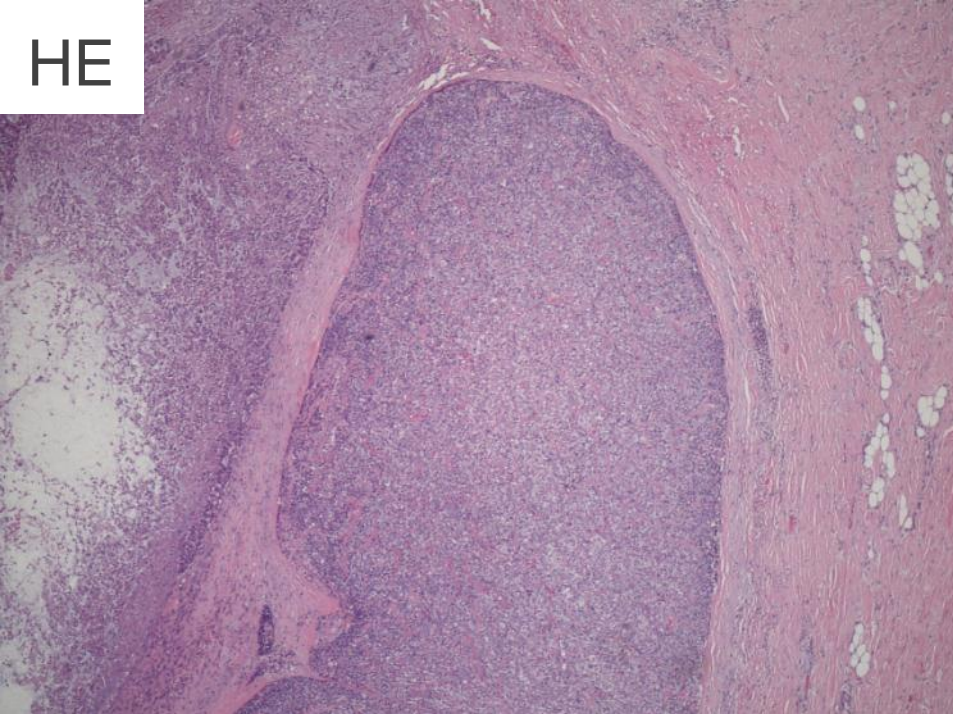
HE



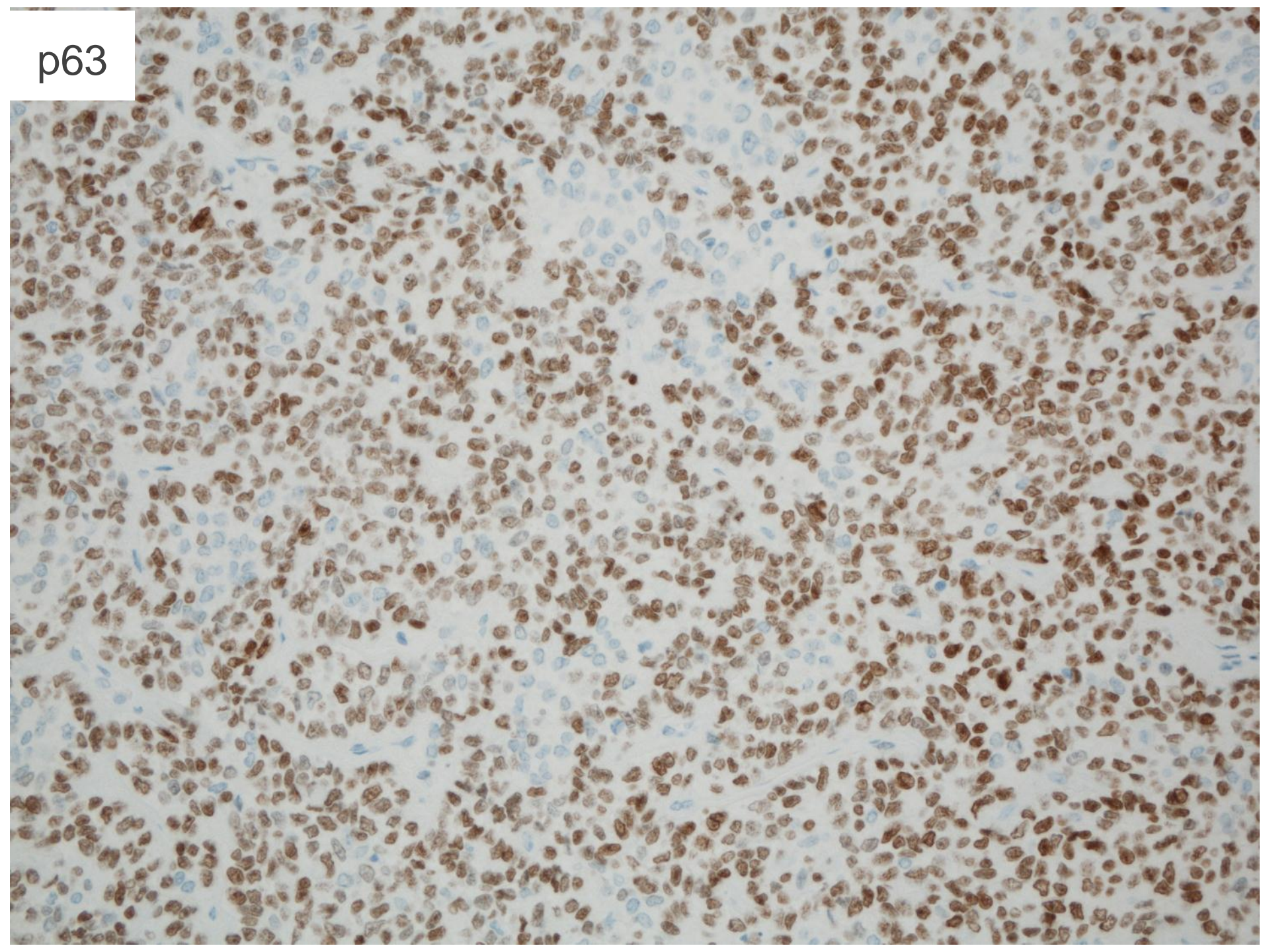
Differential diagnosis

Carcinoma ex pleomorphic adenoma

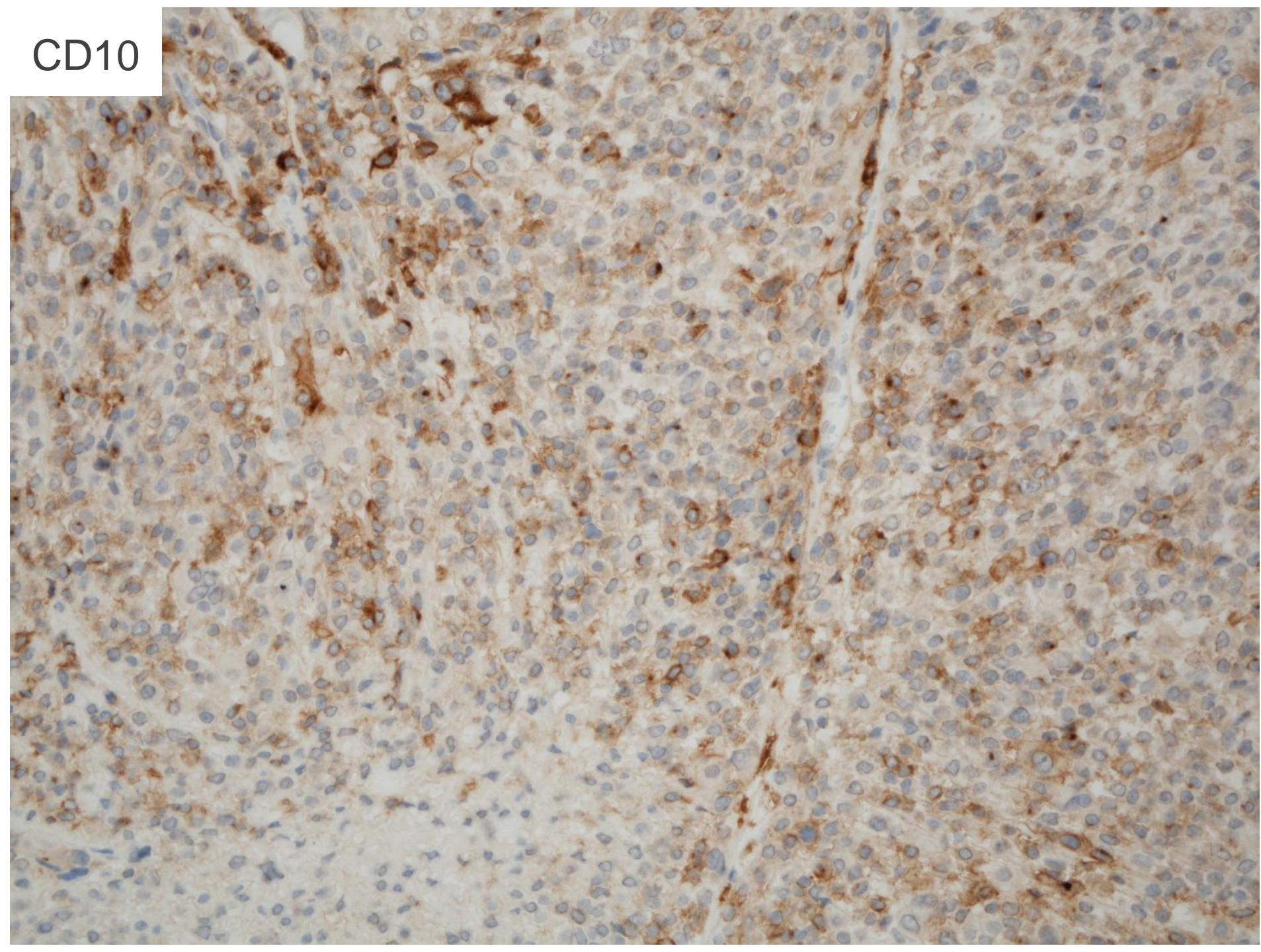
- Salivary duct carcinoma
- Myoepithelial carcinoma
- Adenocarcinoma, NOS
- Squamous cell carcinoma
- Undifferentiated carcinoma
- epithelial-myoepithelial carcinoma
- polymorphous low-grade adenocarcinoma
- mucoepidermoid carcinoma
- carcinosarcoma



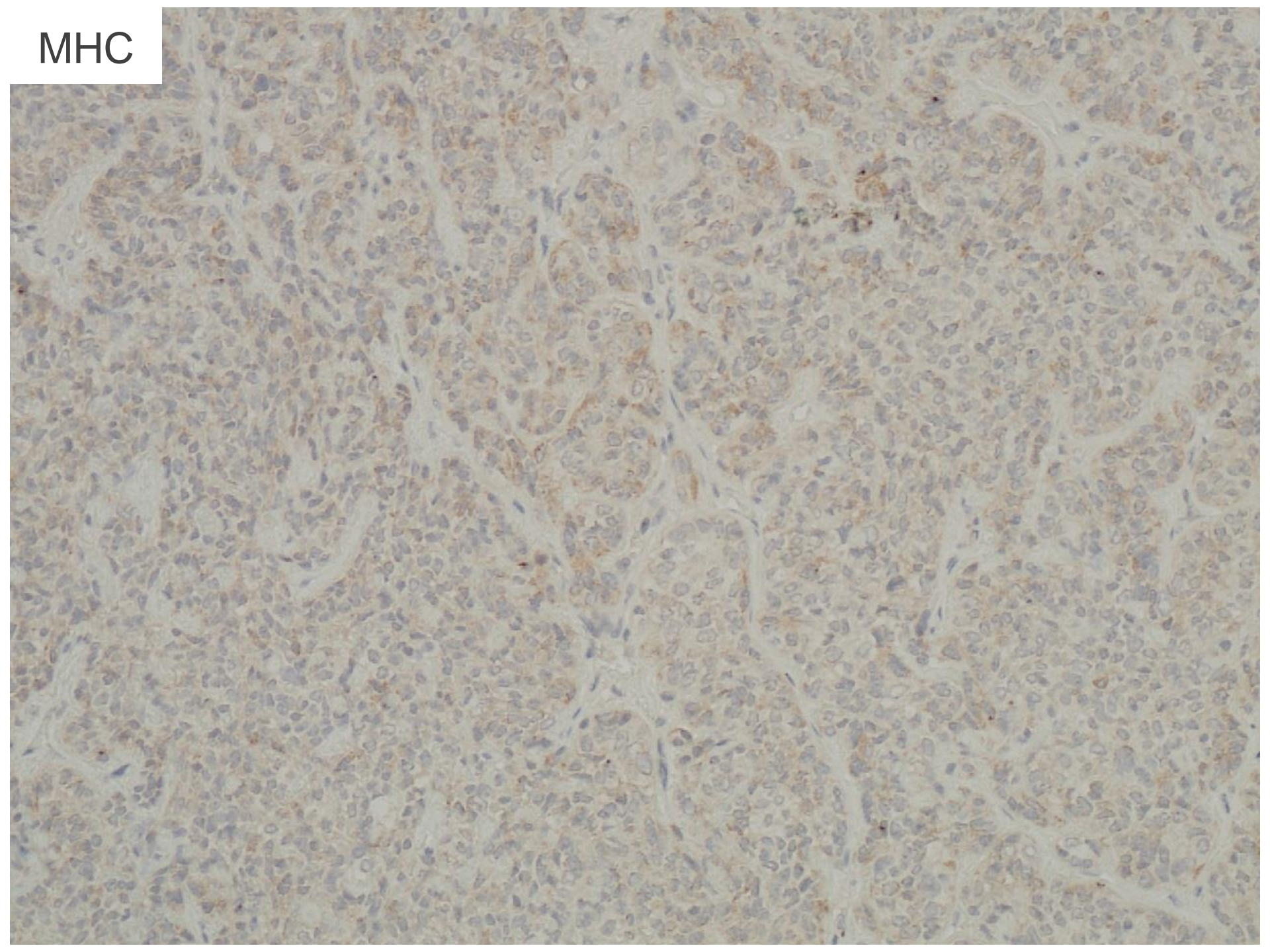
p63

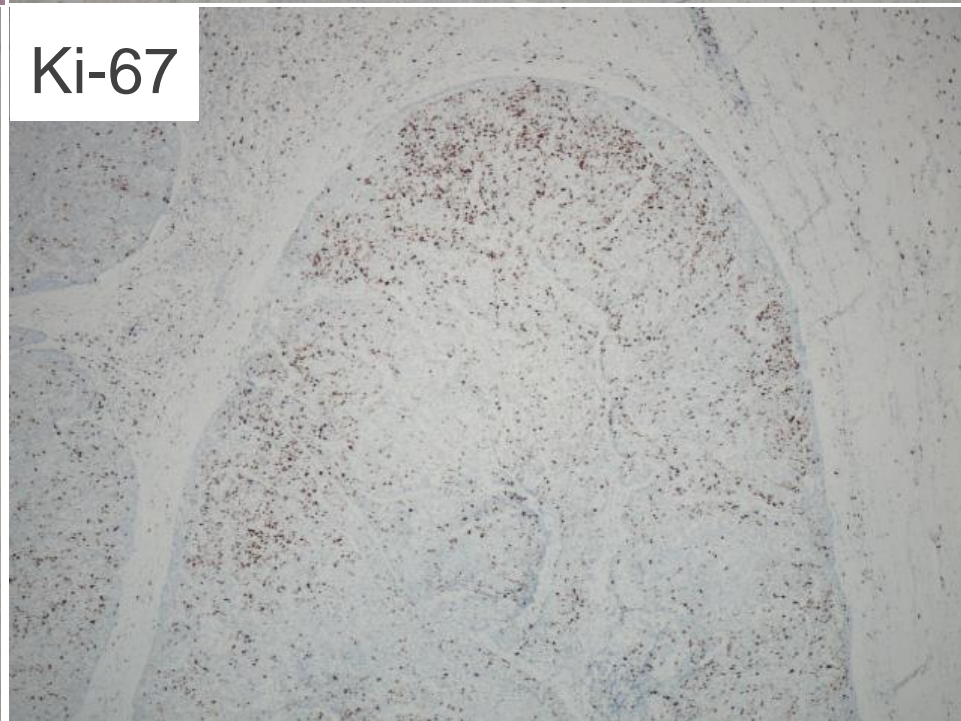
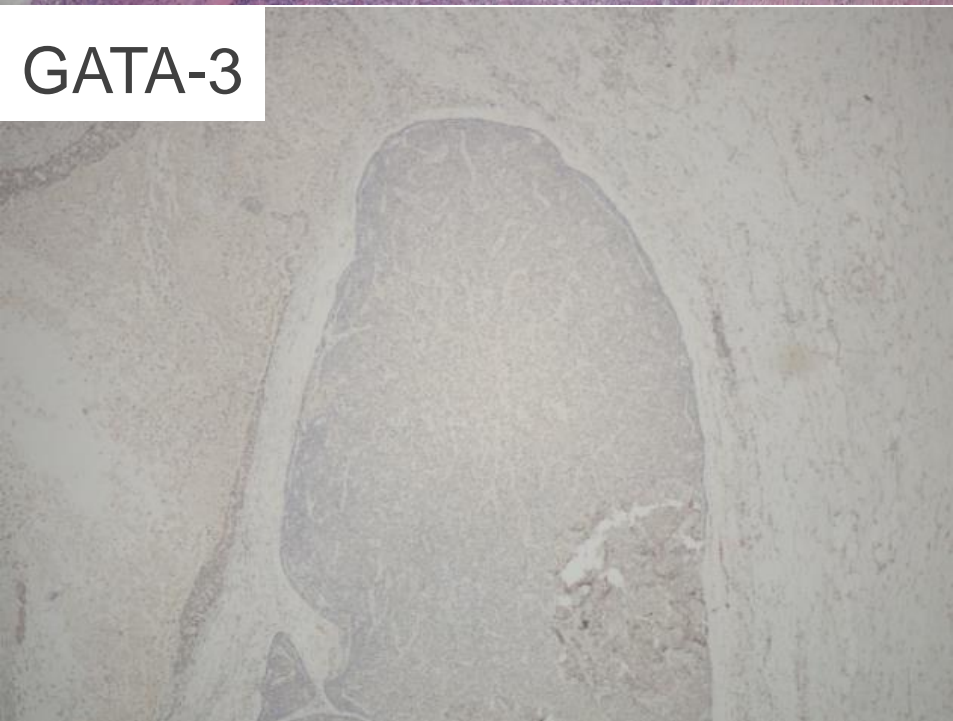
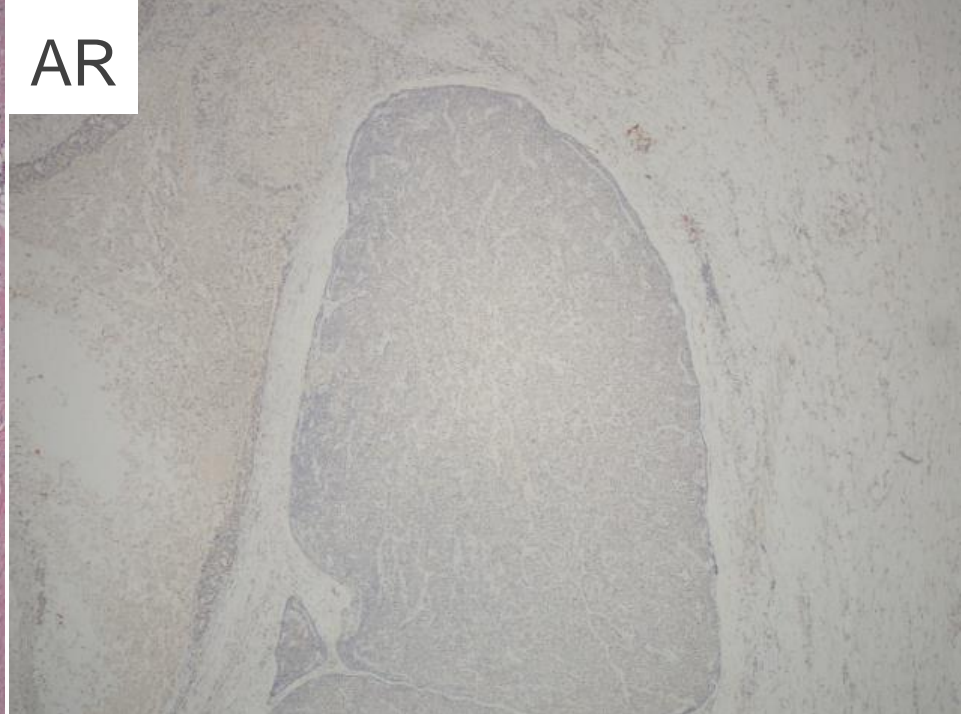
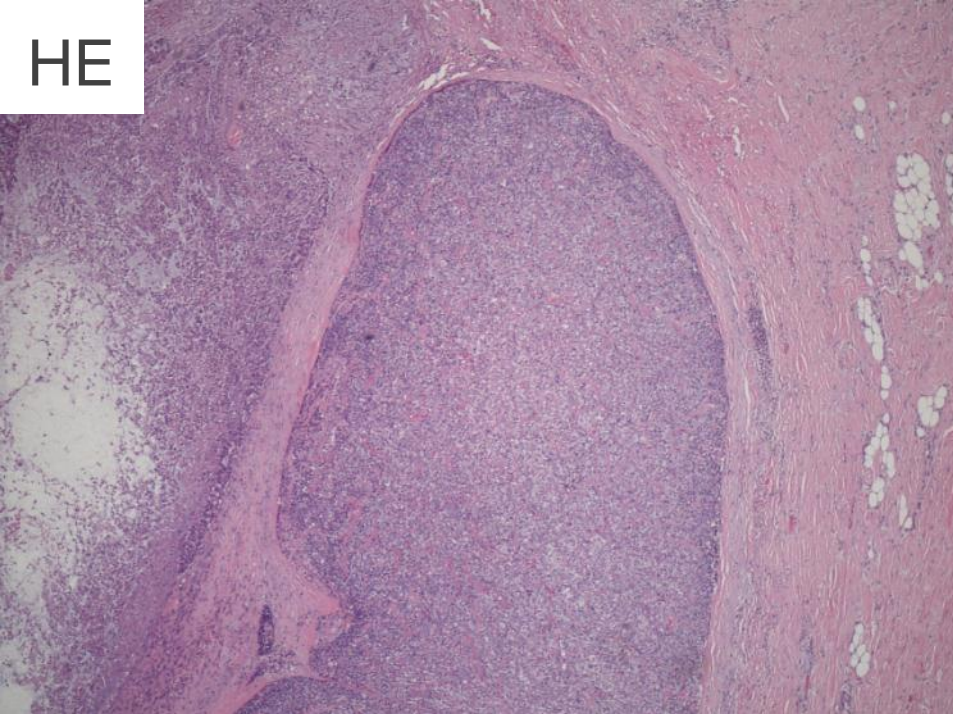


CD10



MHC





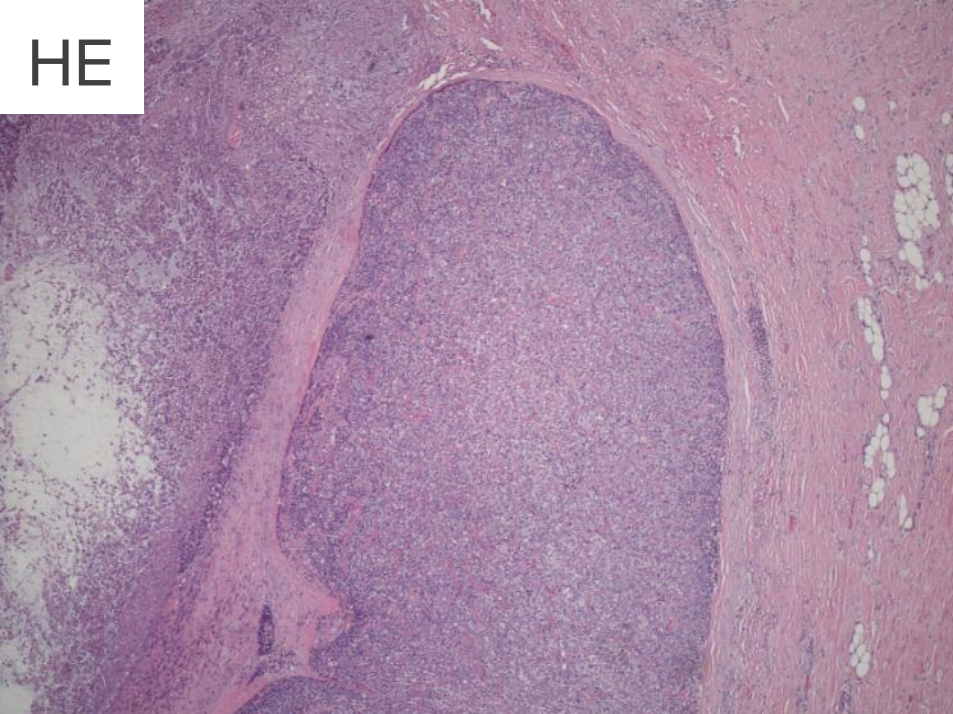
Speaker's diagnosis

Myoepithelial carcinoma ex pleomorphic adenoma

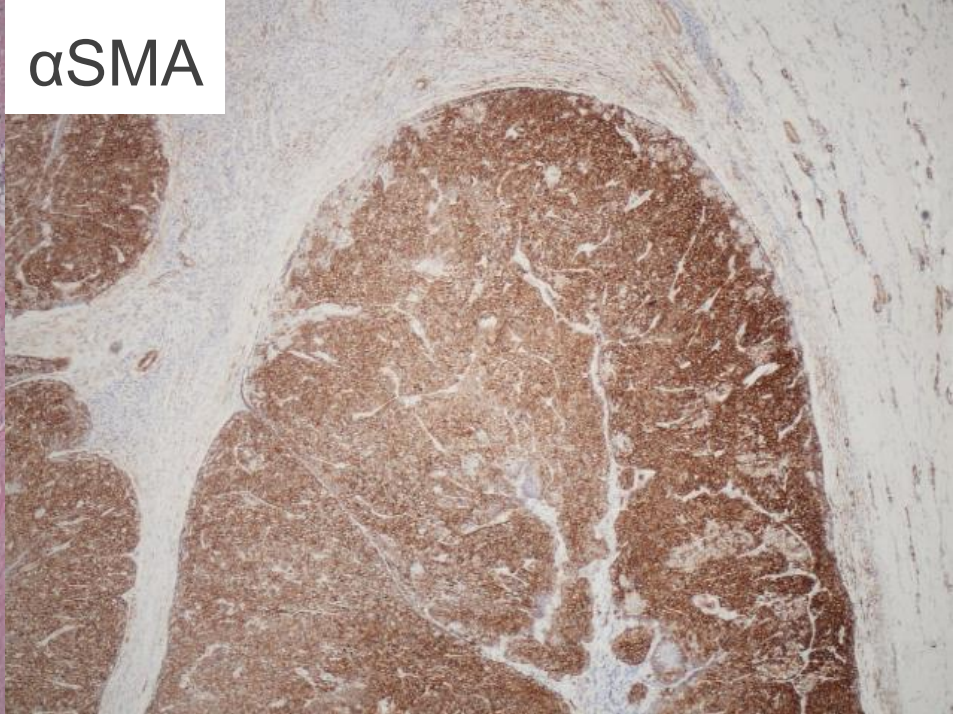
他の筋上皮マーカーも
染めてみました



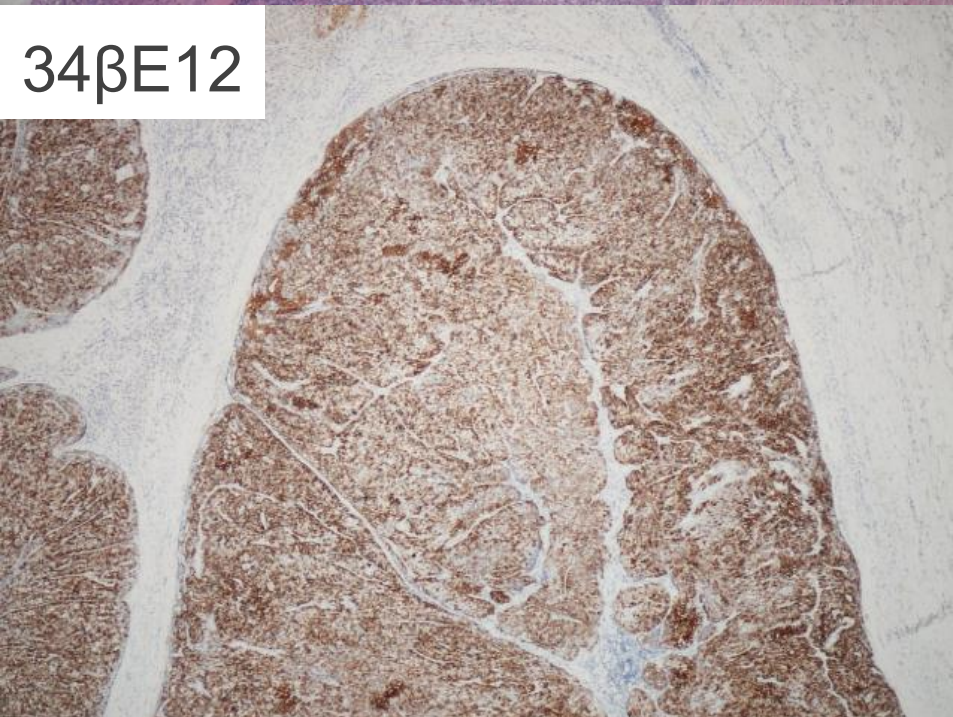
HE



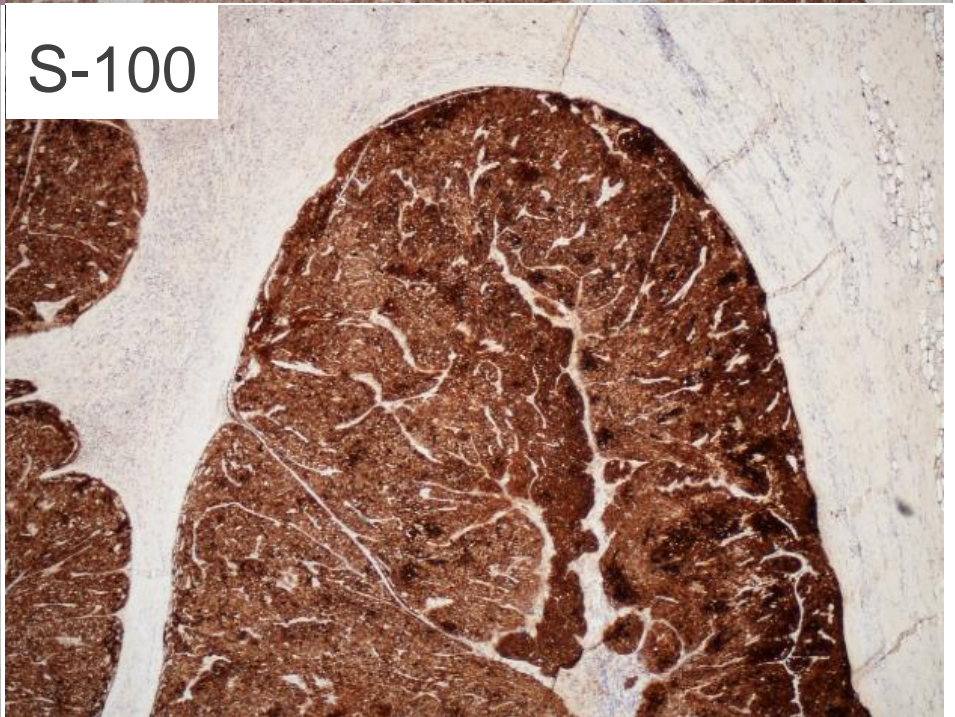
α SMA

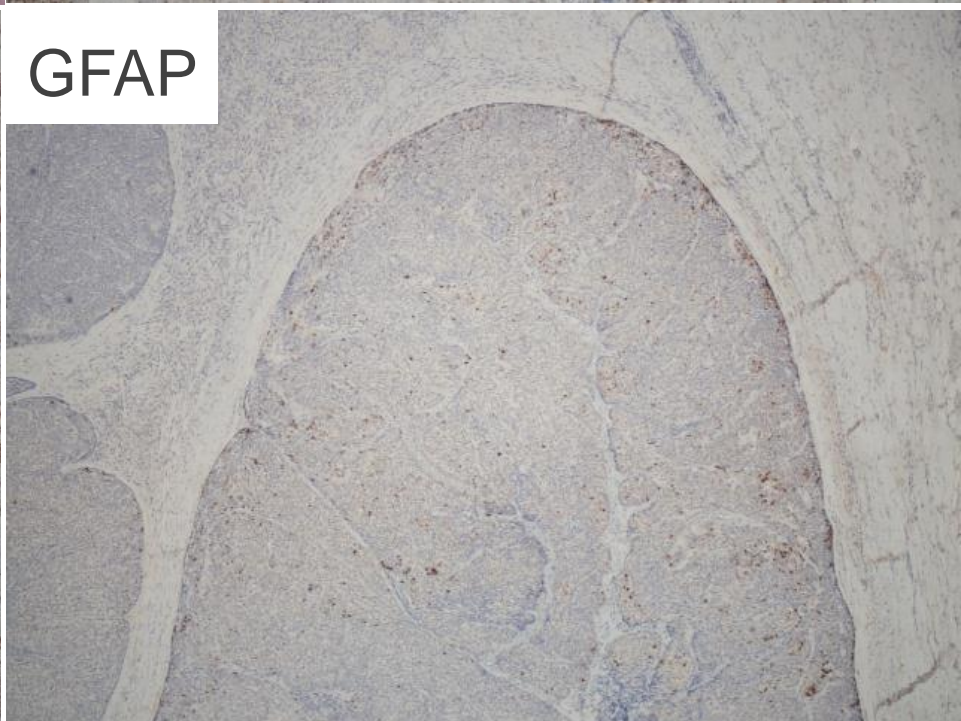
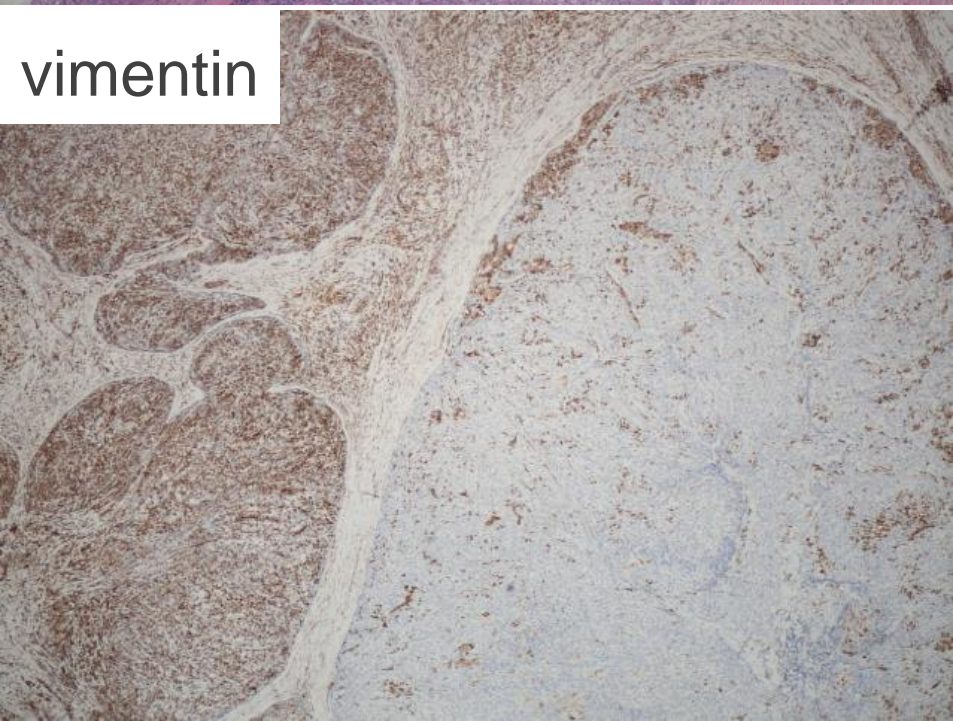
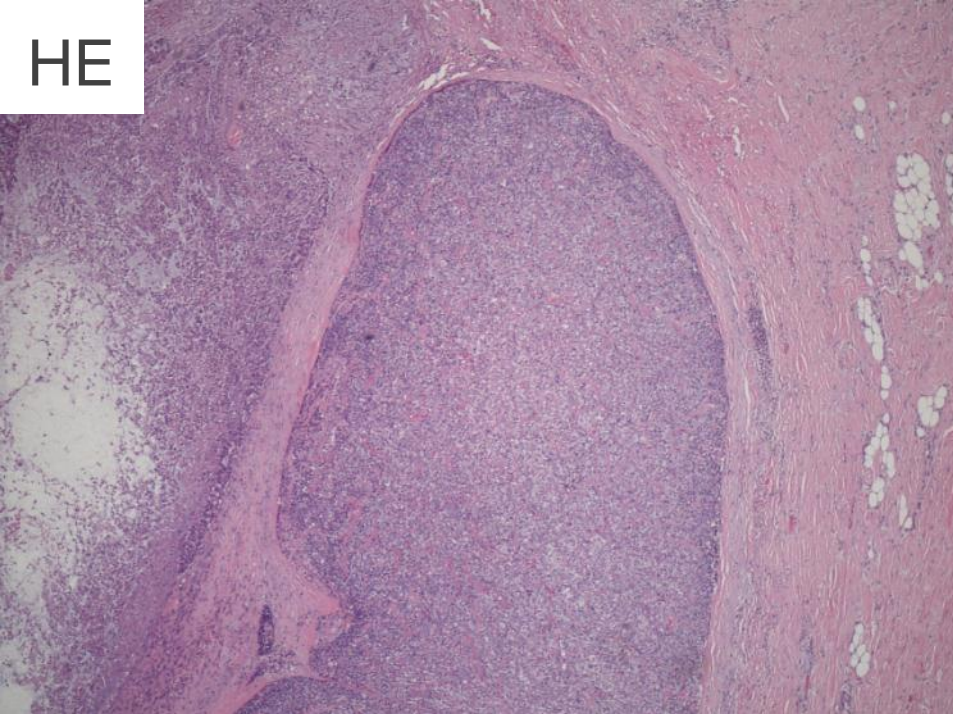


34 β E12

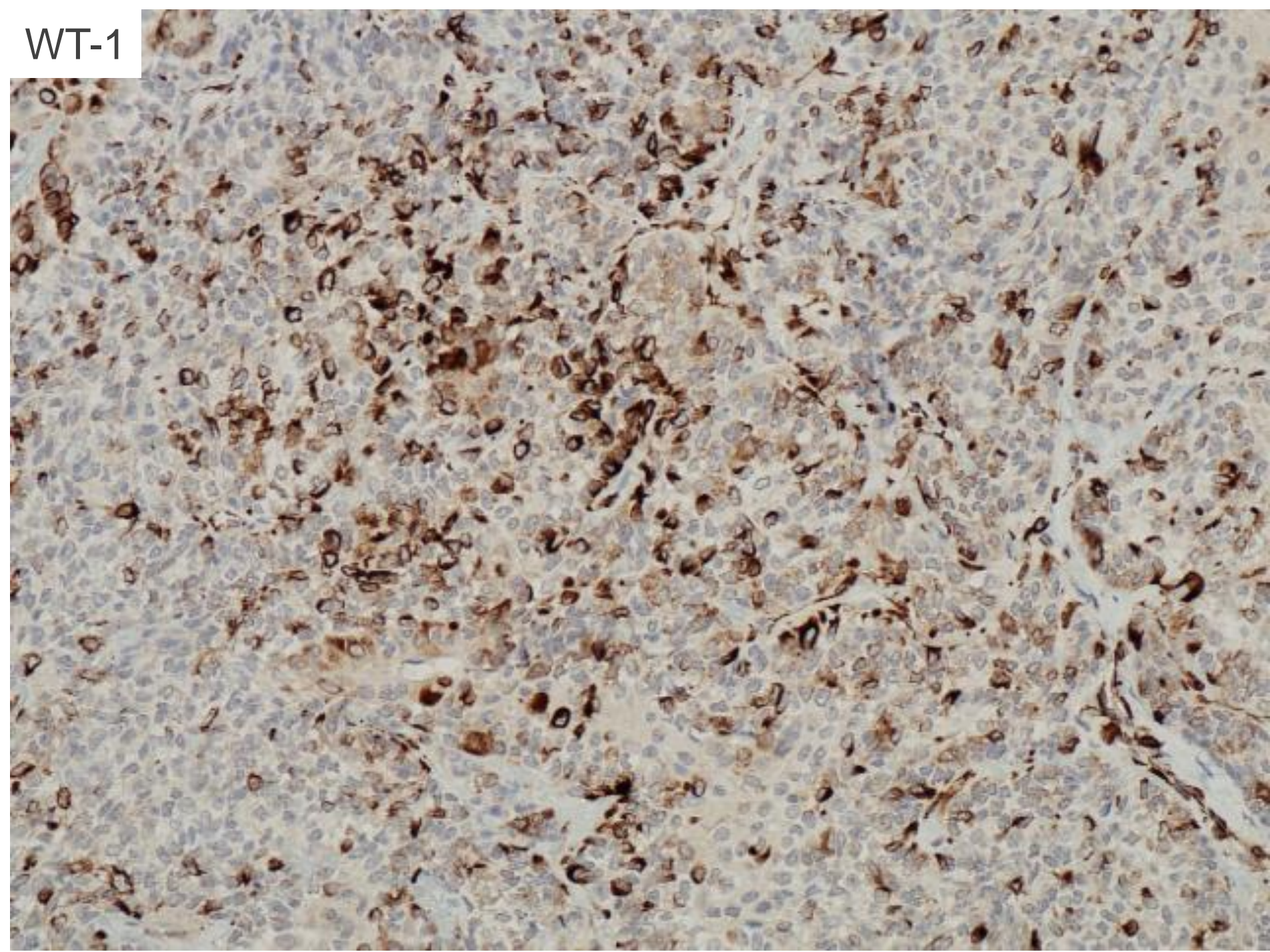


S-100

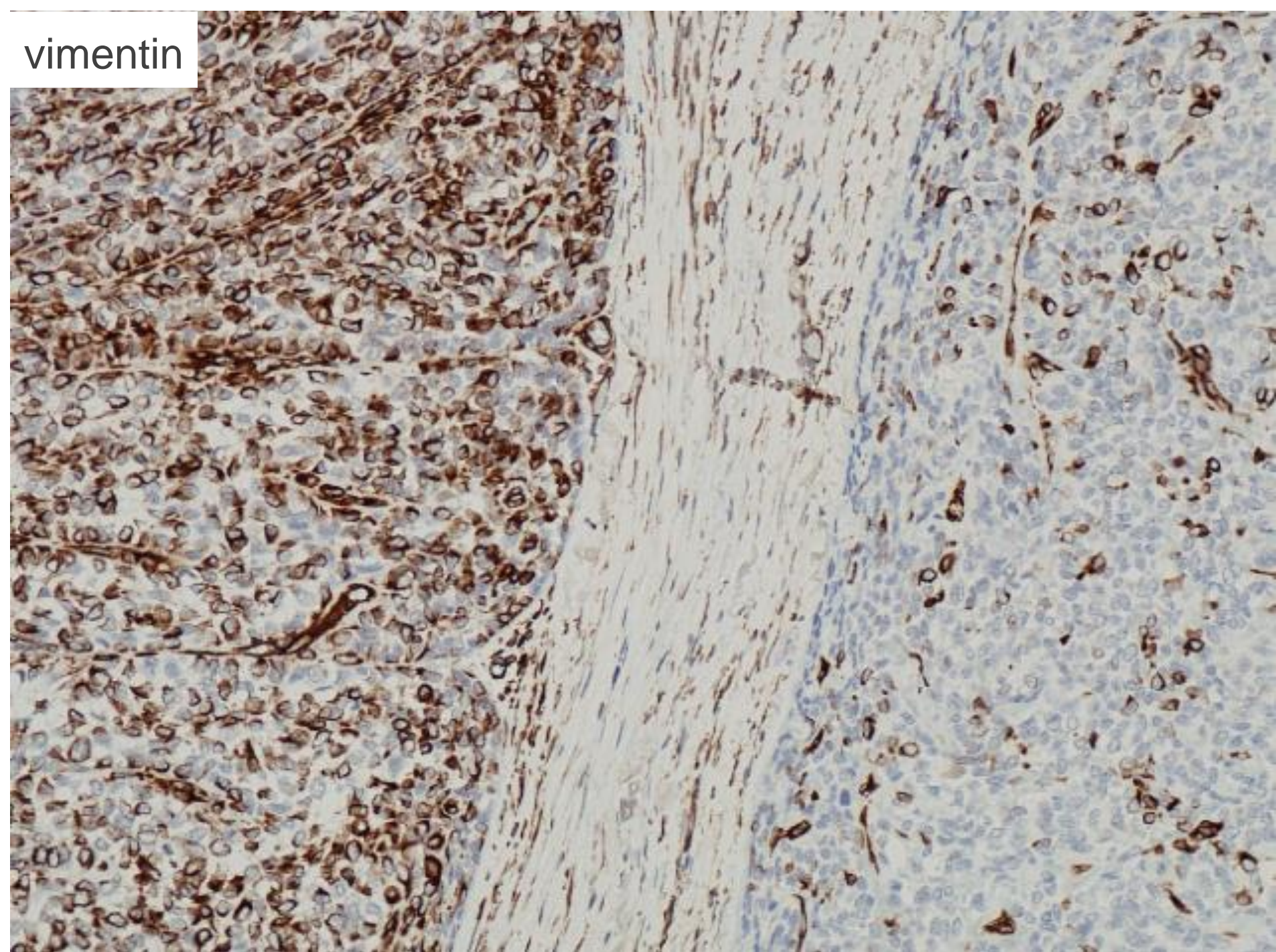




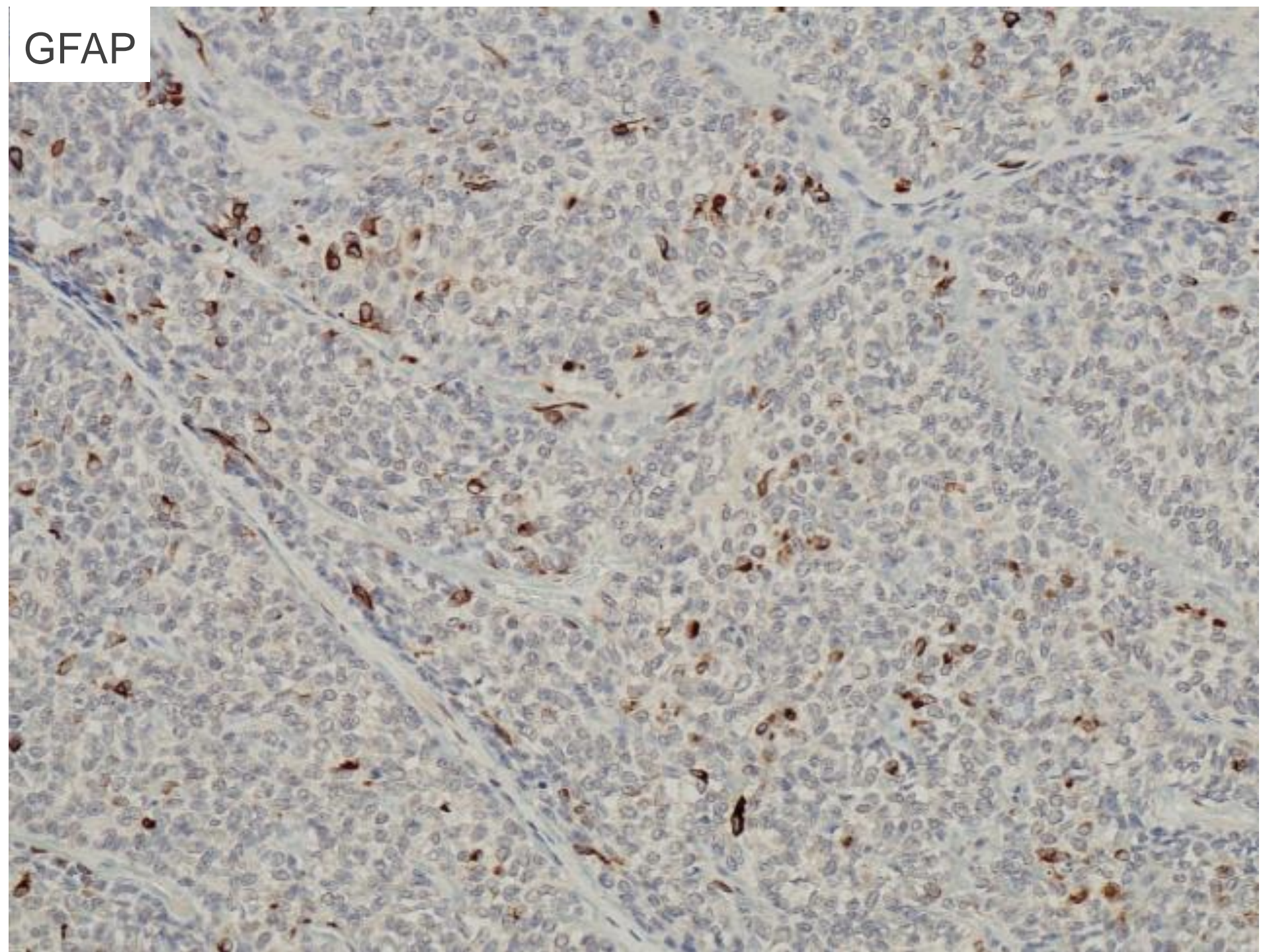
WT-1



vimentin

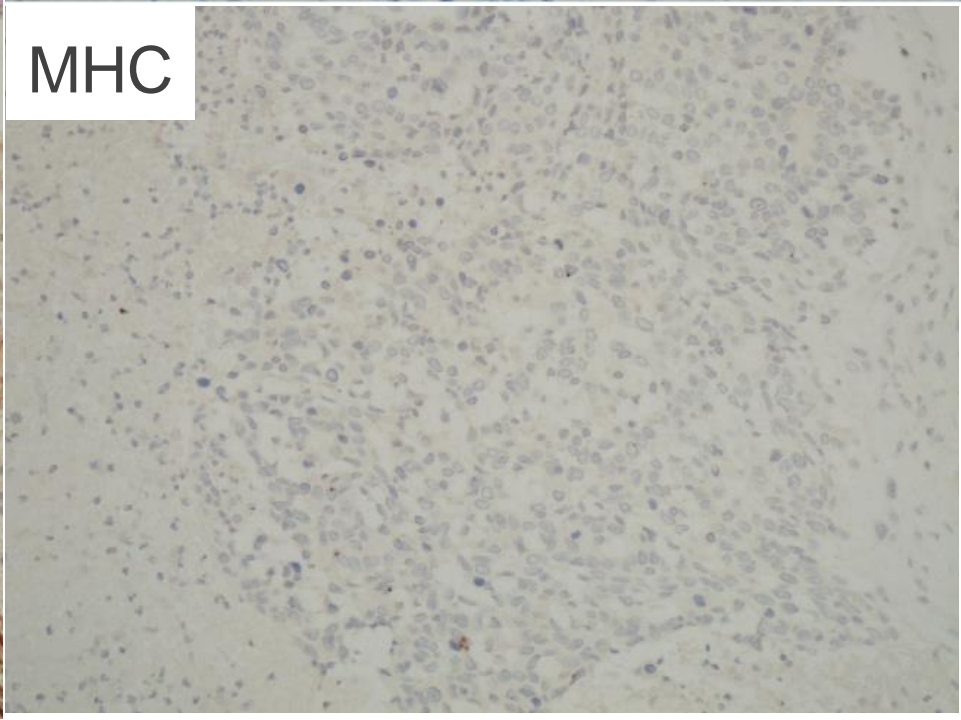
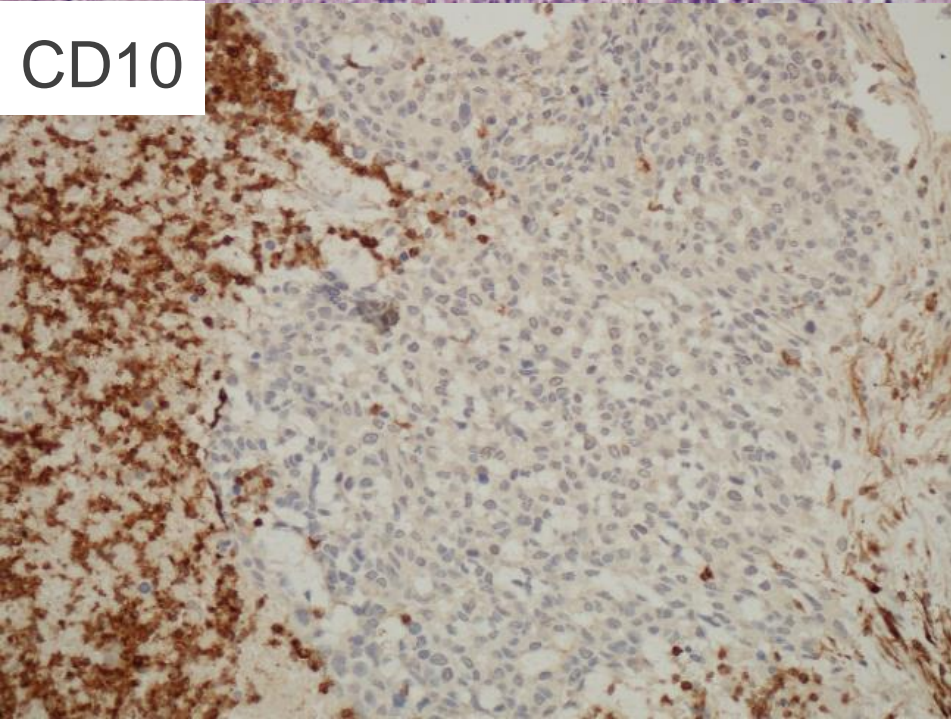
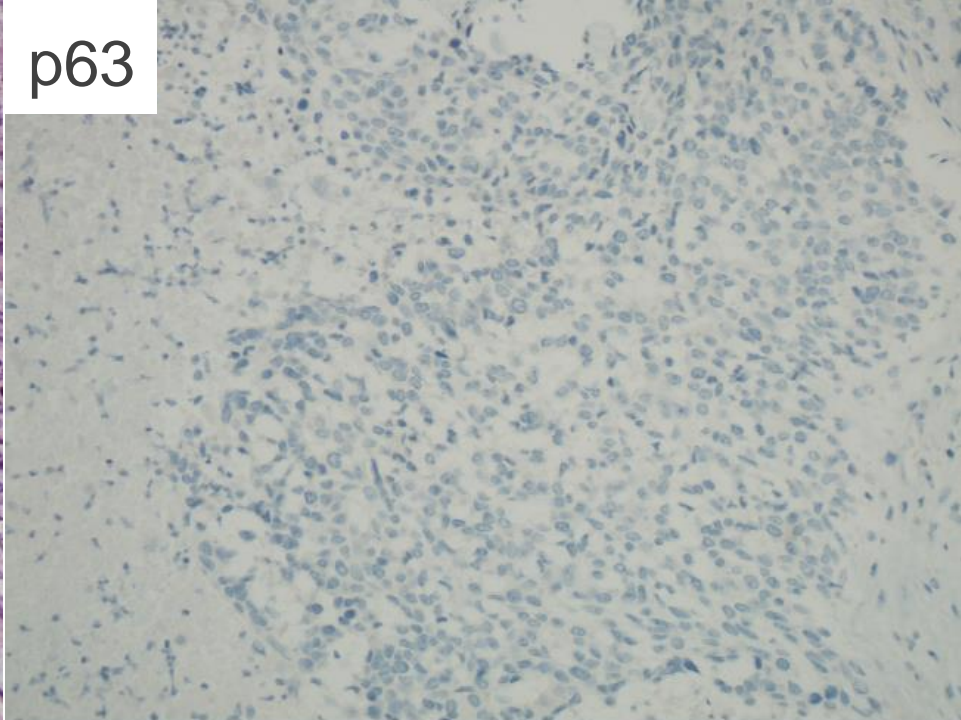
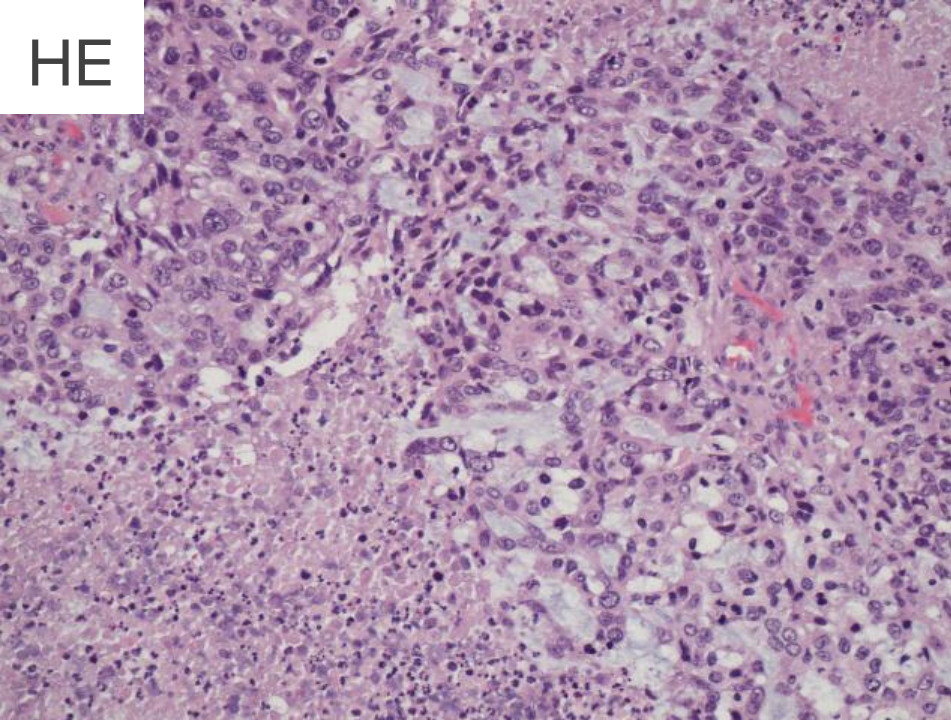


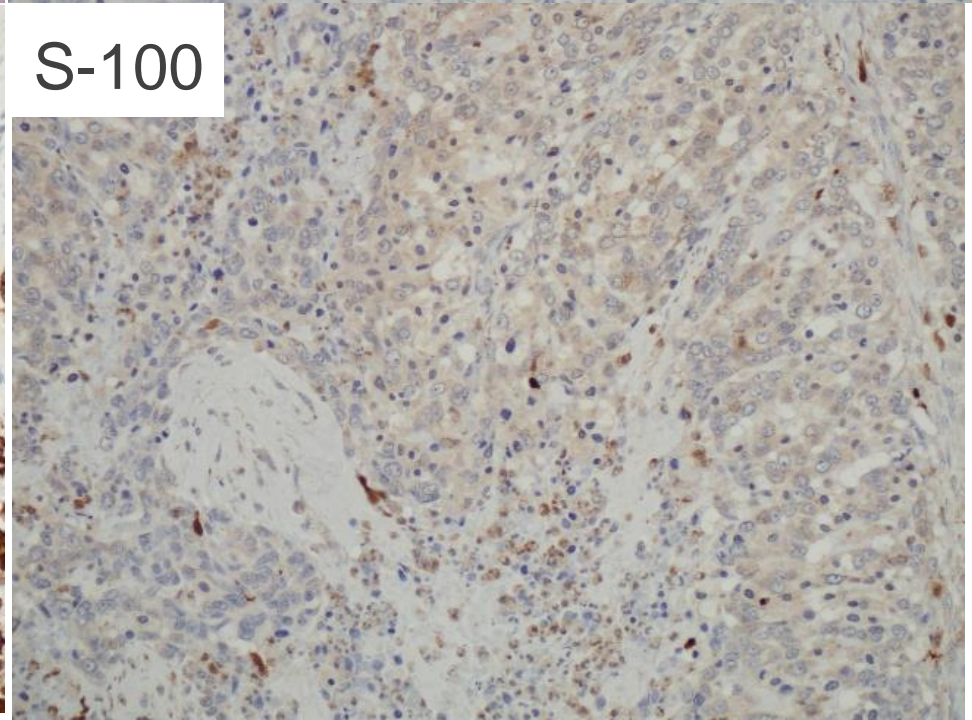
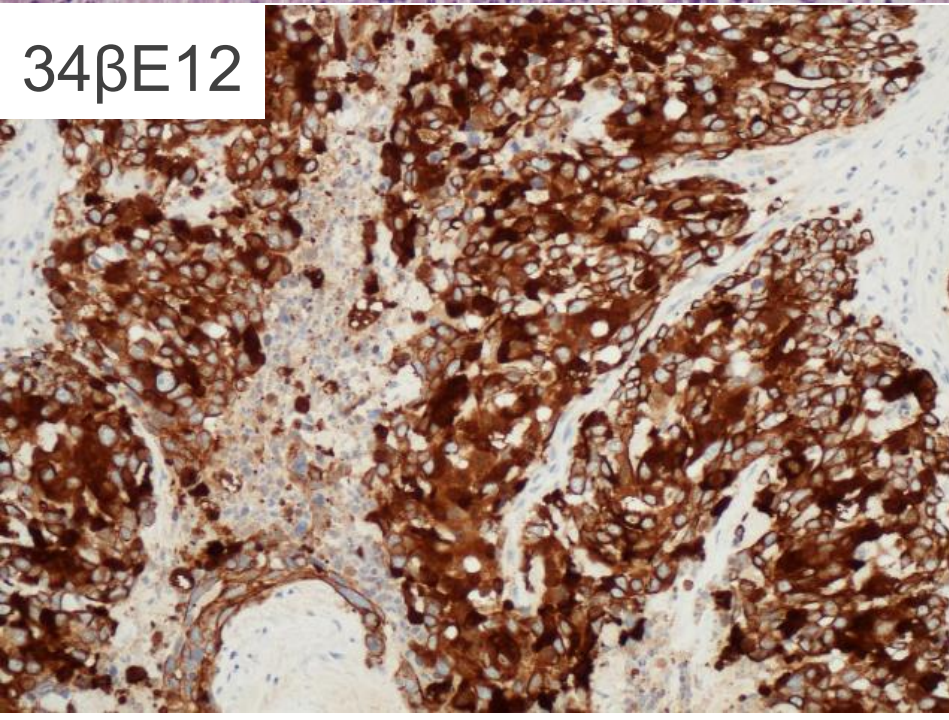
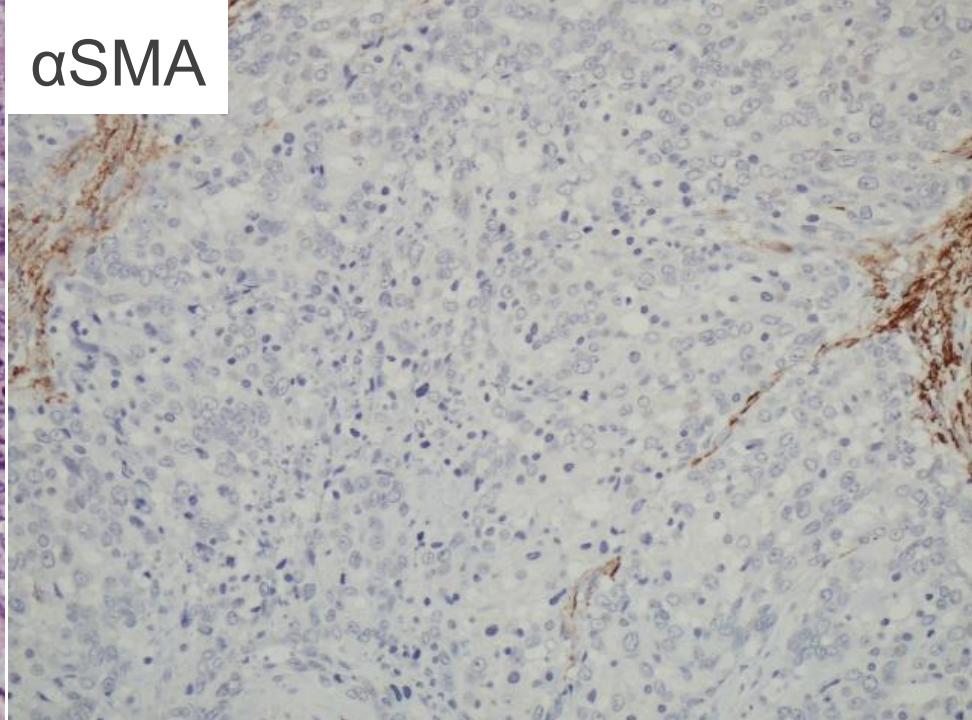
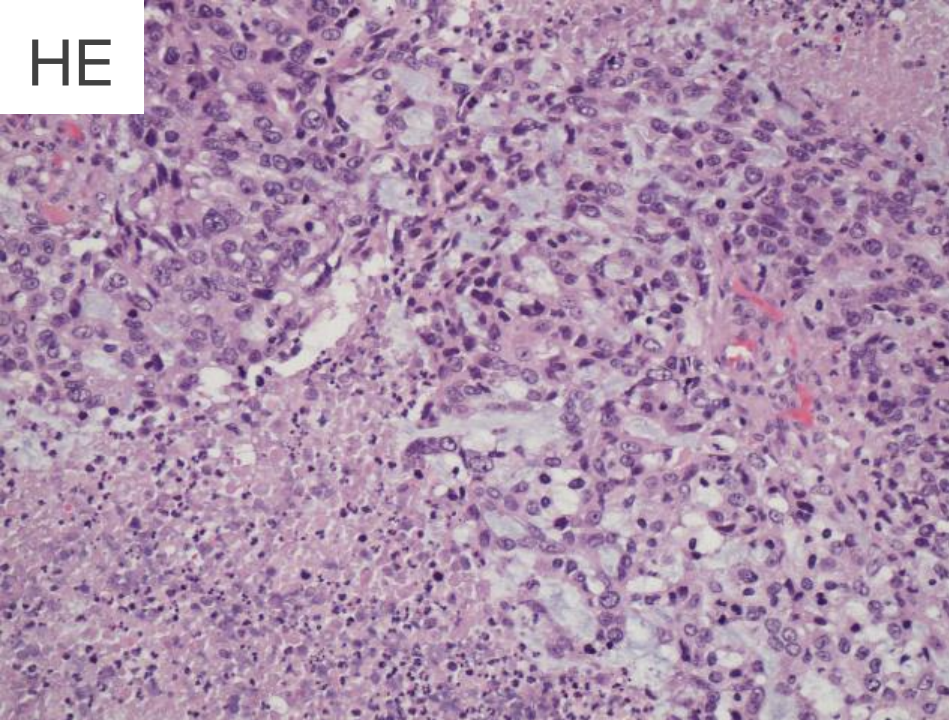
GFAP

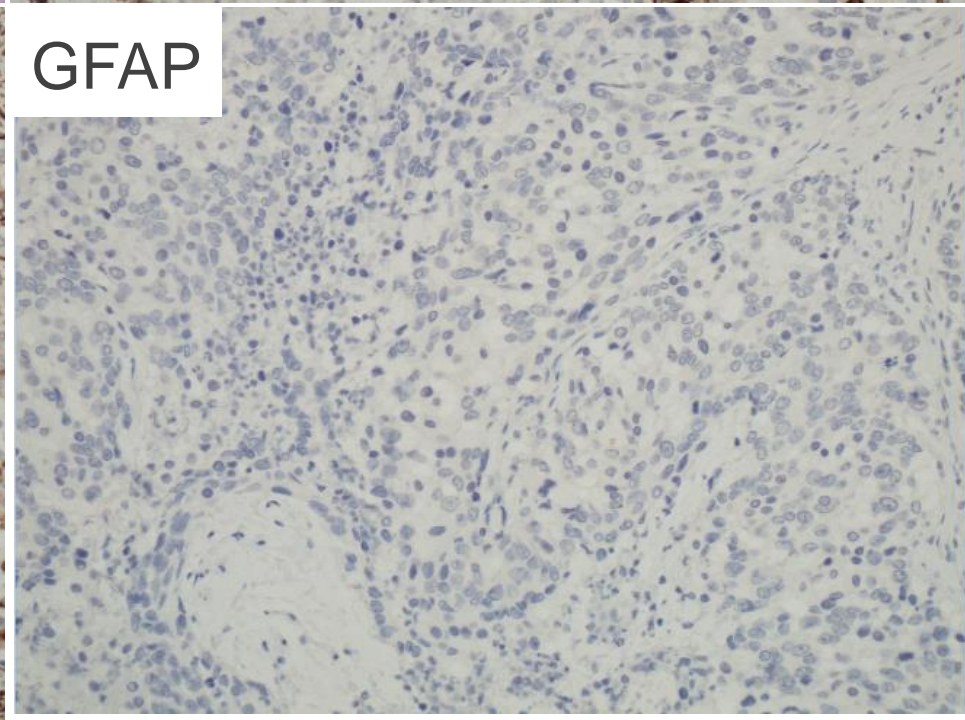
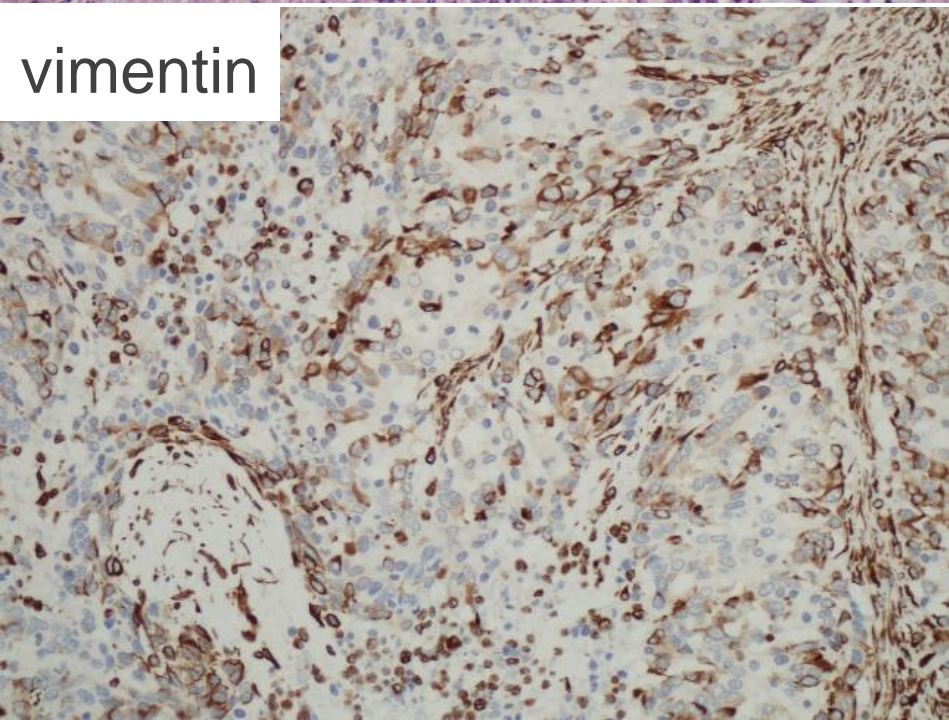
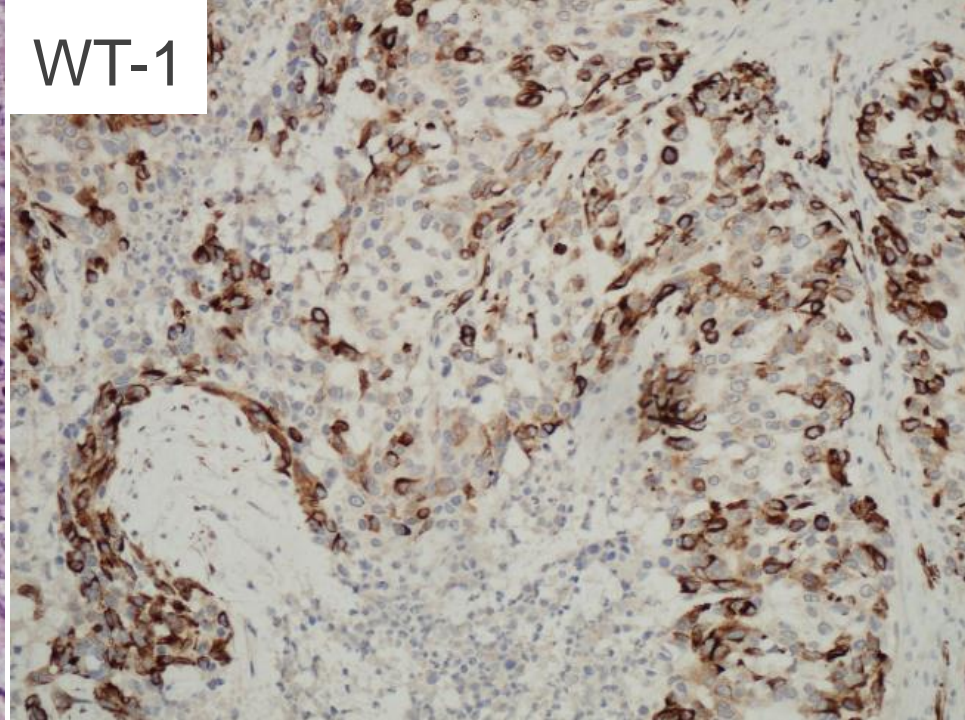
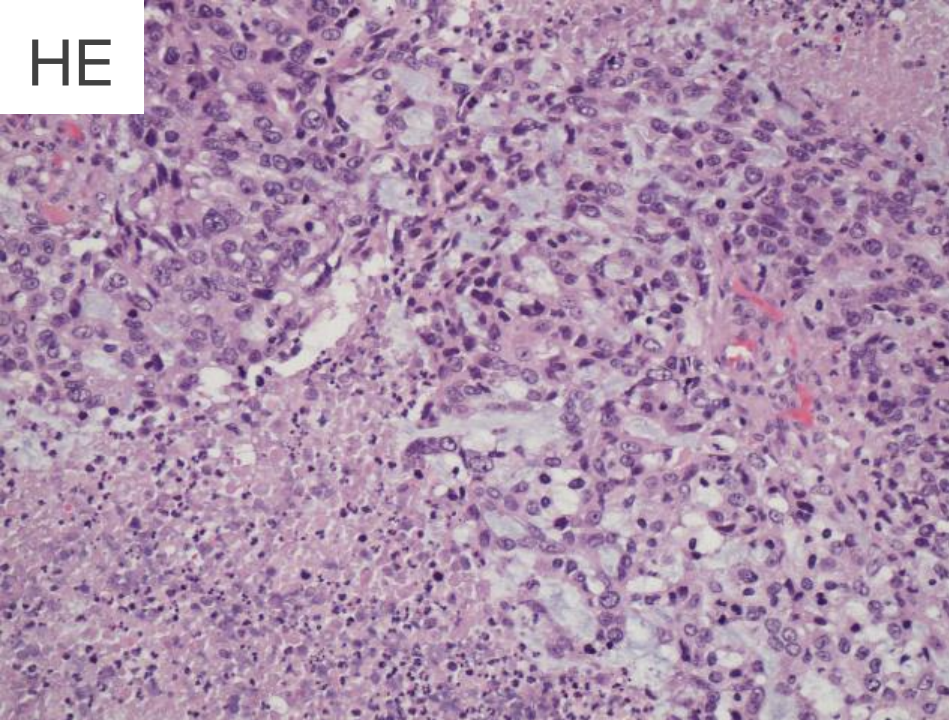


壊死が強くて一段異型が強い場所
はどうなのか・・・

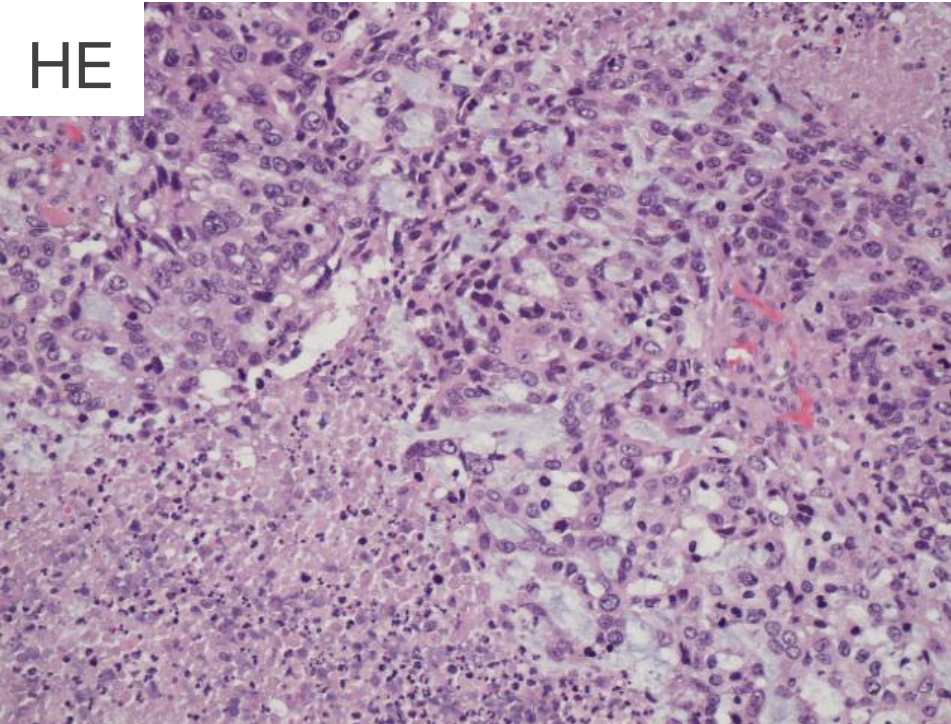




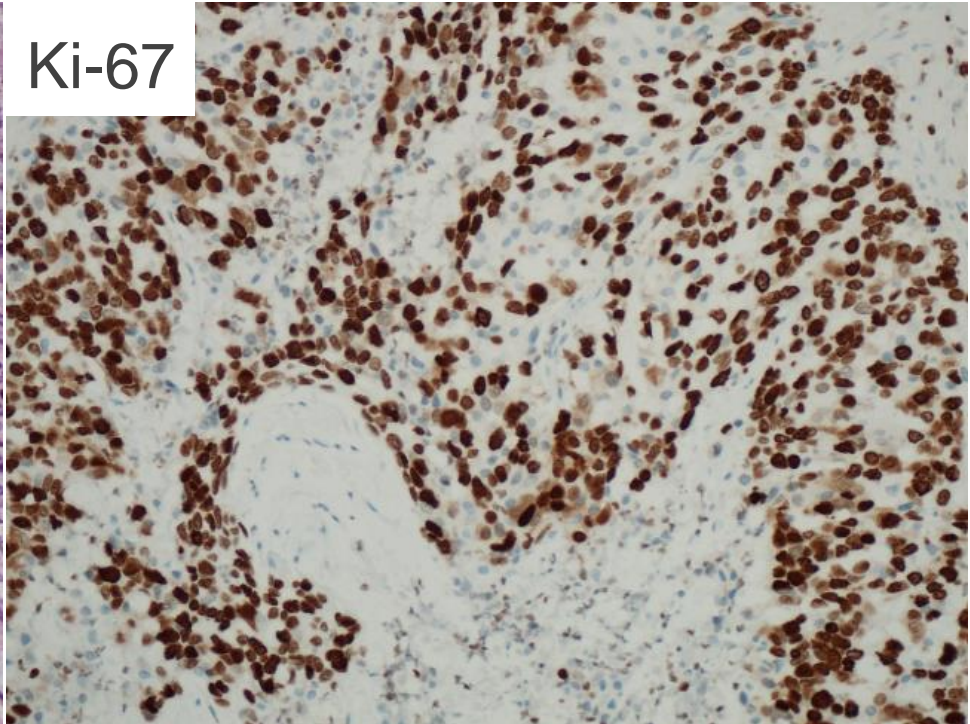




HE



Ki-67



carcinoma ex pleomorphic adenoma

多形腺腫由来癌



carcinoma ex pleomorphic adenoma

多形腺腫 (pleomorphic adenoma)の上皮/筋上皮成分の悪性化により癌腫を生じたもの

- 耳下腺に多く、他に顎下腺、小唾液腺、舌下腺にも生じる
- 60-70歳代に多い (pleomorphic adenomaより10歳以上遅い)
- 「もともとあった腫瘍がここ数ヶ月で大きくなった」というエピソードが典型的
- 全唾液腺腫瘍の3.6%、全唾液腺悪性腫瘍の12%

carcinoma ex pleomorphic adenomaの予後

- 浸潤なし (intracapsular)と被膜から1.5 mm未満の浸潤 (minimally invasive)は予後良好で、被膜から1.5 mm以上の浸潤 (invasive)は予後不良といわれていた
(転移25-75%、5年生存率25-65%、20年生存率0-38%)
- 2017年に改訂されたWHO分類第4版では、「被膜から4~6 mm未満の浸潤は予後良好」と修正された
- 癌腫成分の種類によって変わる

carcinoma ex pleomorphic adenomaの癌腫成分

- Salivary duct carcinoma
- Myoepithelial carcinoma
- Adenocarcinoma, NOS
- Squamous cell carcinoma
- Undifferentiated carcinoma
- epithelial-myoepithelial carcinoma
- polymorphous low-grade adenocarcinoma
- mucoepidermoid carcinoma
- carcinosarcoma

など

どの筋上皮系マーカーを使えば・・・

古典的なマーカー

S100

actin (α SMA, HHF35)

vimentin

GFAP

MHC

Cytokeratin (CK14)

新しいマーカー

p63

CD10

calponin

WT-1

DOG-1

maspin

上記のマーカーを併用するのが最も有用である

まとめ

- 「以前からある頸部腫瘍の増大」では、carcinoma ex pleomorphic adenomaを鑑別に挙げ、pleomorphic adenomaが含まれているかを確認する。
- Myoepithelial carcinoma ex pleomorphic adenomaの場合、特異的な筋上皮系マーカーがないため、筋上皮マーカーを組合せ、組織像も合わせて判断する。

ご清聴ありがとうございました
今後ともよろしくお願いいたします。

