

# 顎下腺腫瘍

松野岳志<sup>1)</sup>、西村広健<sup>1)</sup>、福田裕次郎<sup>2)</sup>、森谷卓也<sup>1)</sup>

1) 川崎医科大学 病理学

2) 同 耳鼻咽喉科学

## 【症例】

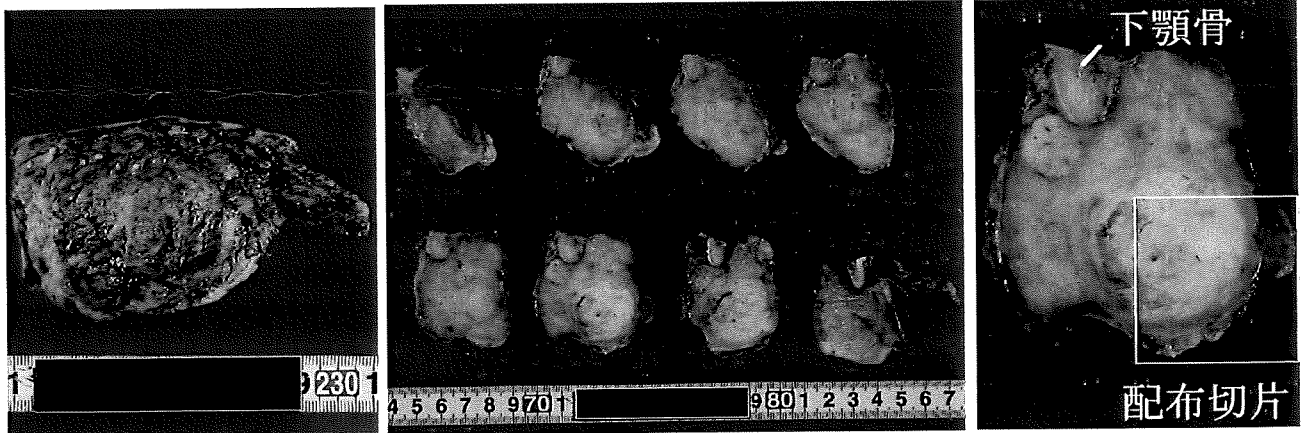
50 歳代男性

## 【現病歴】

約 20 年前に左顎下部の腫瘍を自覚し、近医で唾液腺感染症と診断された。経過を観察していたが、年単位で徐々に、さらに 1 年前から急速に増大し切除された。

## 【肉眼所見】

割面白色調の境界不明瞭な 10cm 大の腫瘍で、内部に黄色結節状の領域が混在していた。



## 【問題点】

病理診断

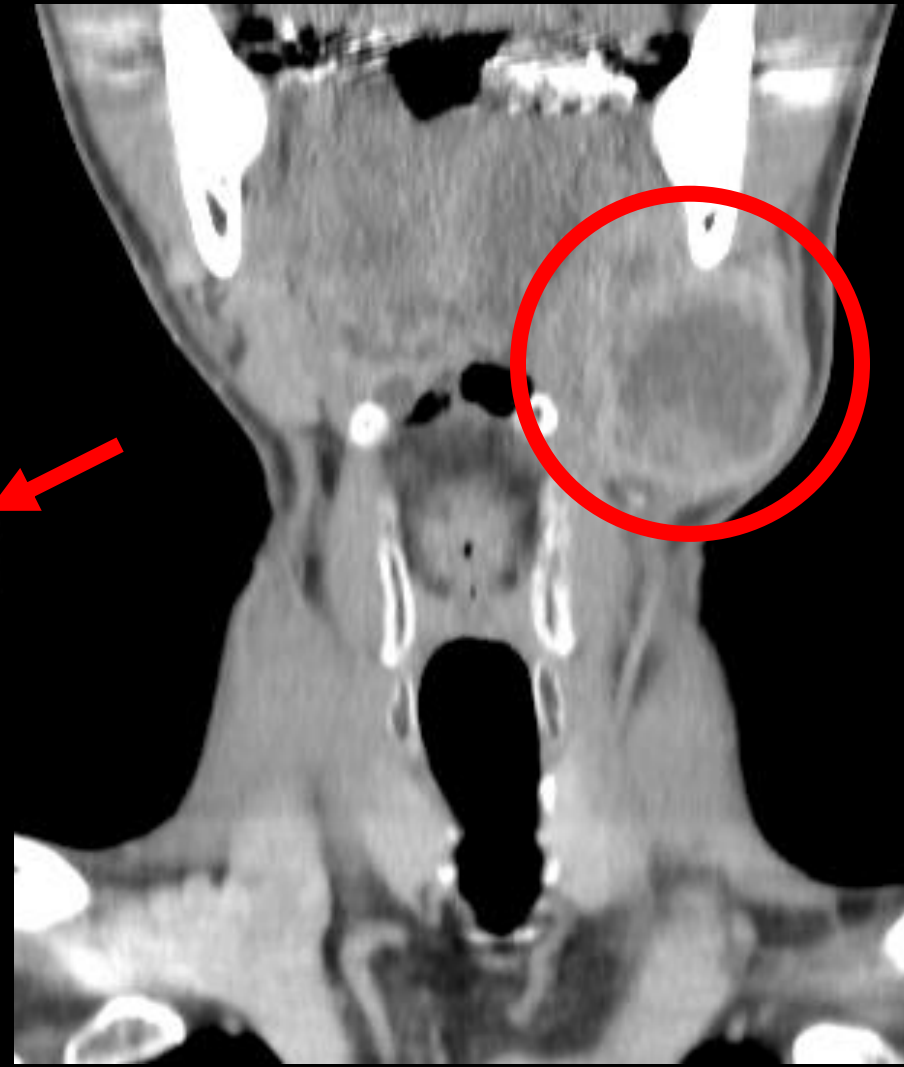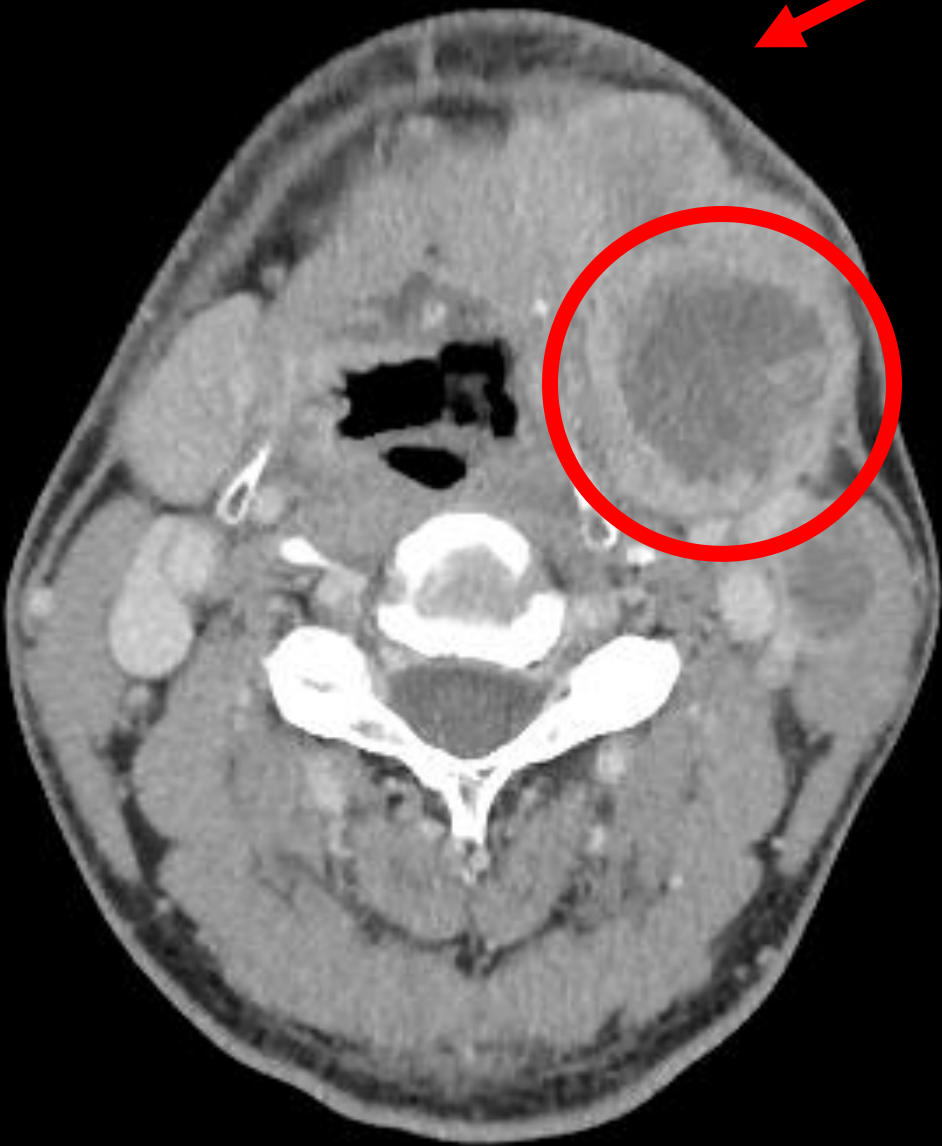## 【症例】

50歳代男性

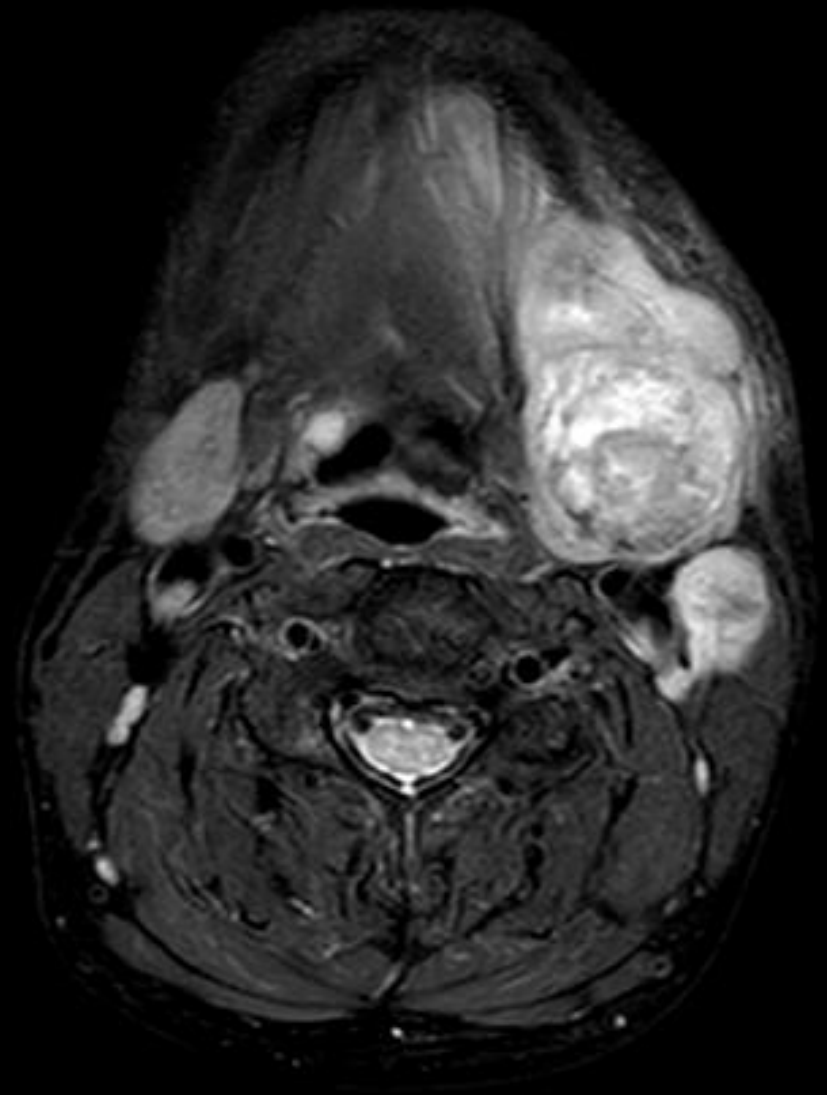
## 【現病歴】

約20年前に左顎下部の腫瘍を自覚し、近医で唾液腺感染と診断された。経過を観察していたが、年単位で徐々に、1年前から急速に増大し、切除された。

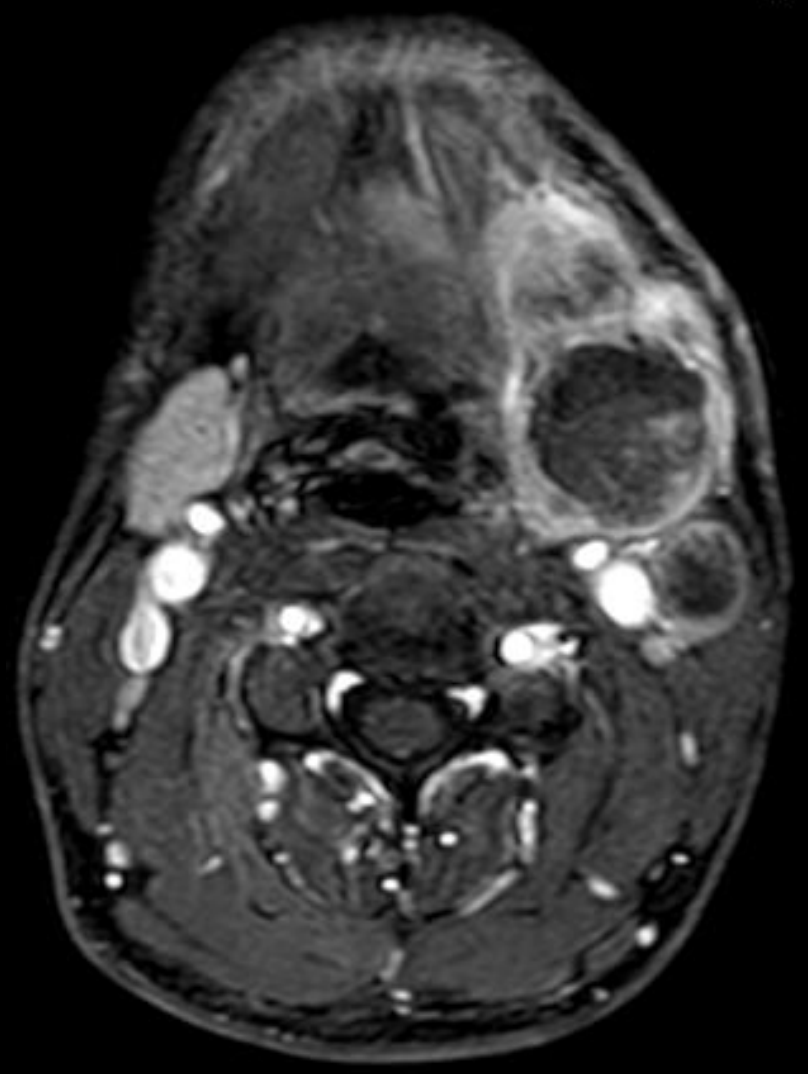
CT所見



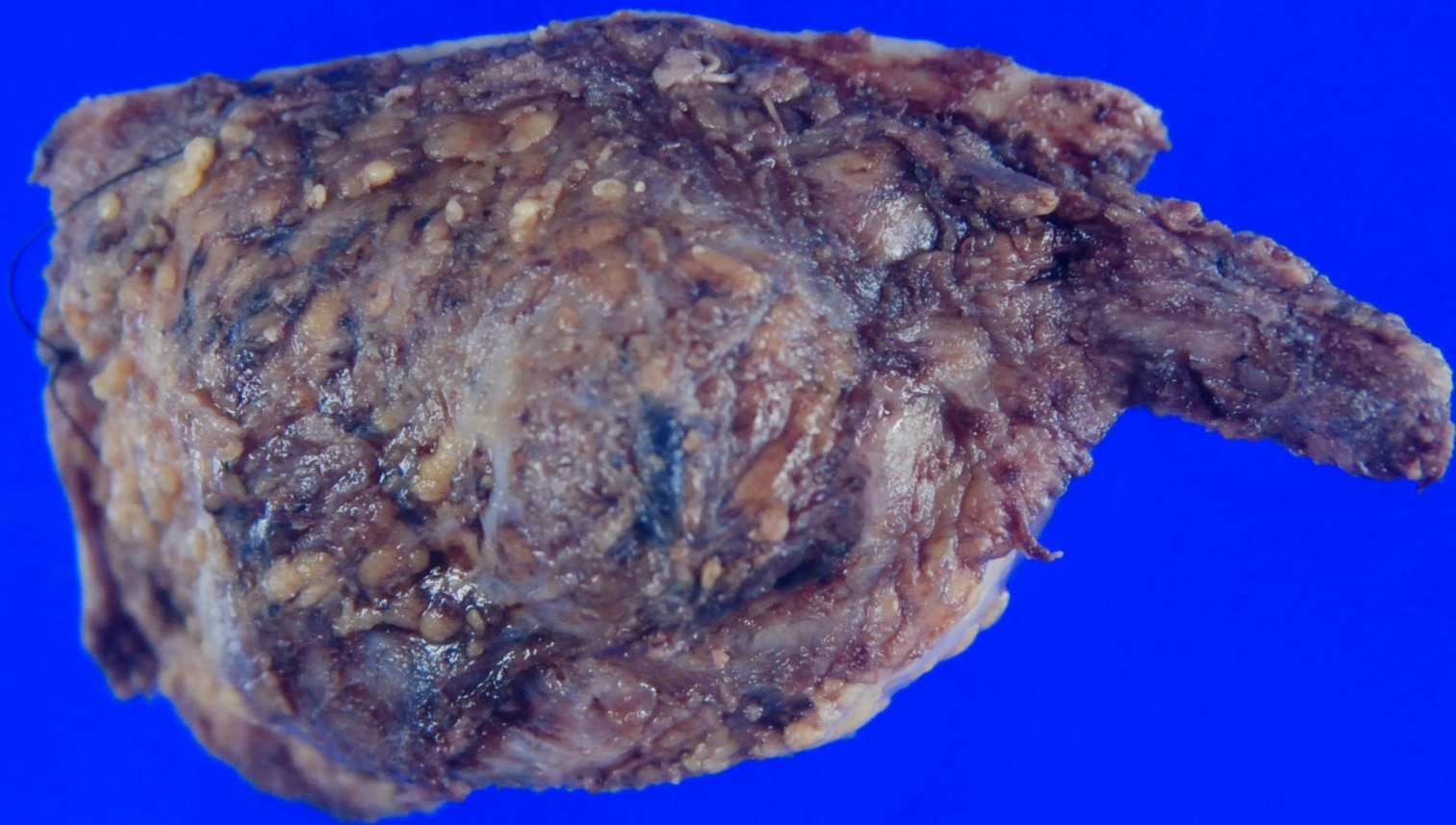# MRI所見



T2-FS

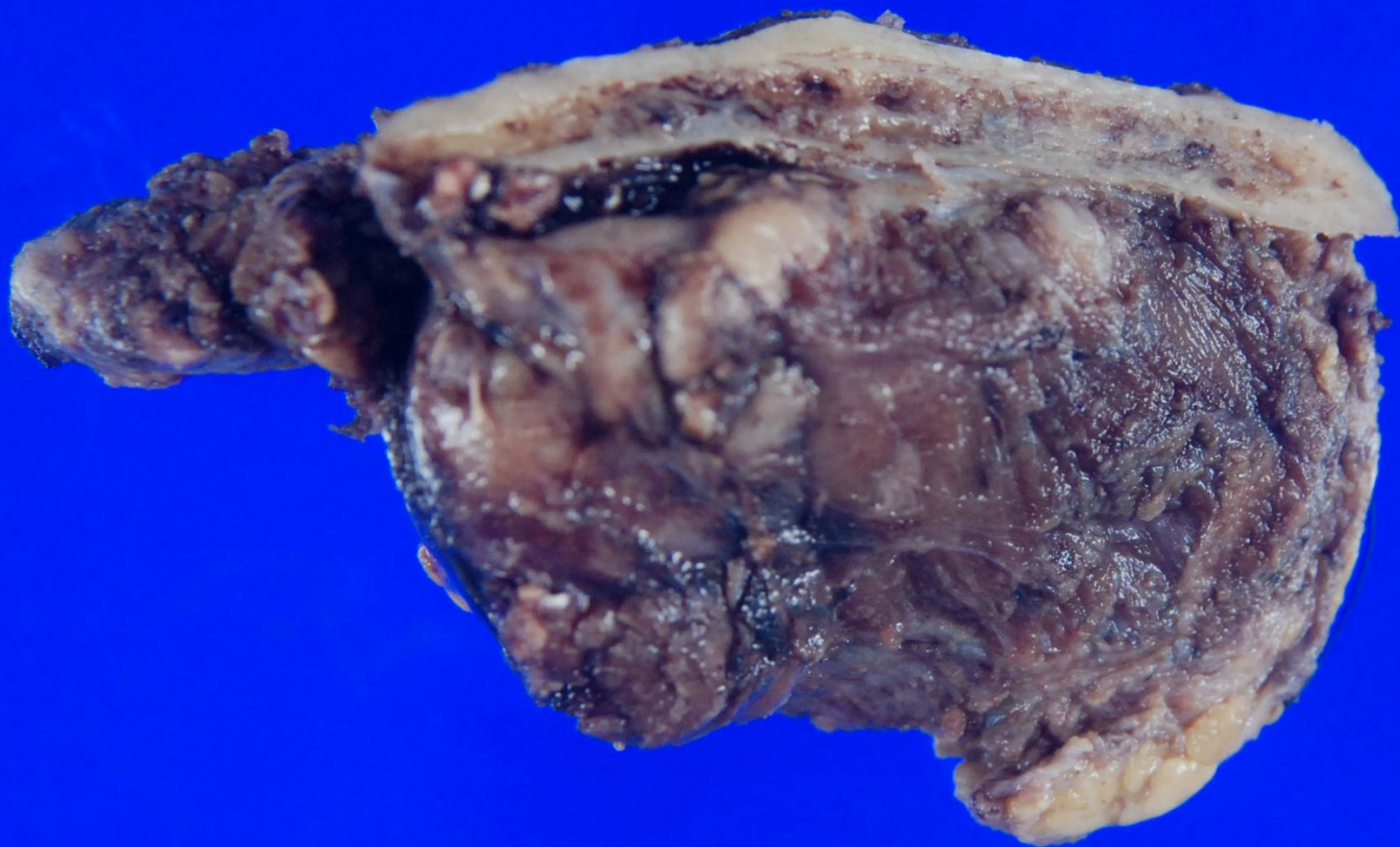


造影T1



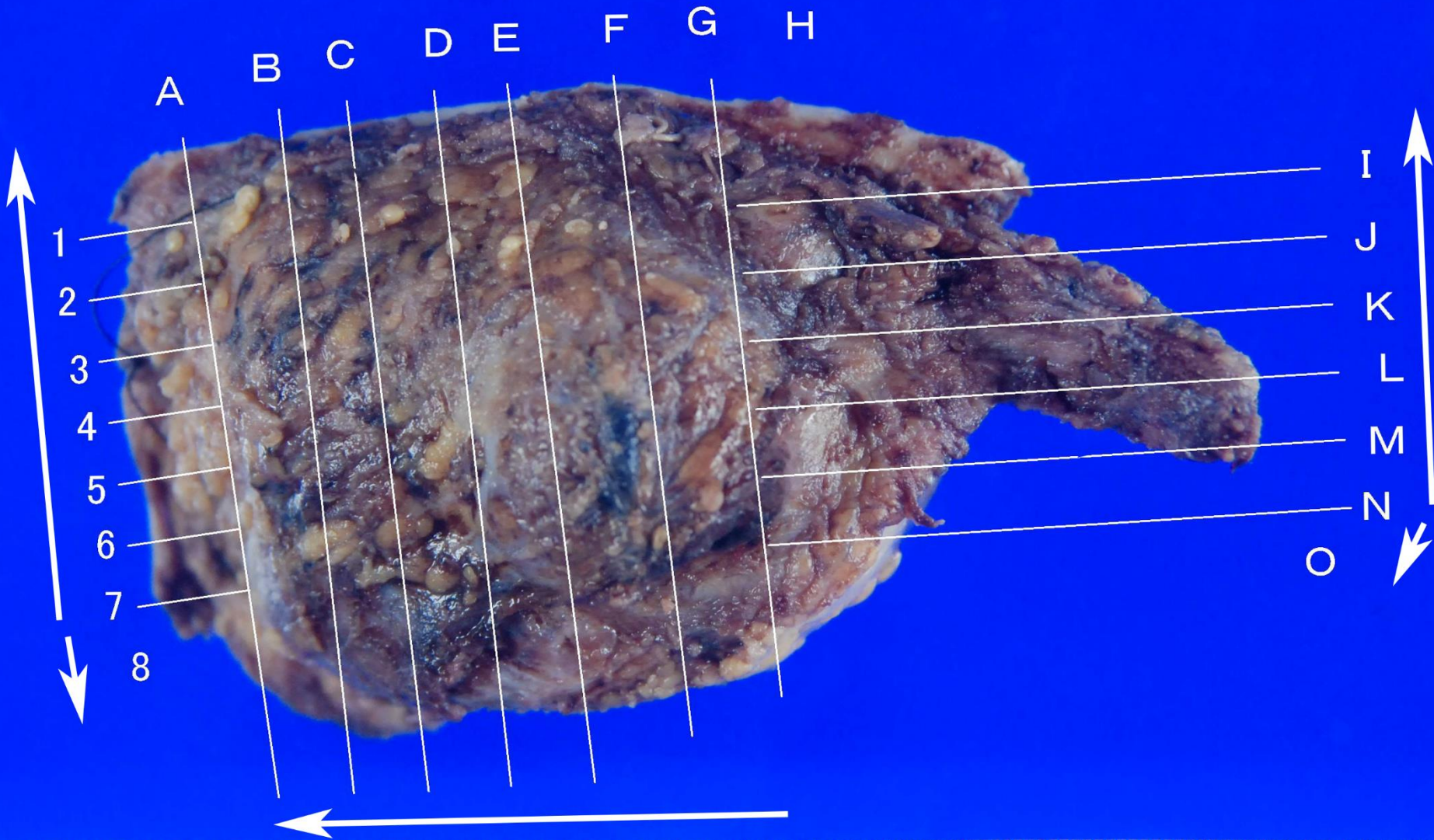
10.1x4.9x3.1cm





10.1x4.9x3.1cm

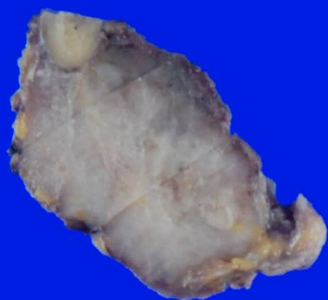




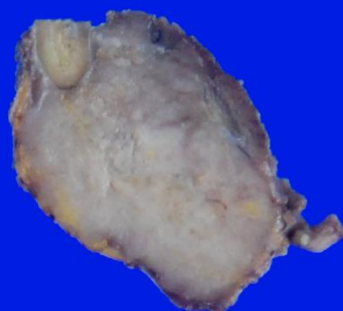A



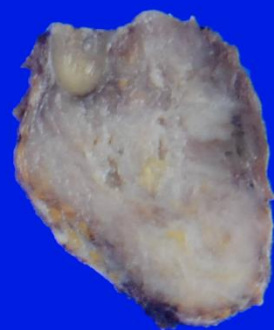B



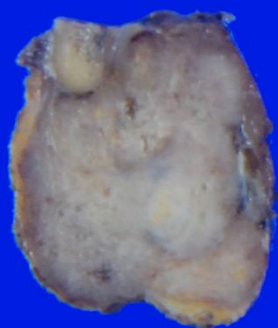
C



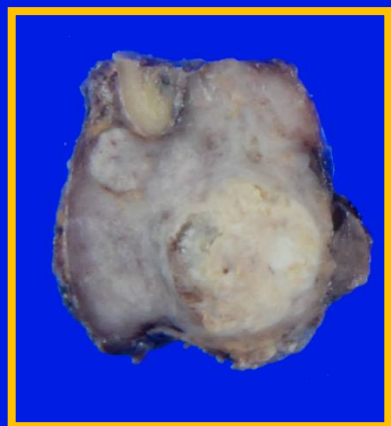
D



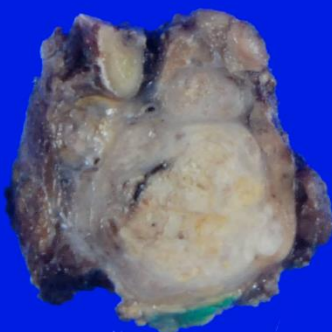
E




F



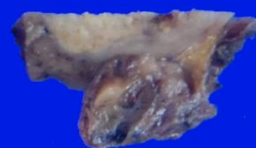G



I



K



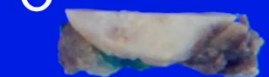M



N

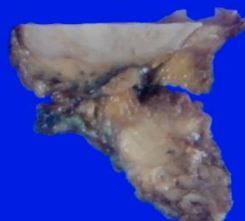


O

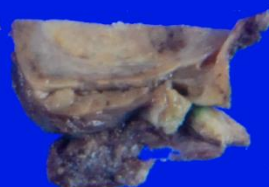

H

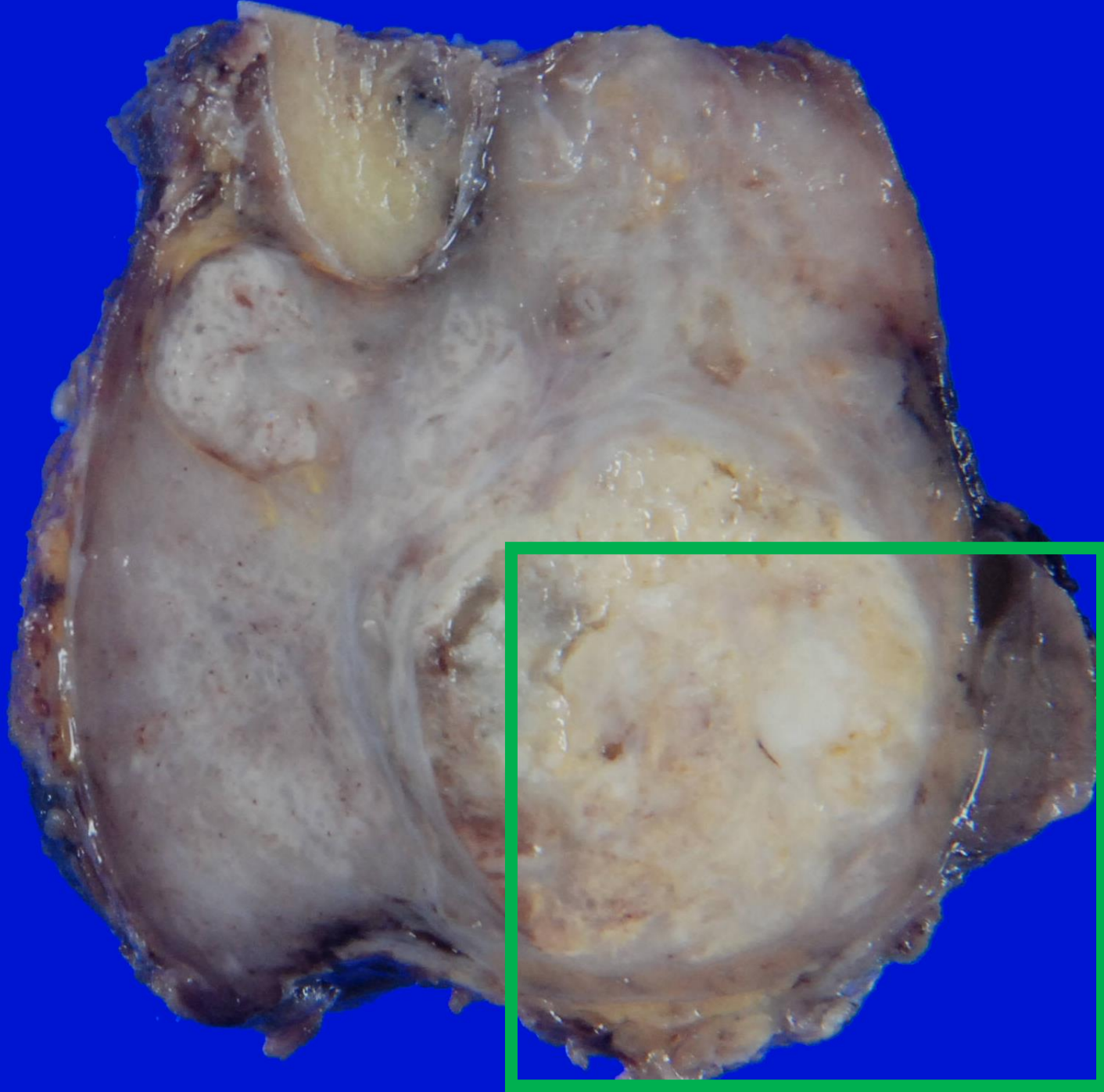
J



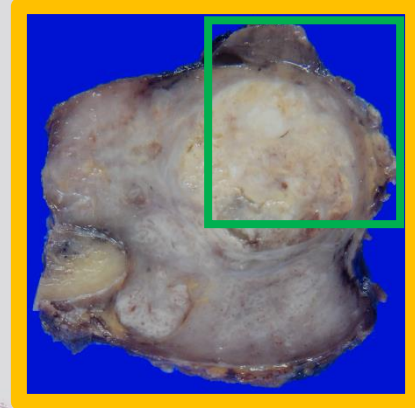
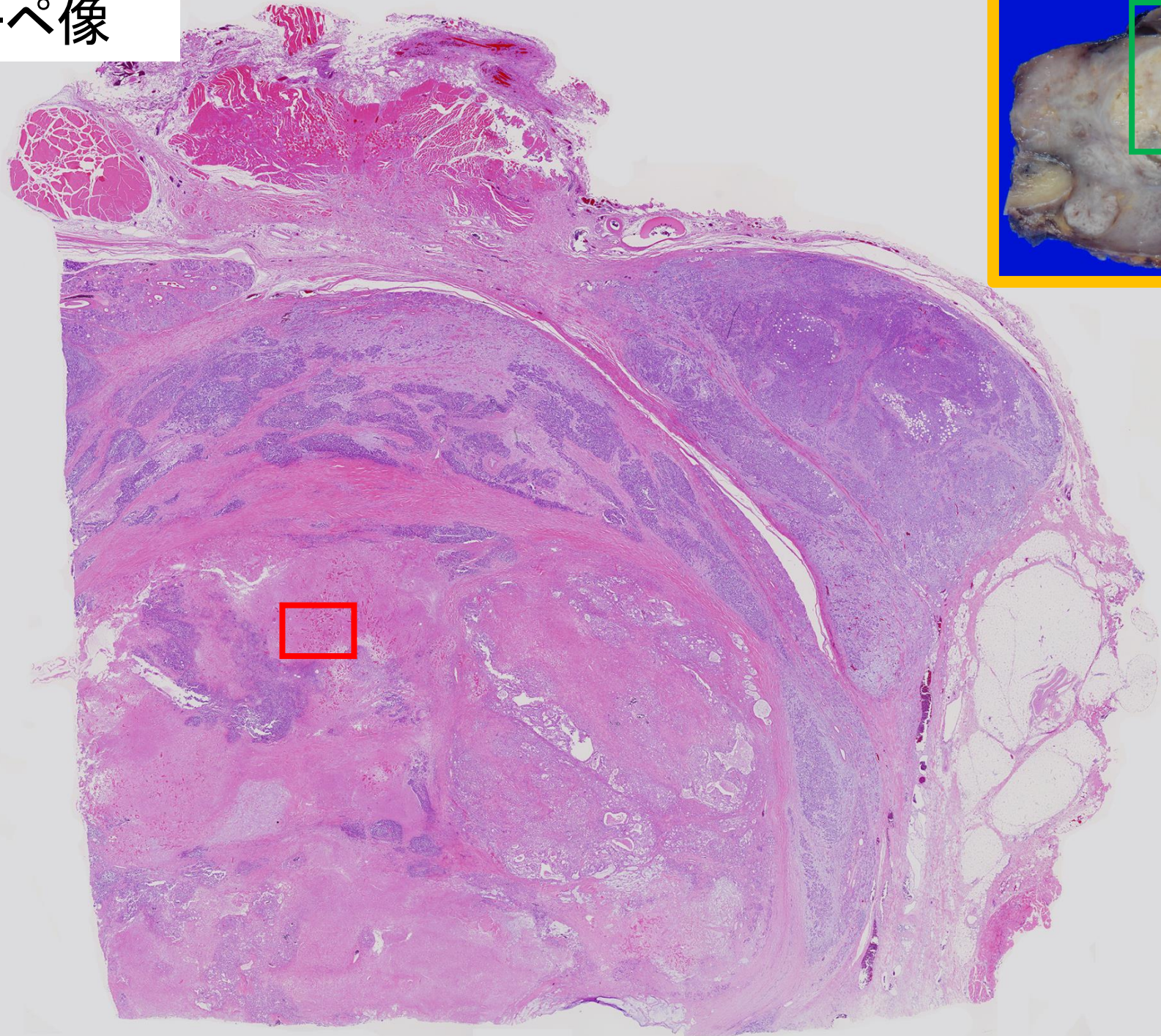
L



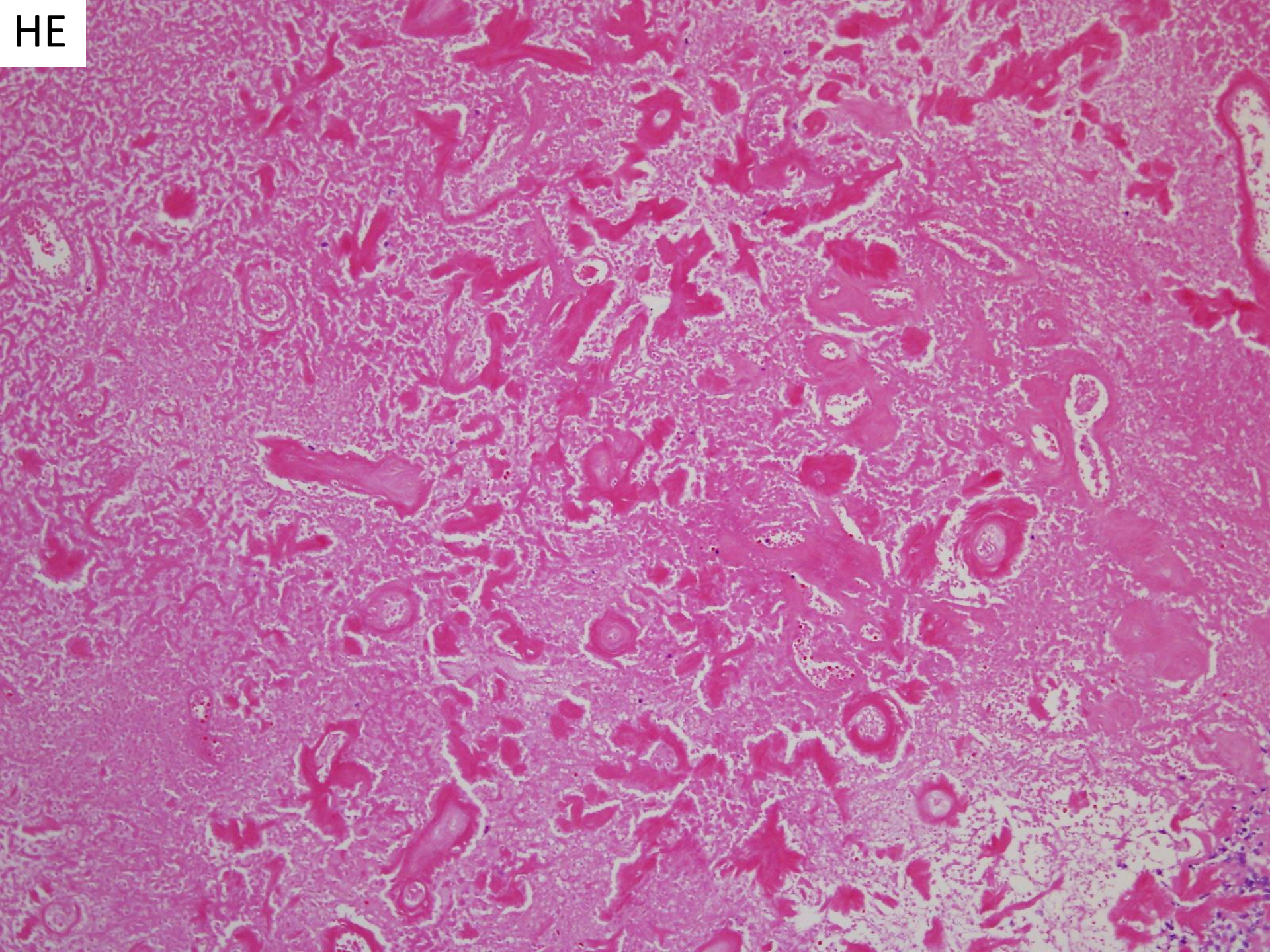




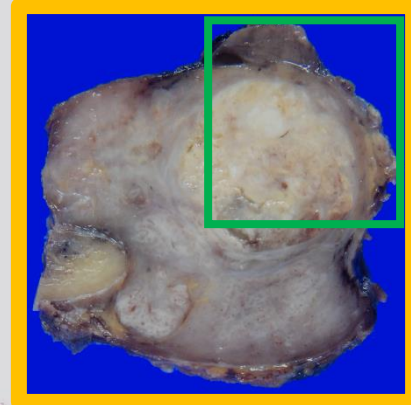
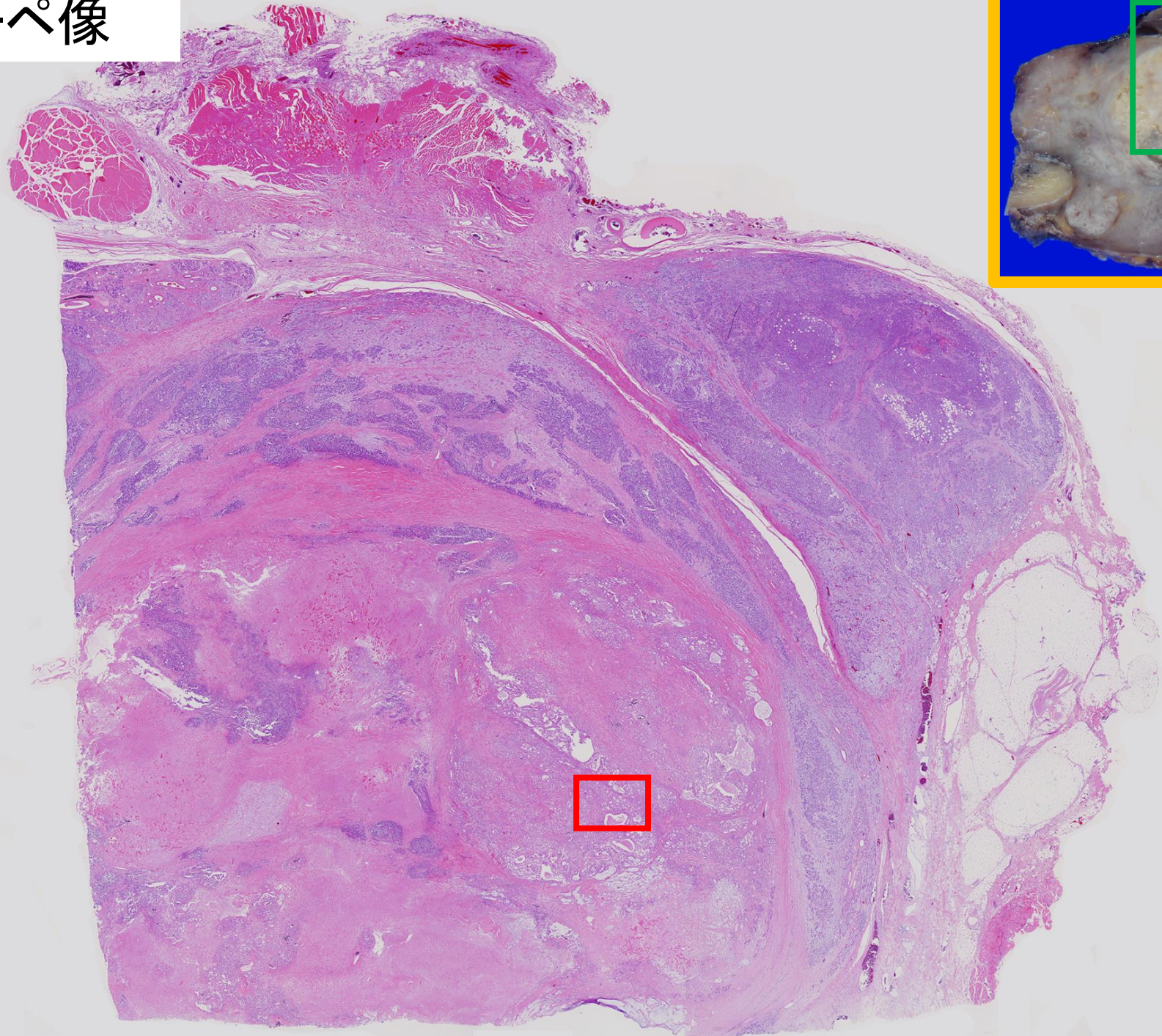
ルーペ像



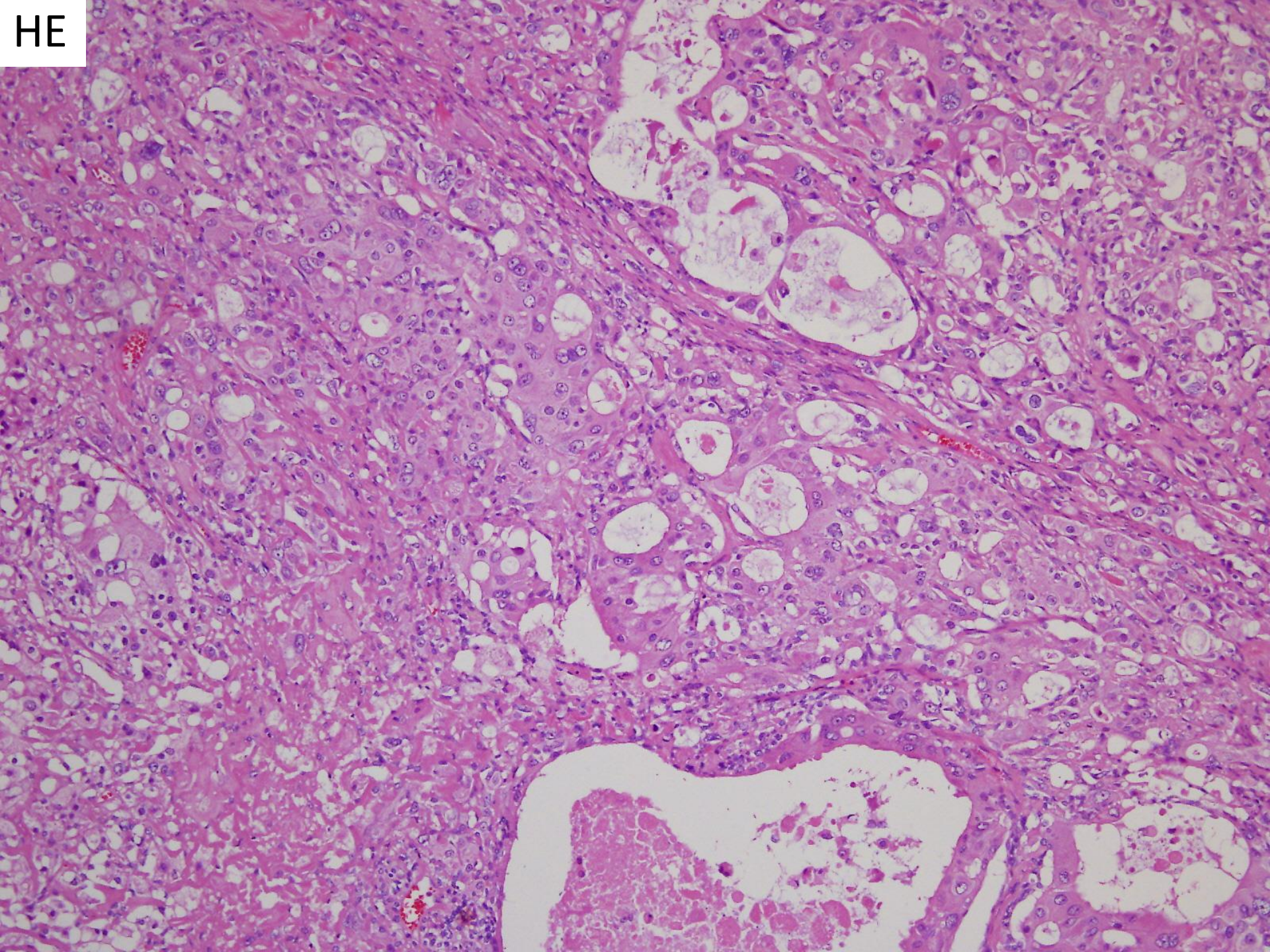
HE



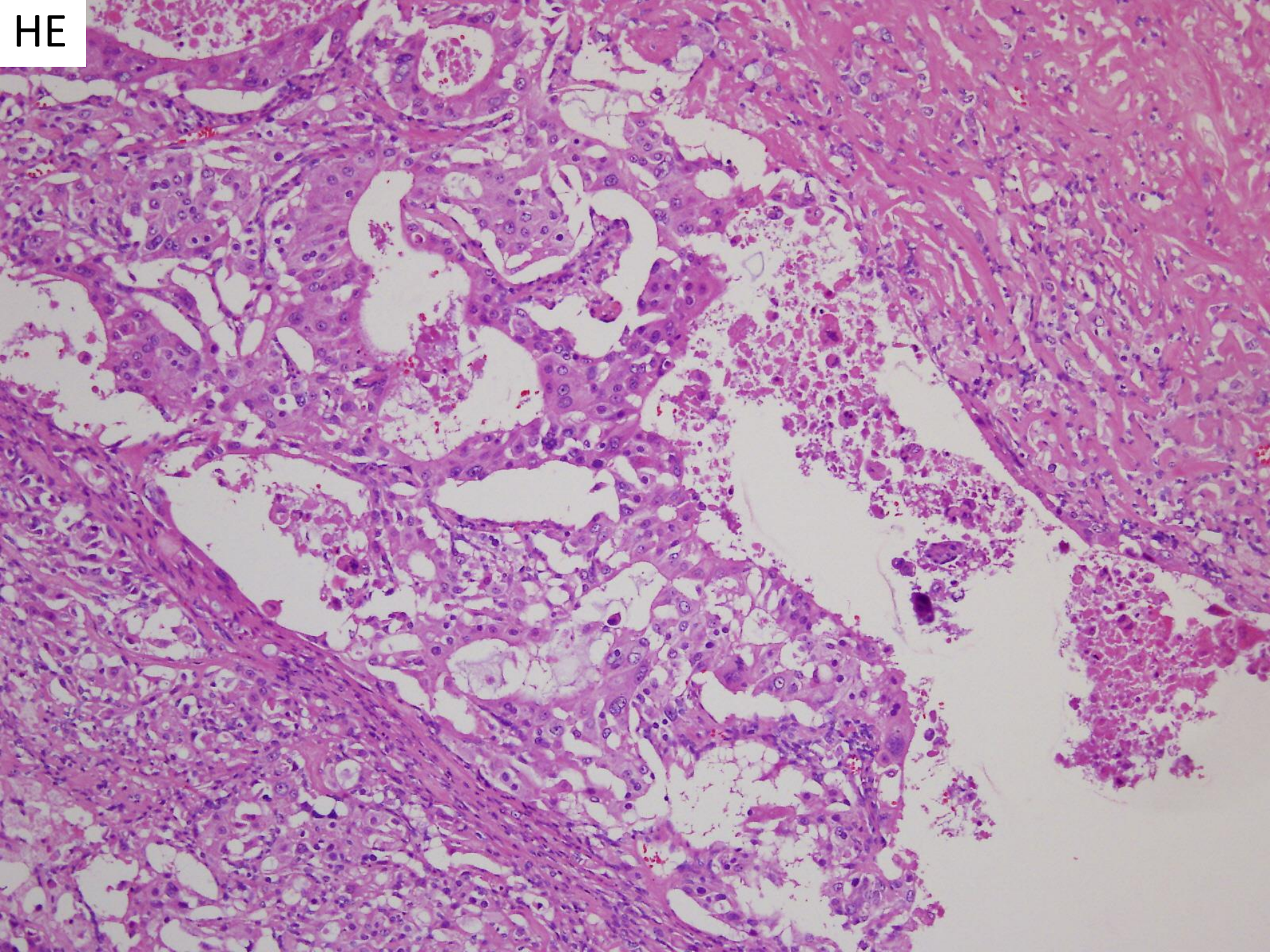
ルーペ像



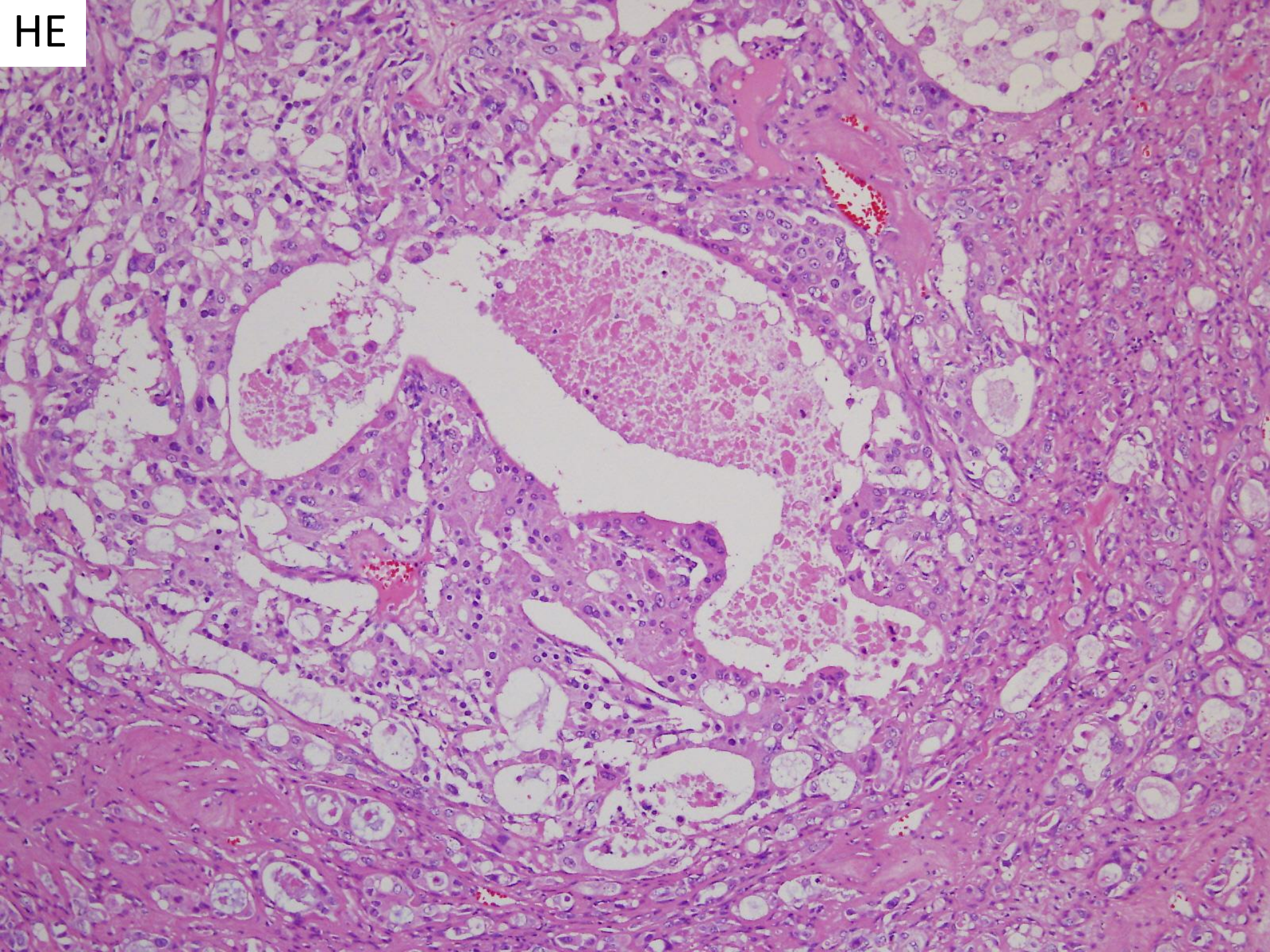
HE

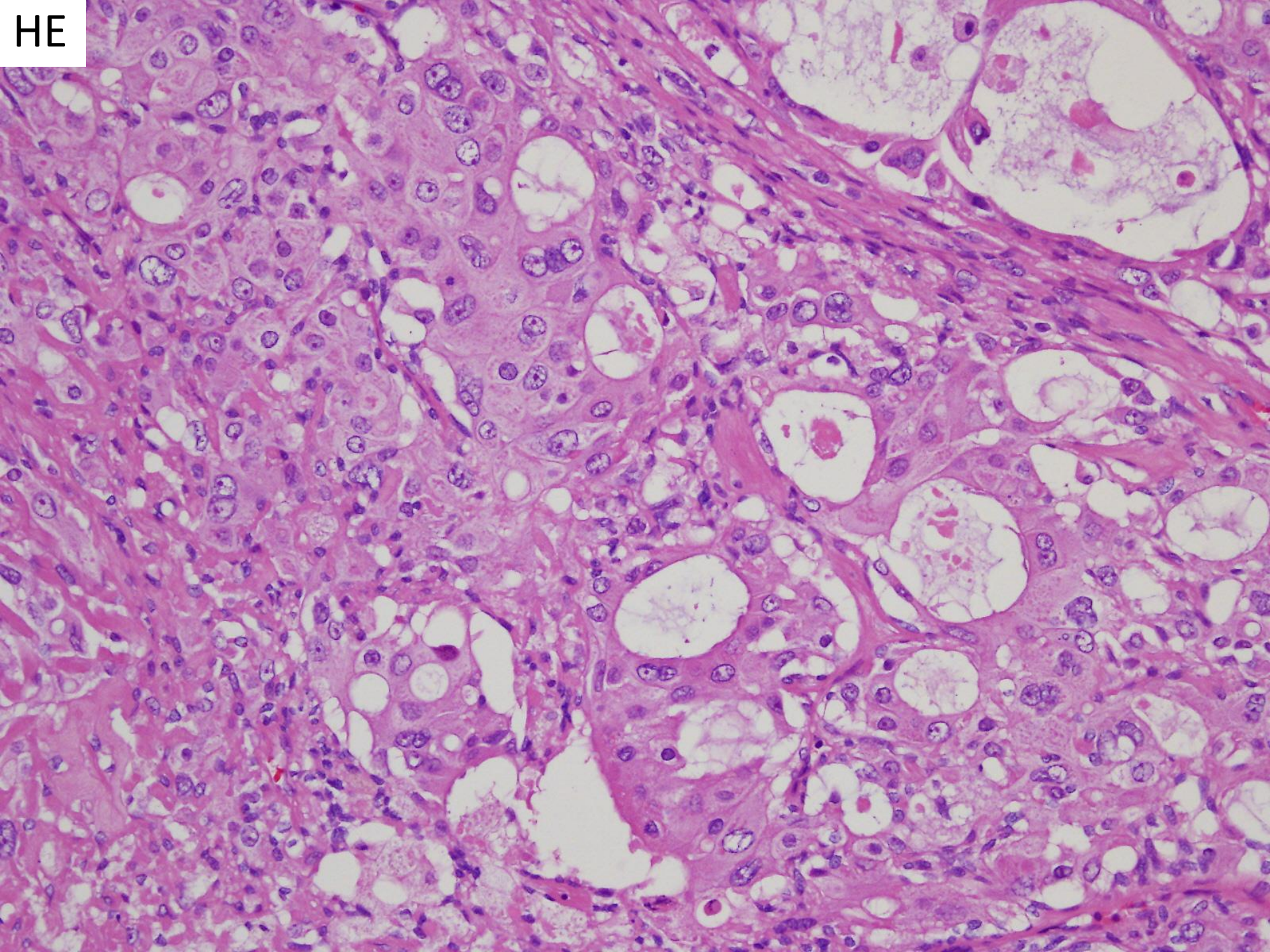


HE



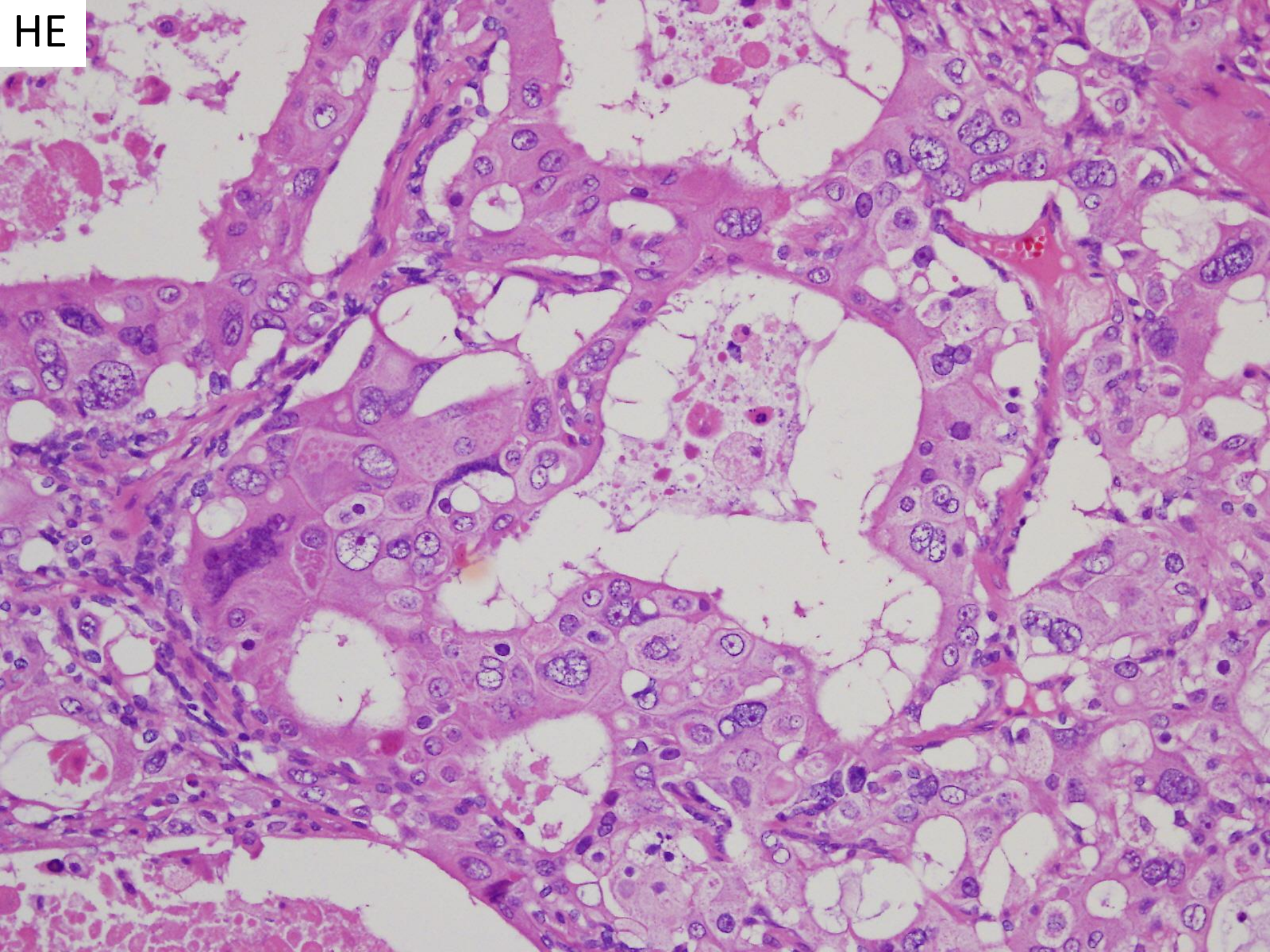
HE



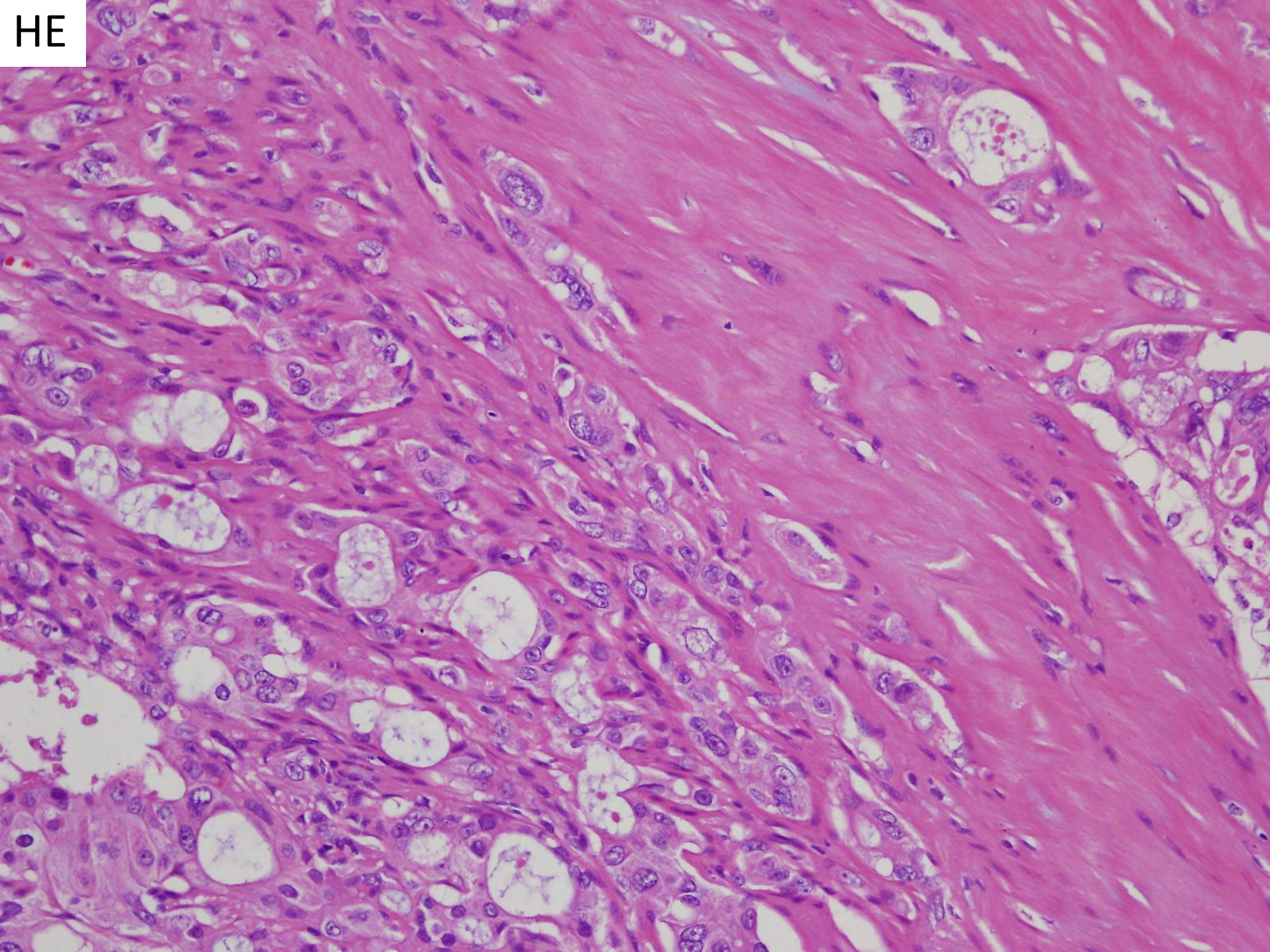




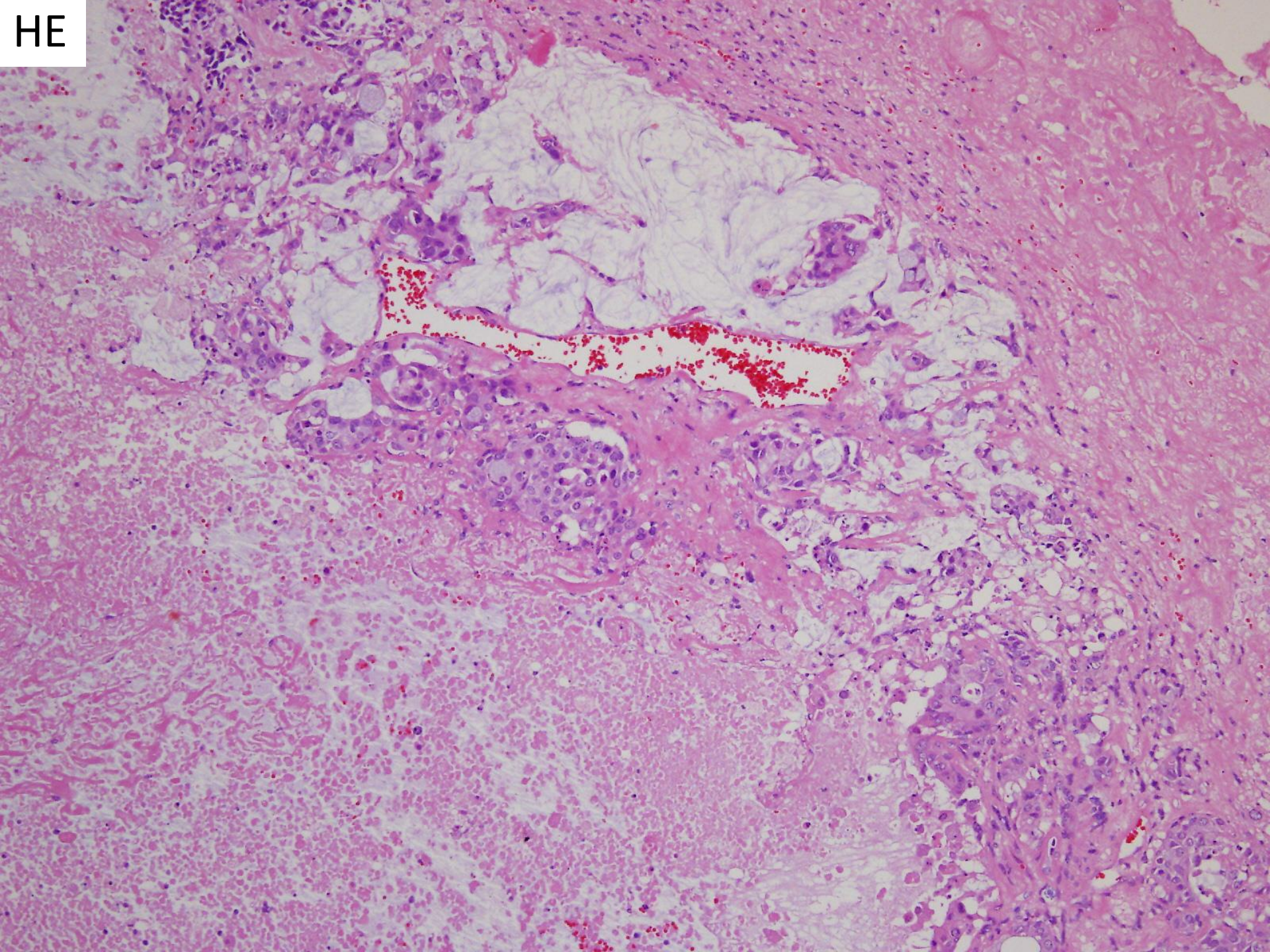
HE



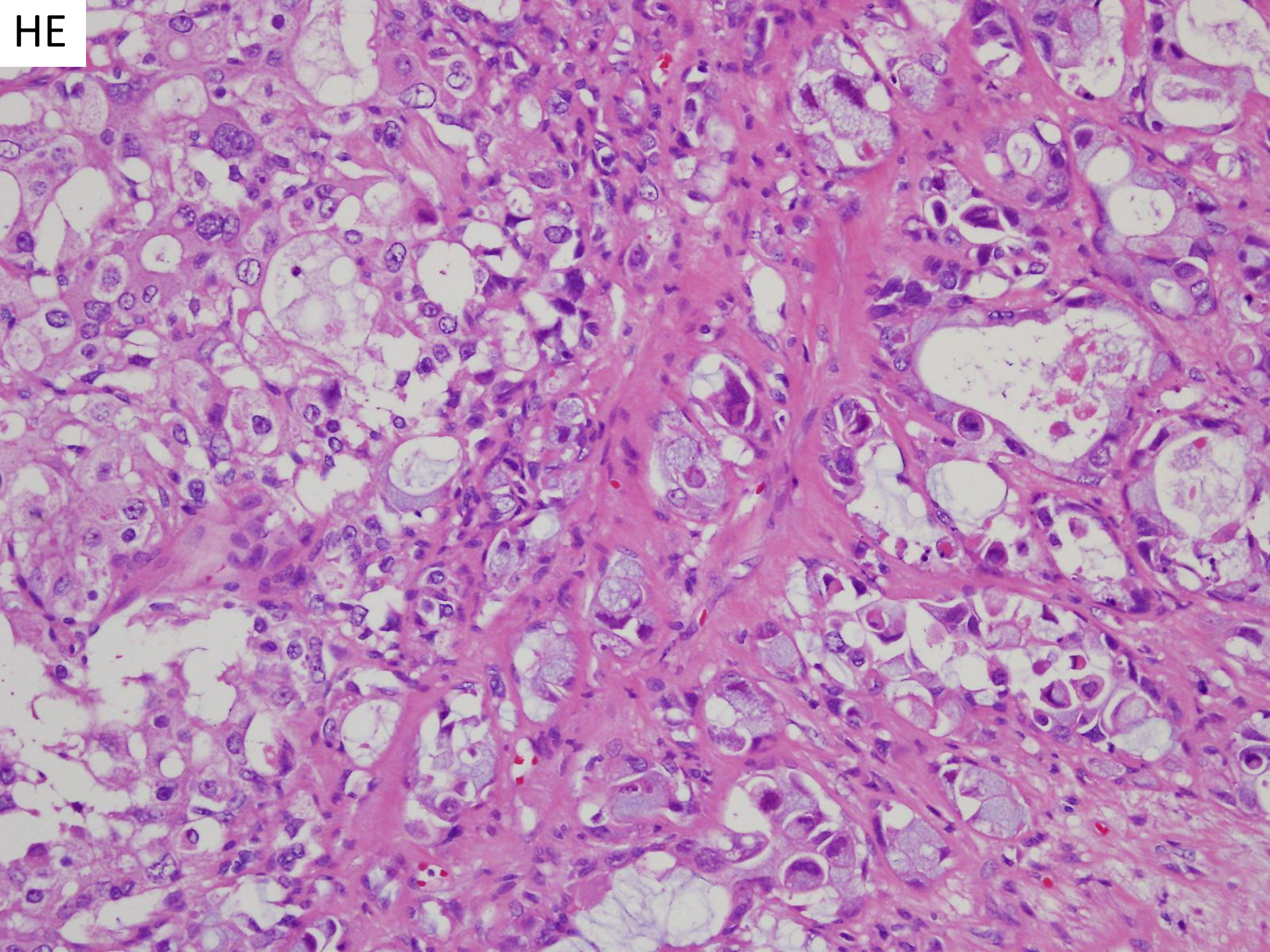
HE



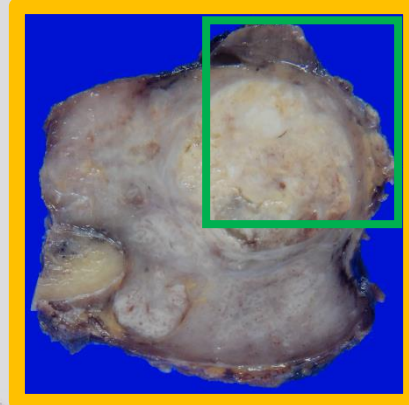
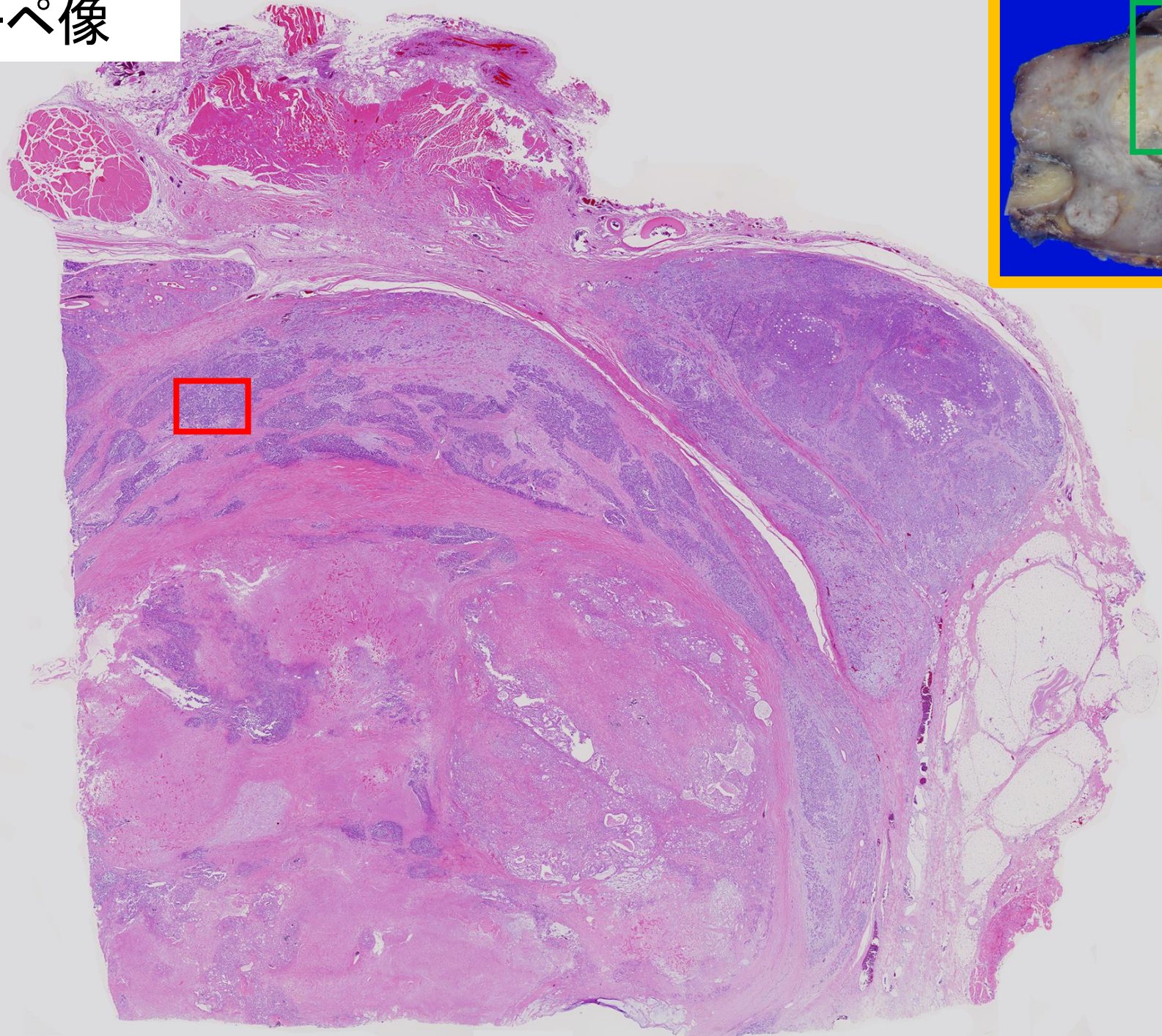
HE



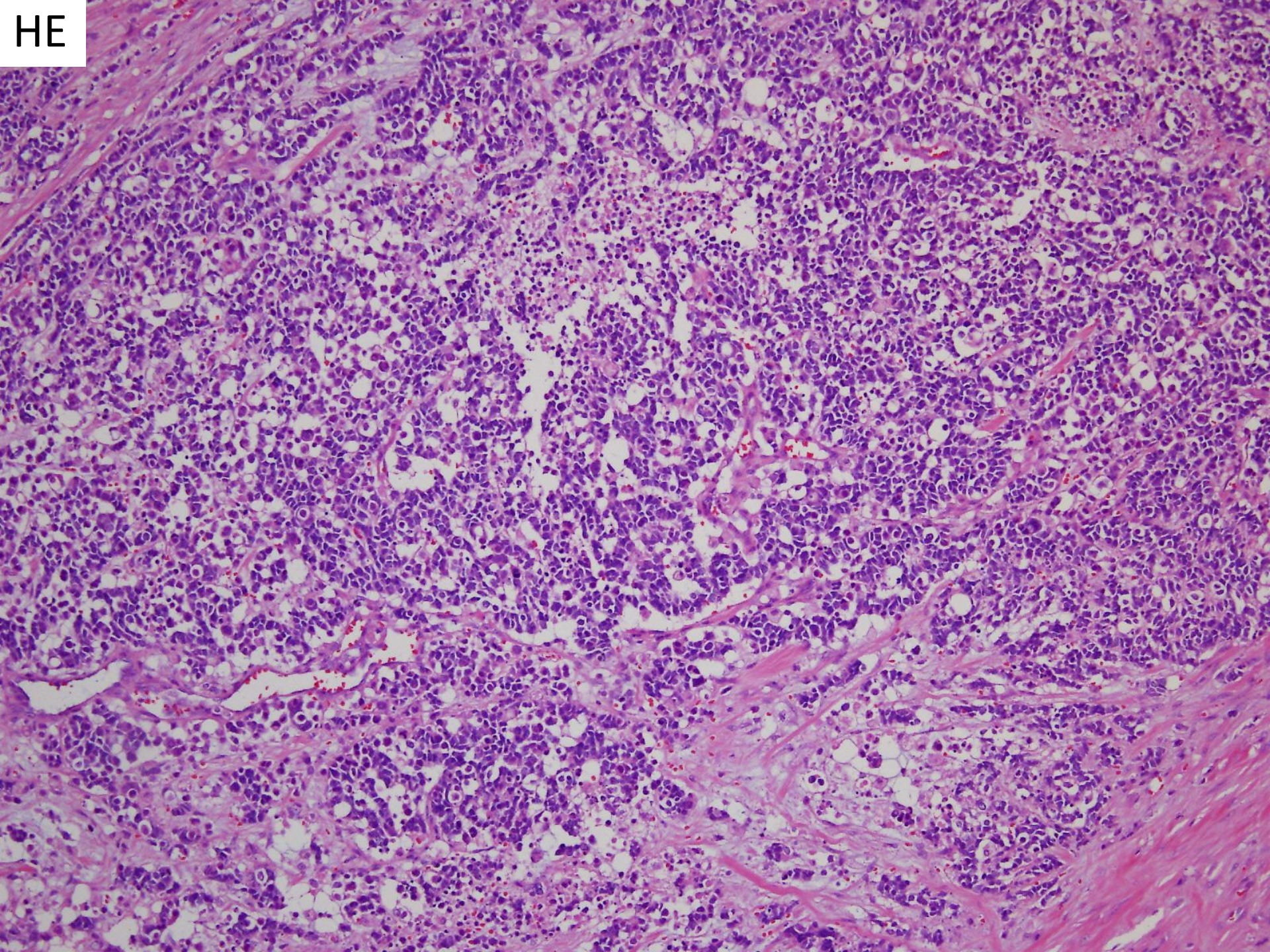
HE



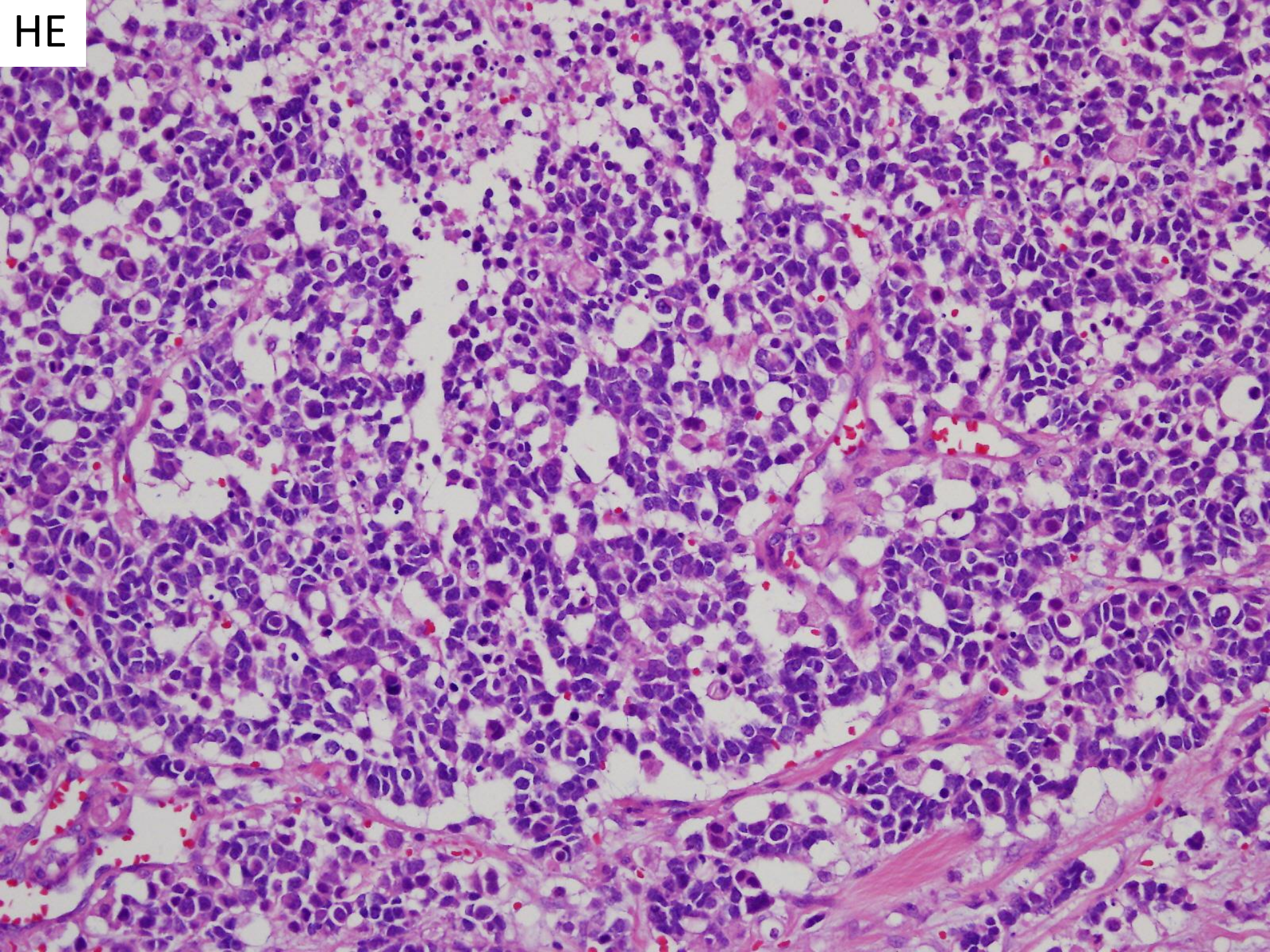
ルーペ像



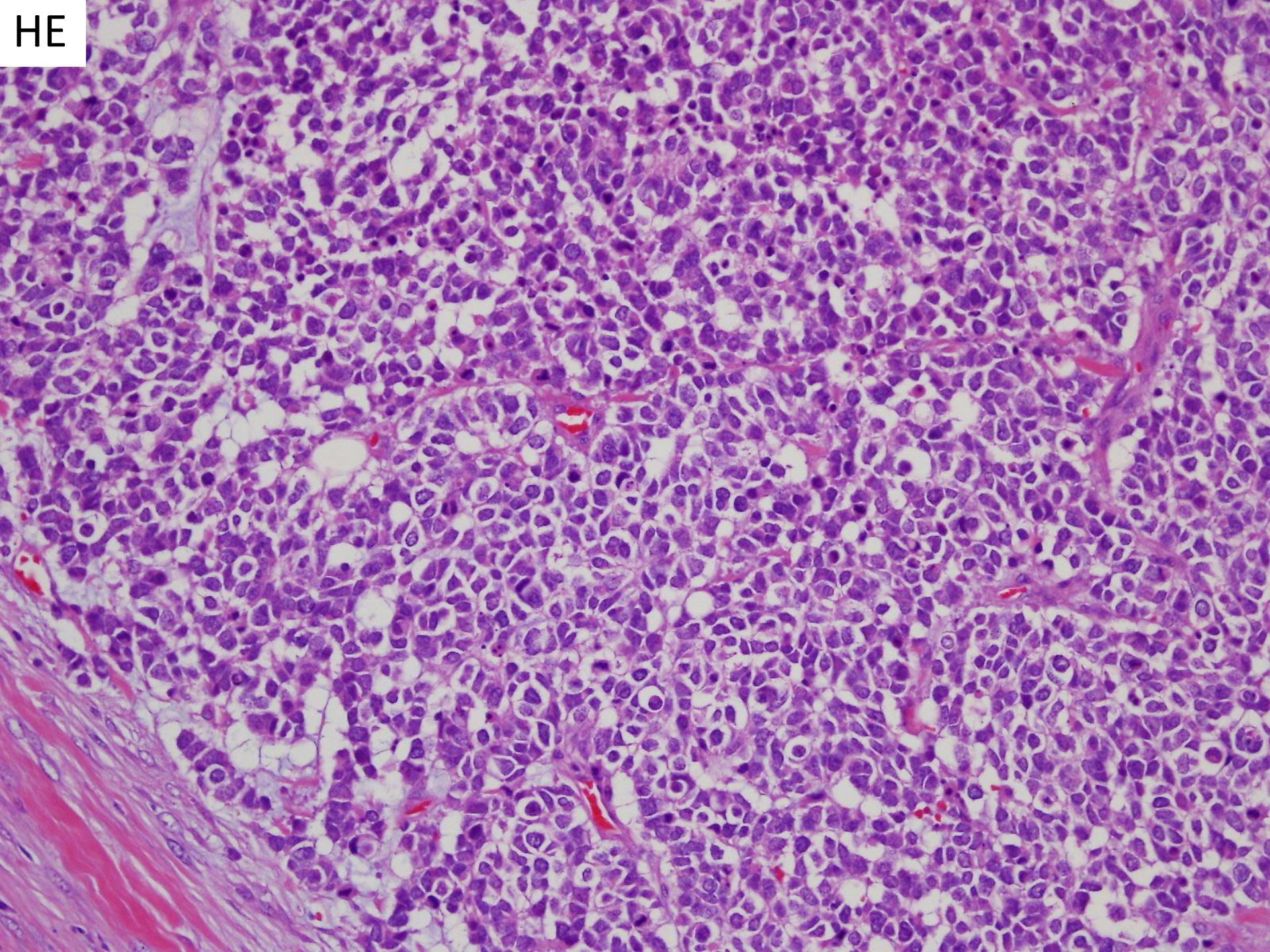
HE



HE

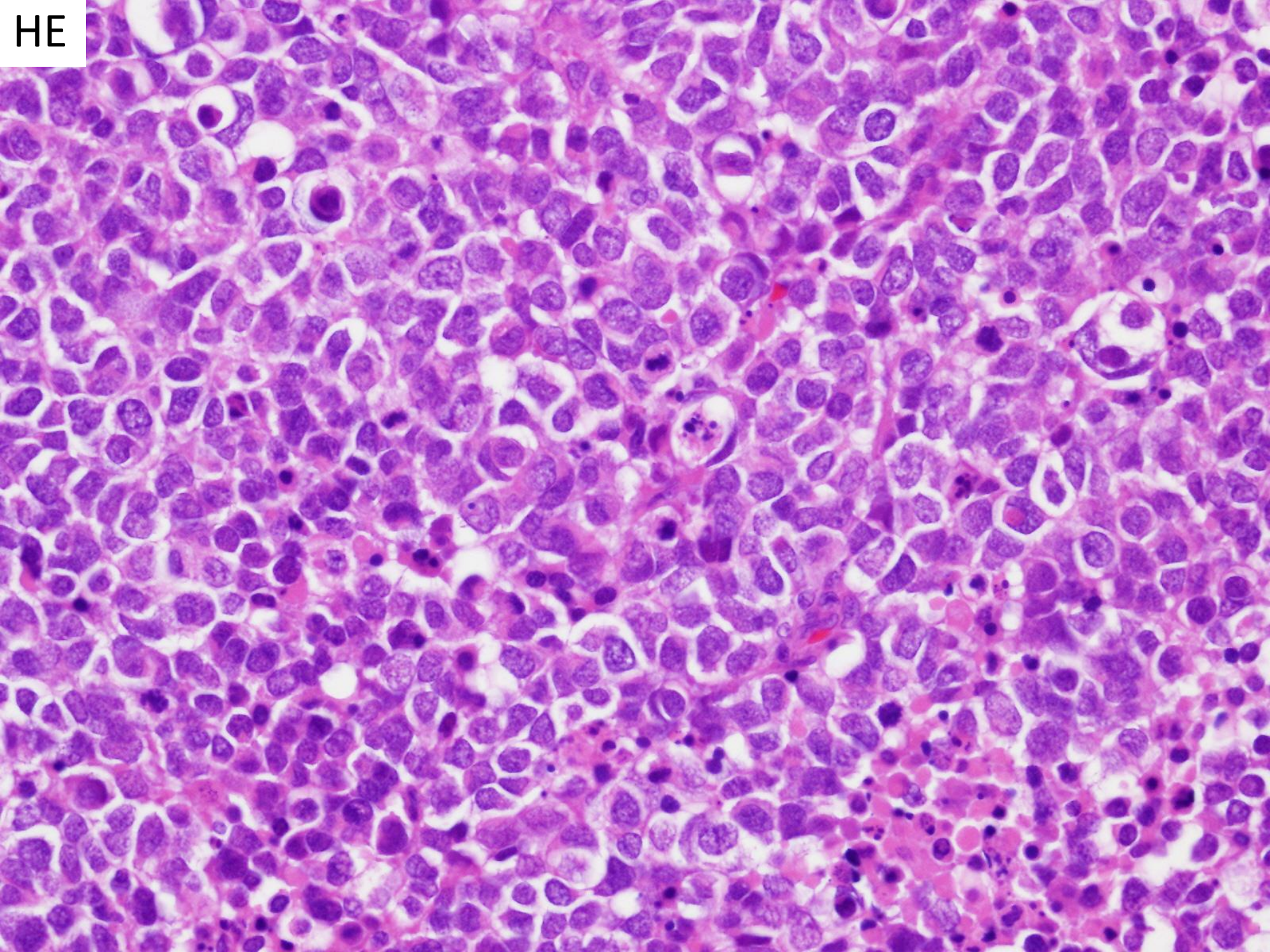


HE

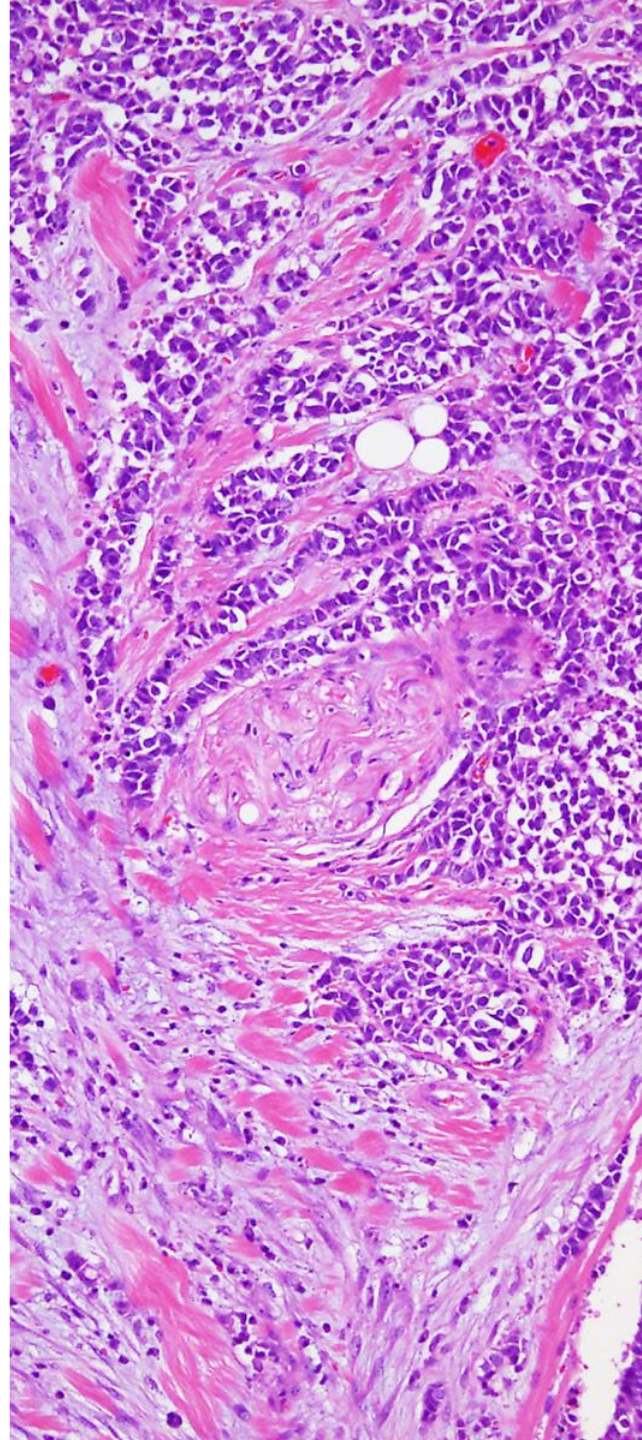
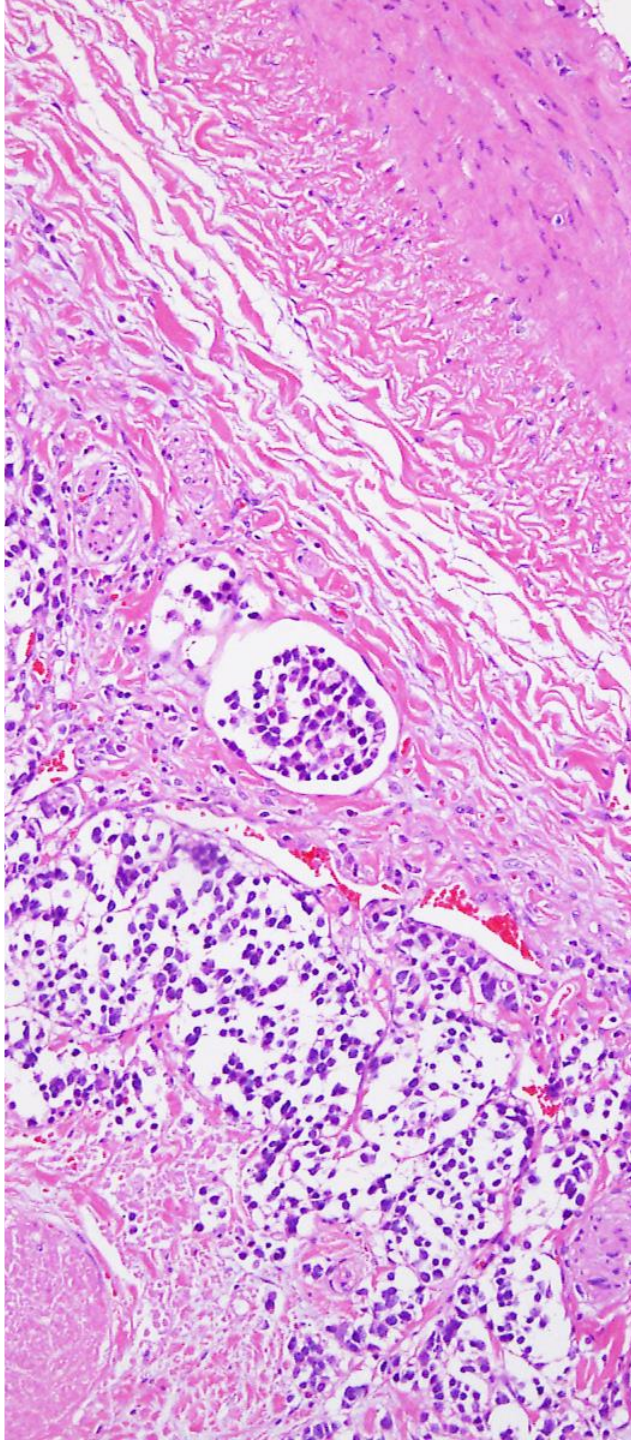
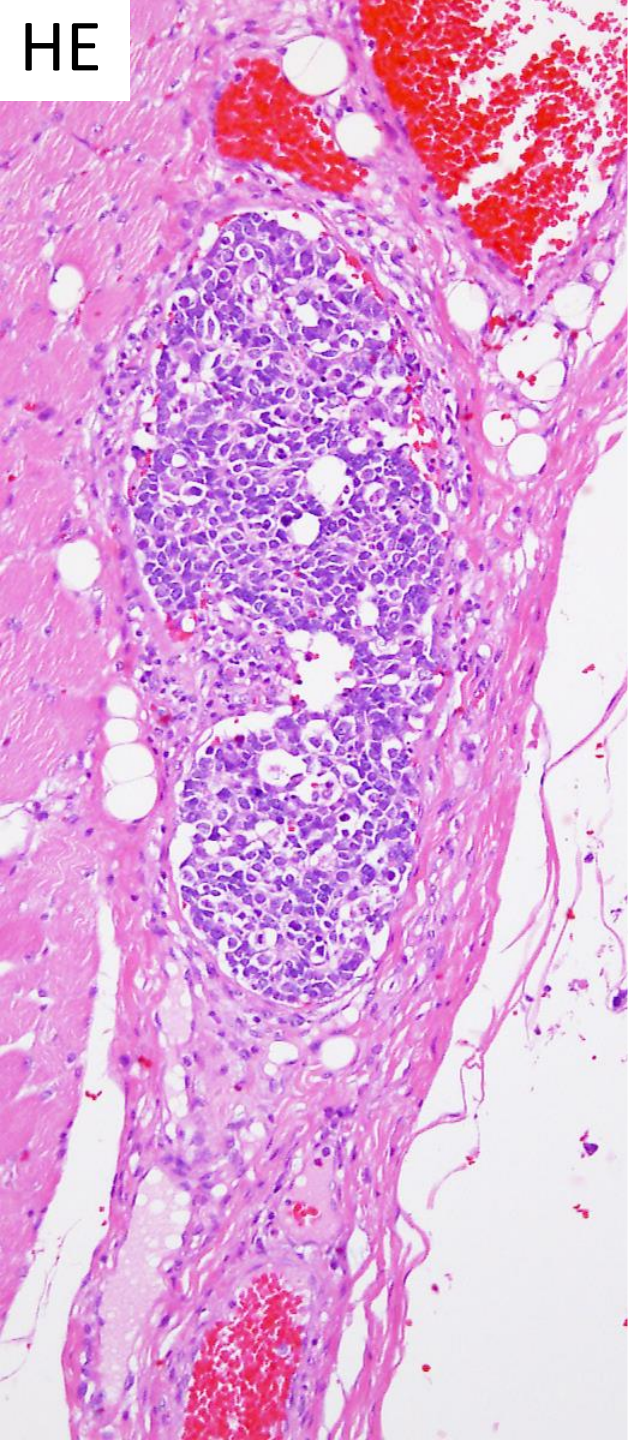




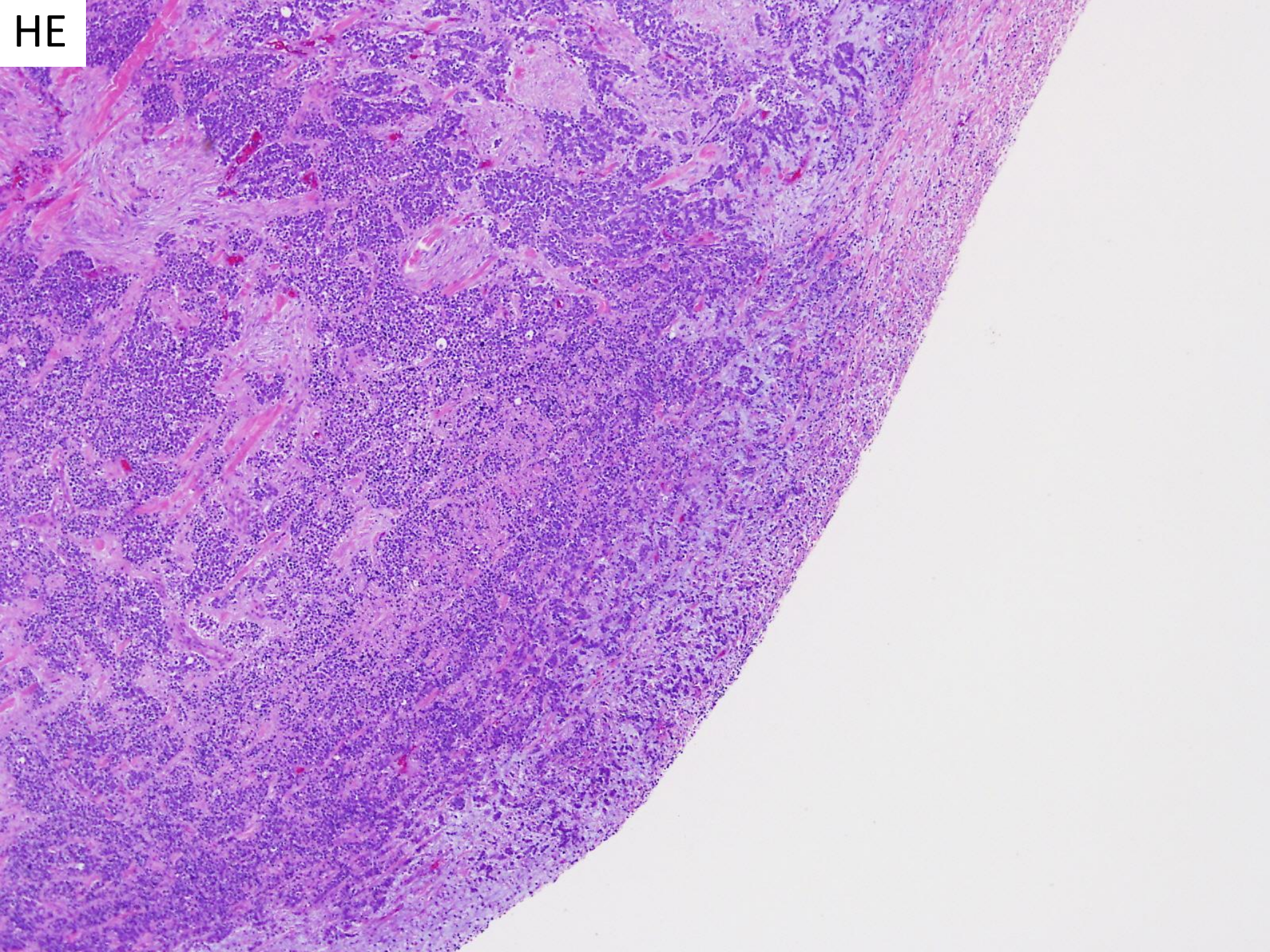
HE



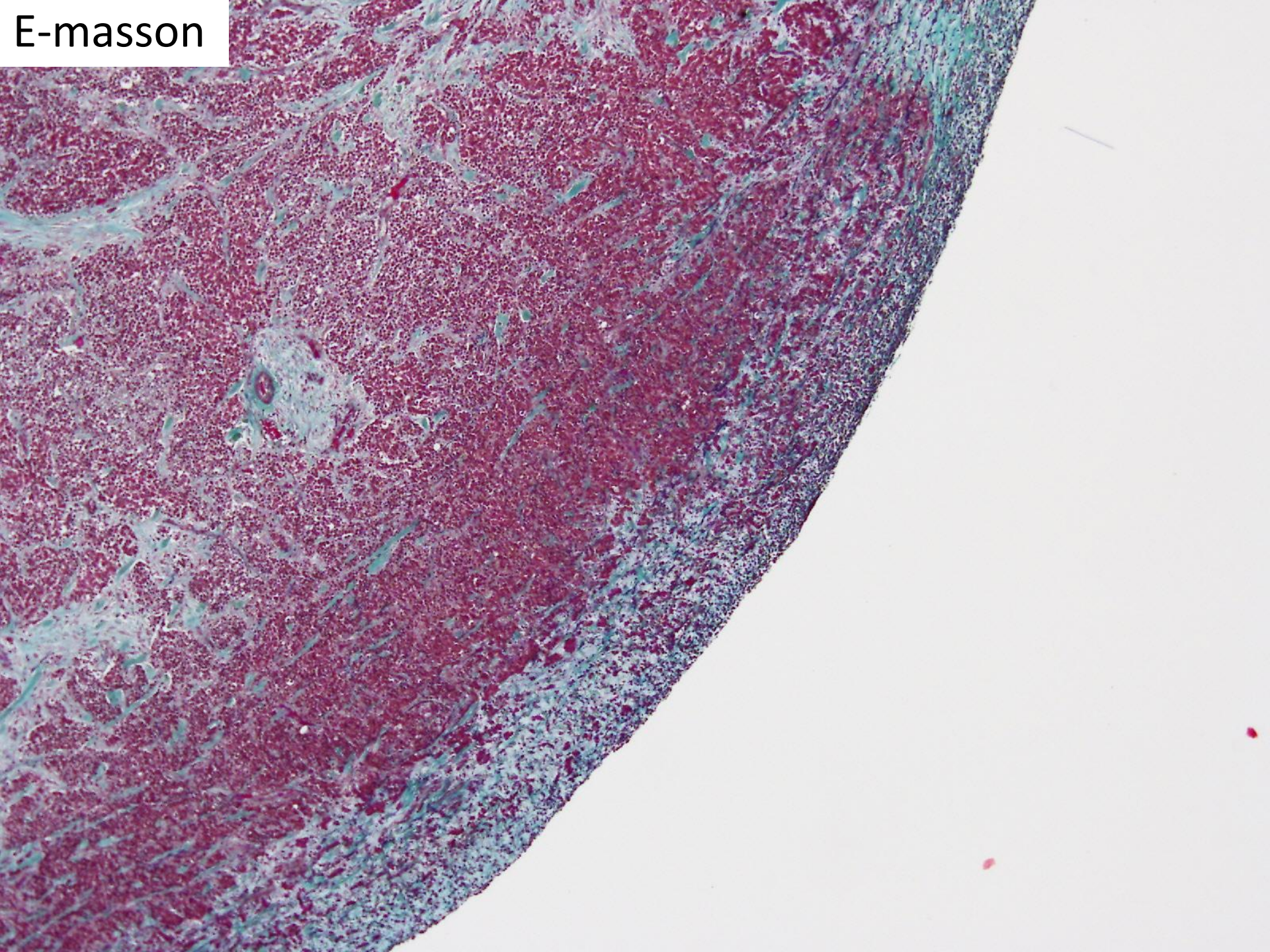
HE



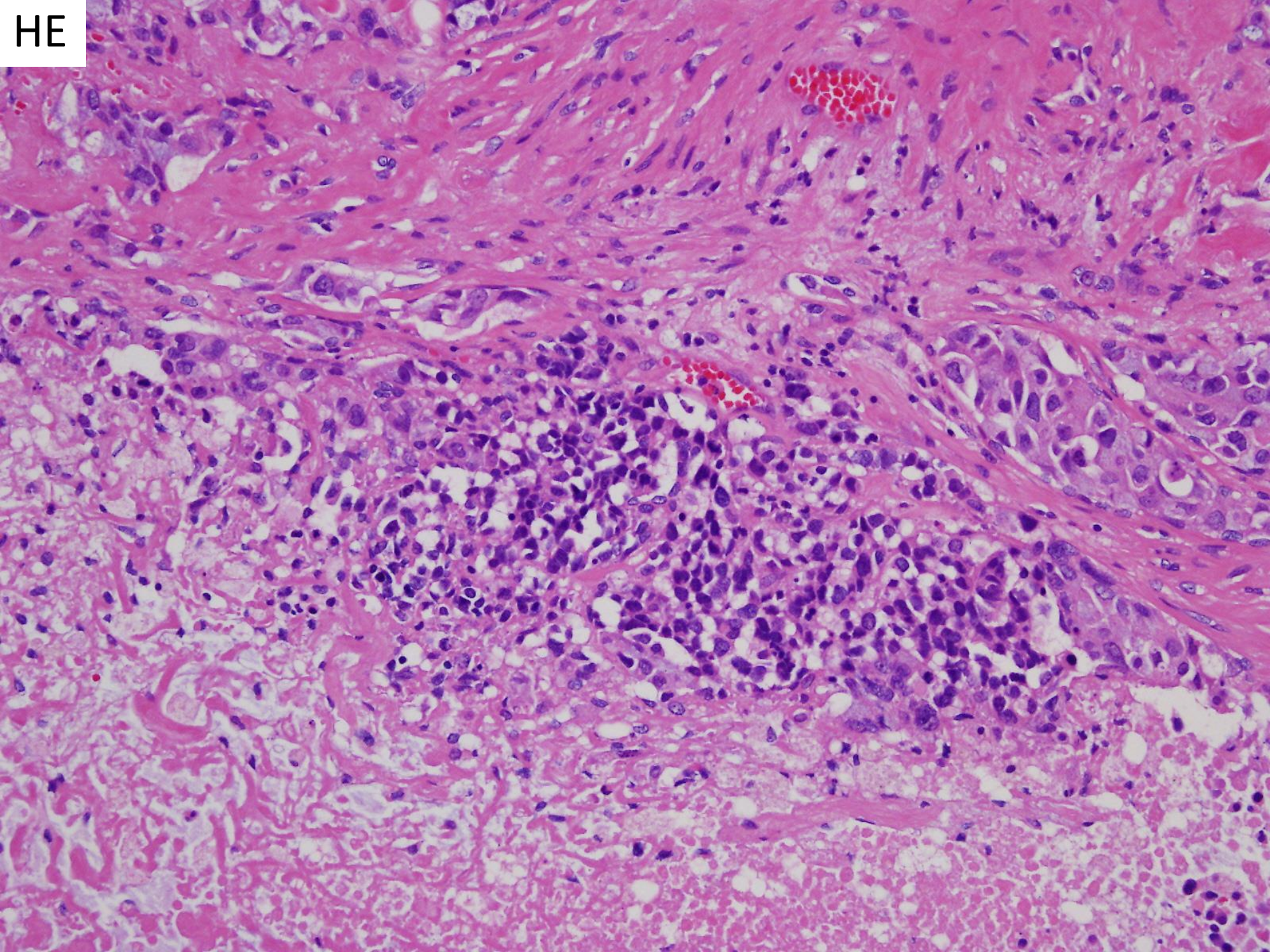
HE



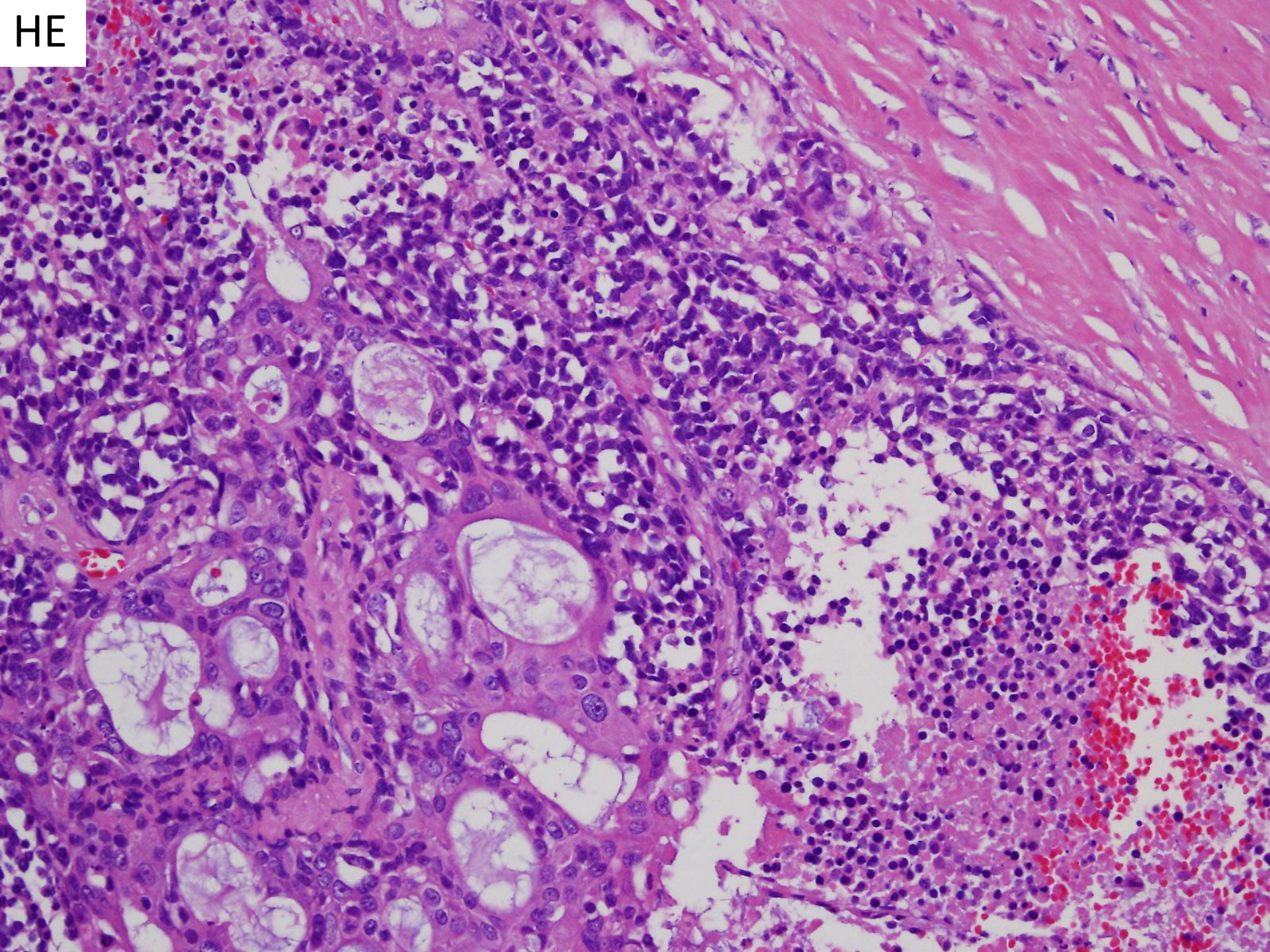
E-masson

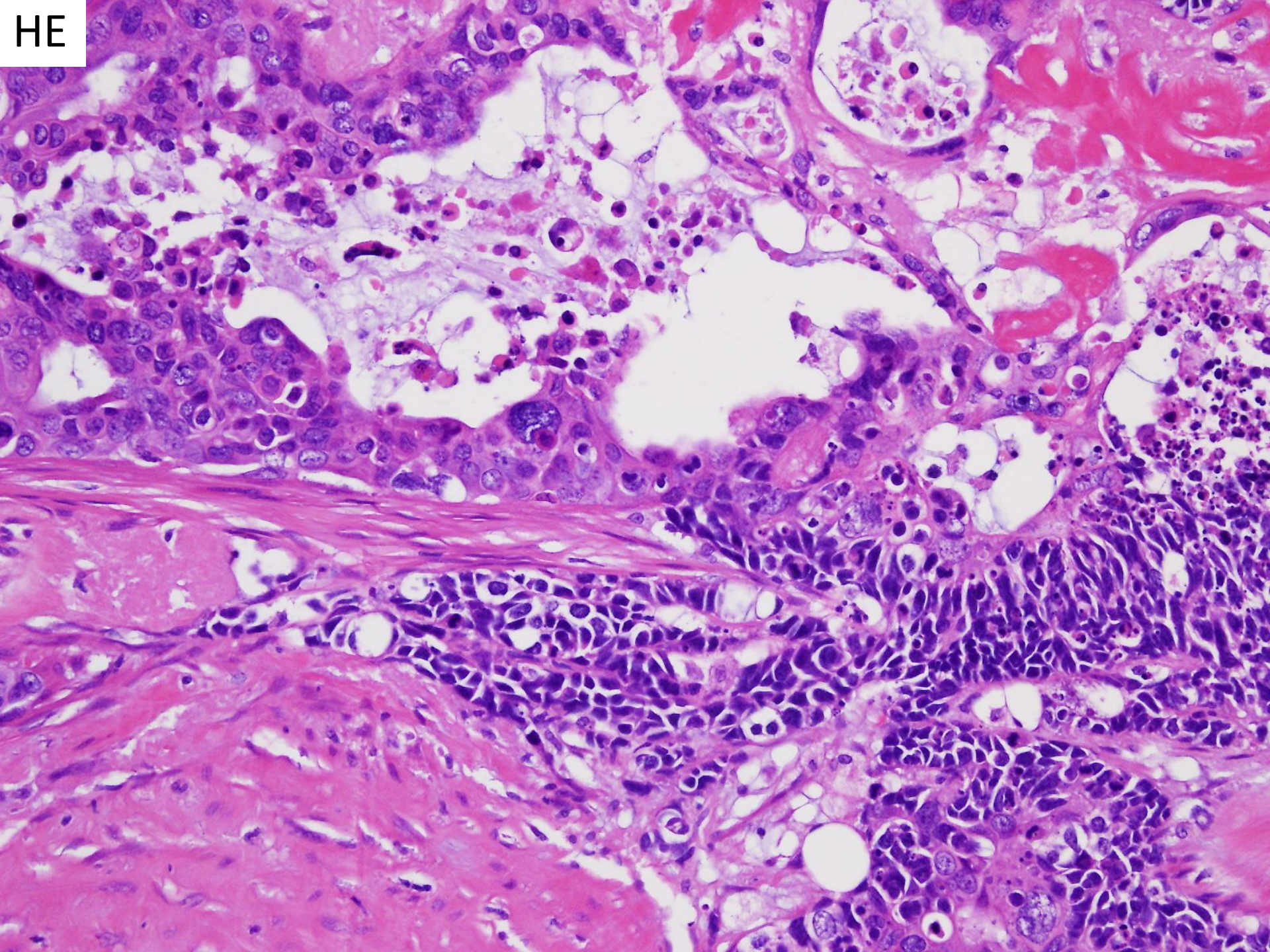


HE



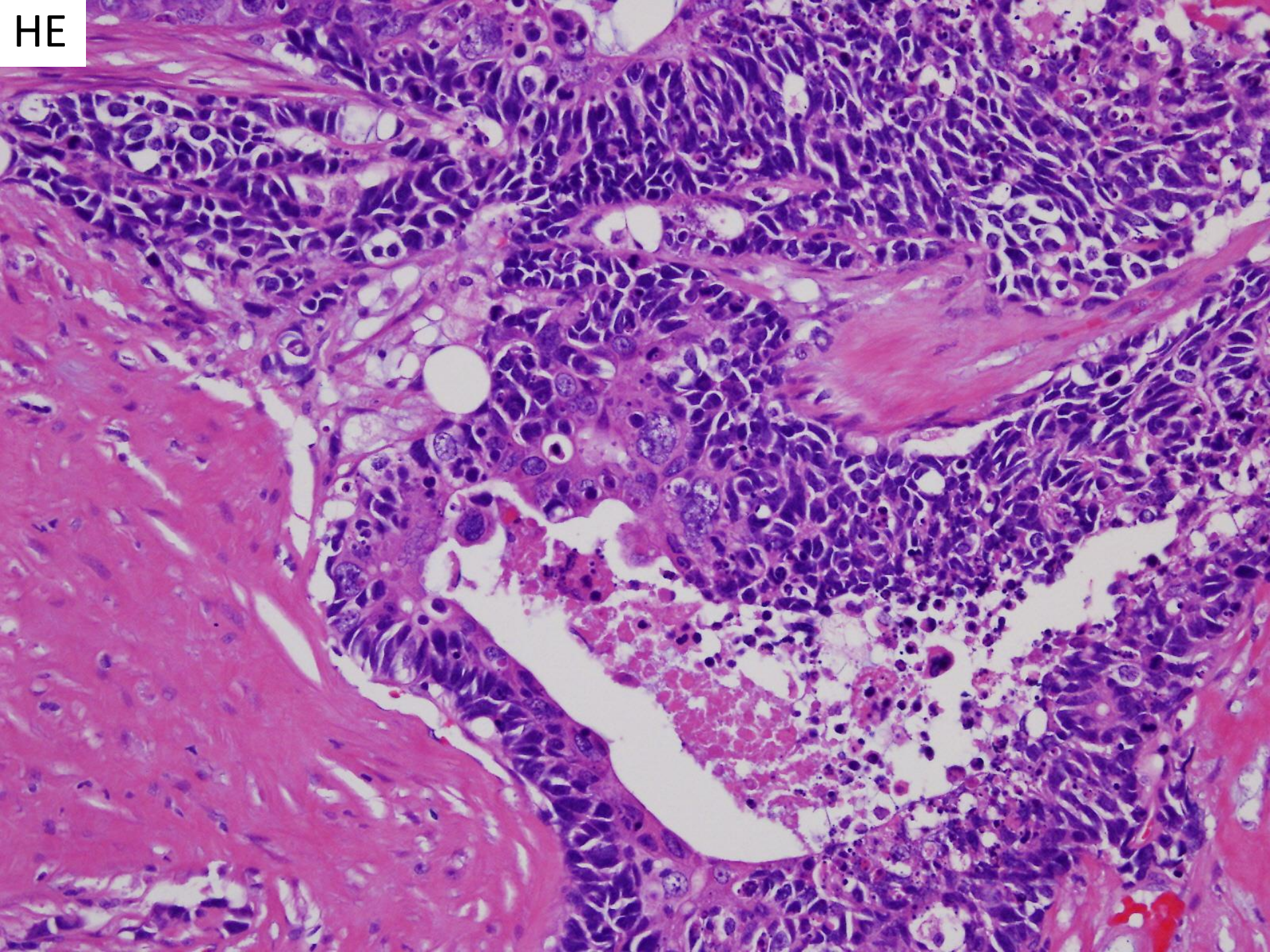
HE





HE

HE

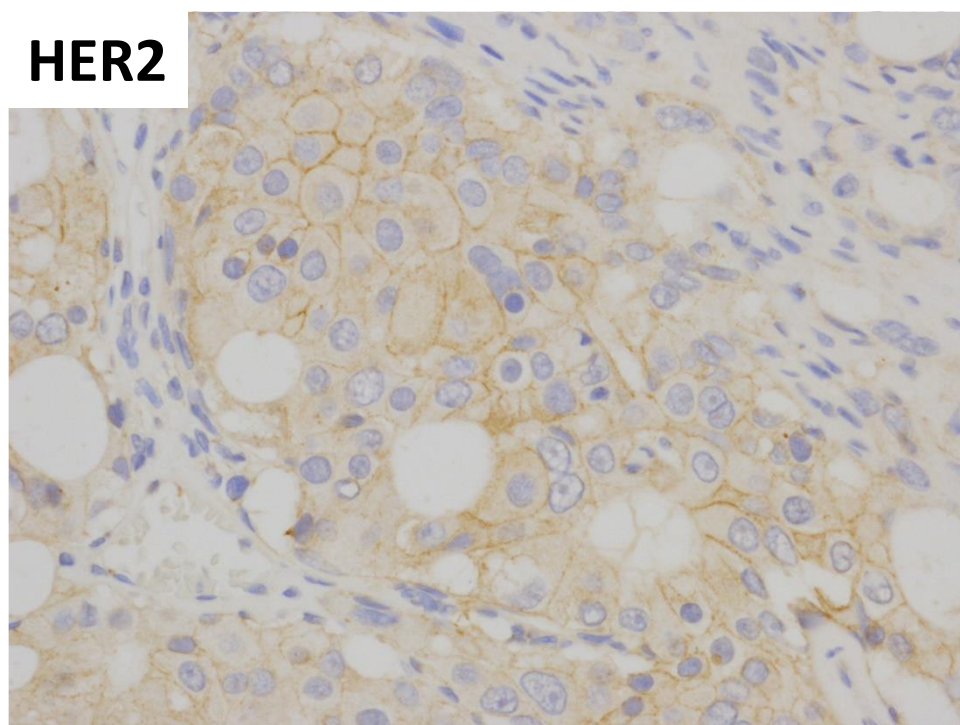
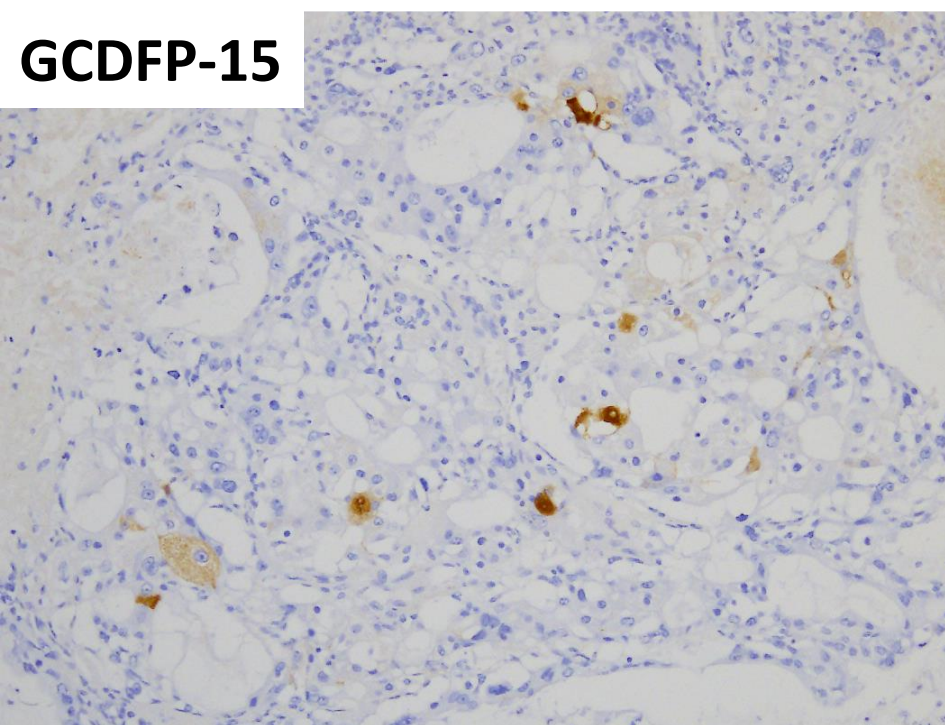
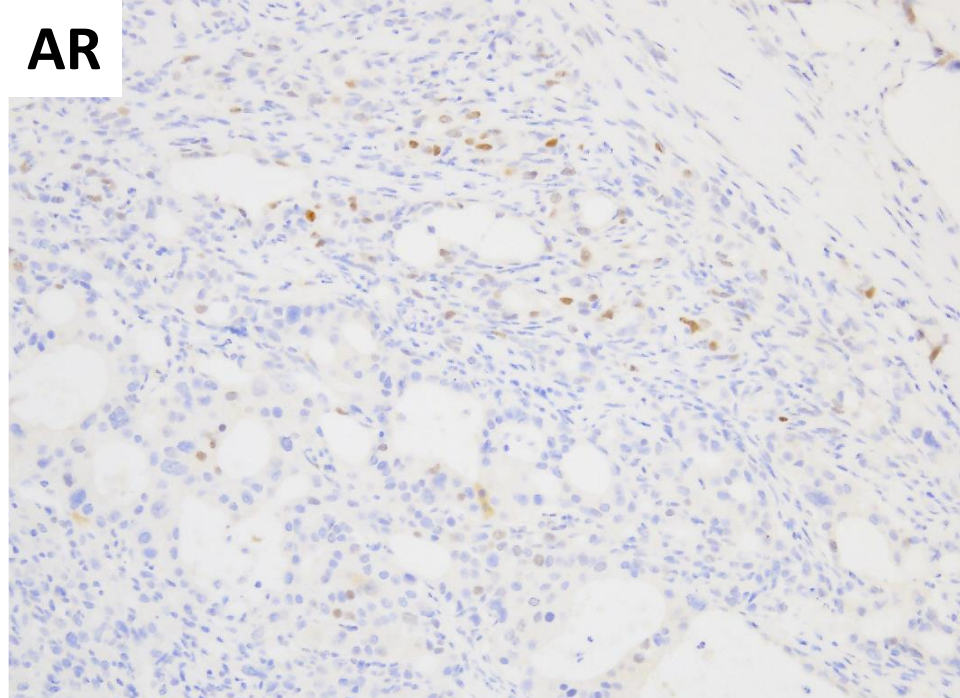
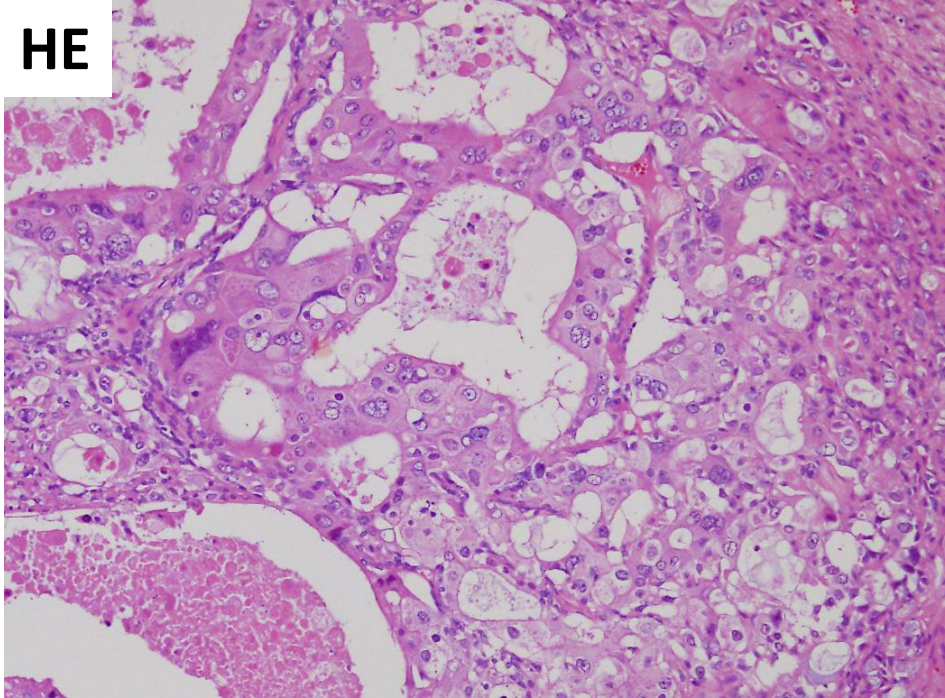




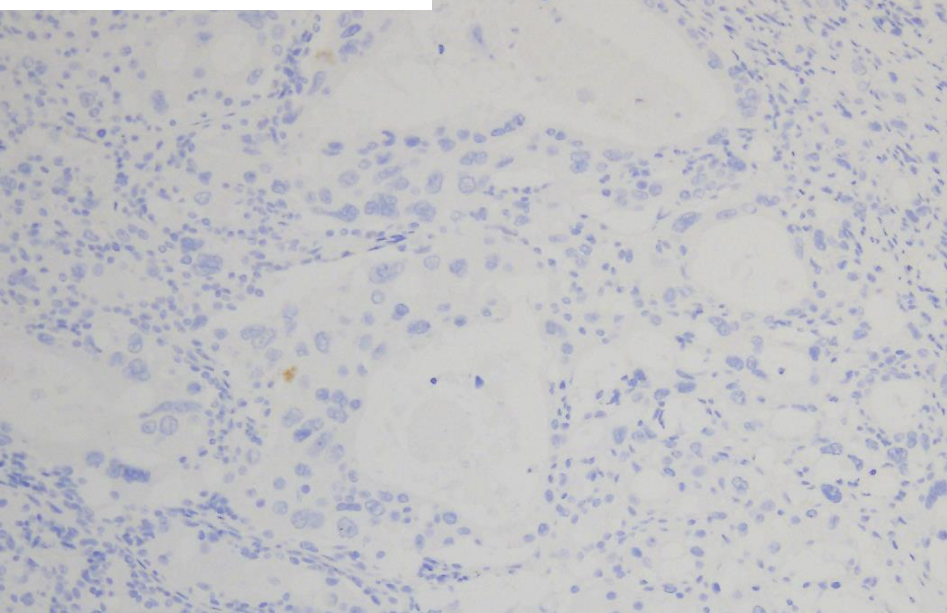
## 【鑑別診断】

- 唾液腺導管癌
- 粘表皮癌
- オンコサイト癌
- 腺様嚢胞癌
- 類基底扁平上皮癌
- 嚢胞腺癌
- +
- 小細胞癌
- 肺小細胞癌、皮膚メルケル細胞癌の転移
- 悪性リンパ腫

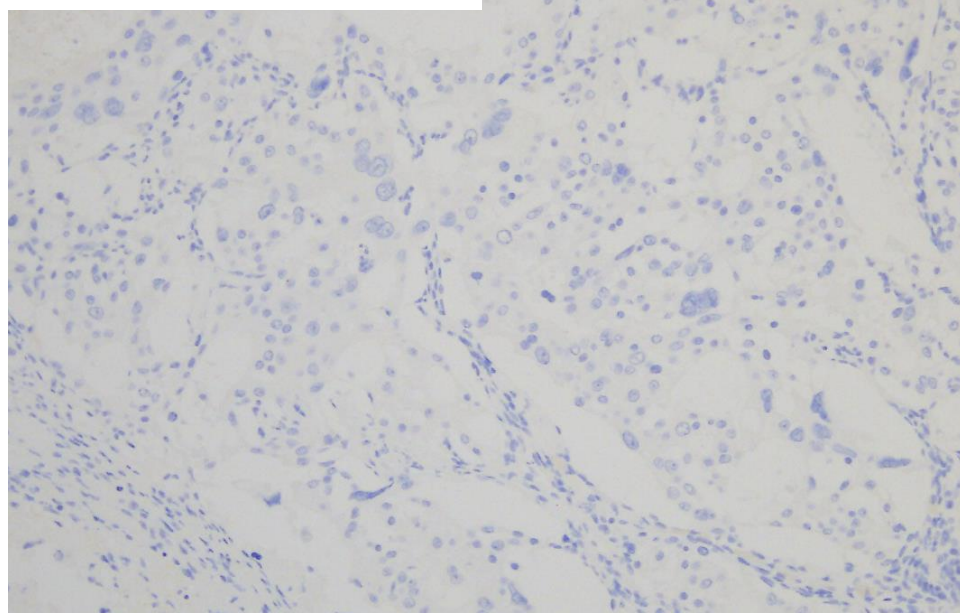
# 唾液腺導管癌にみえた成分



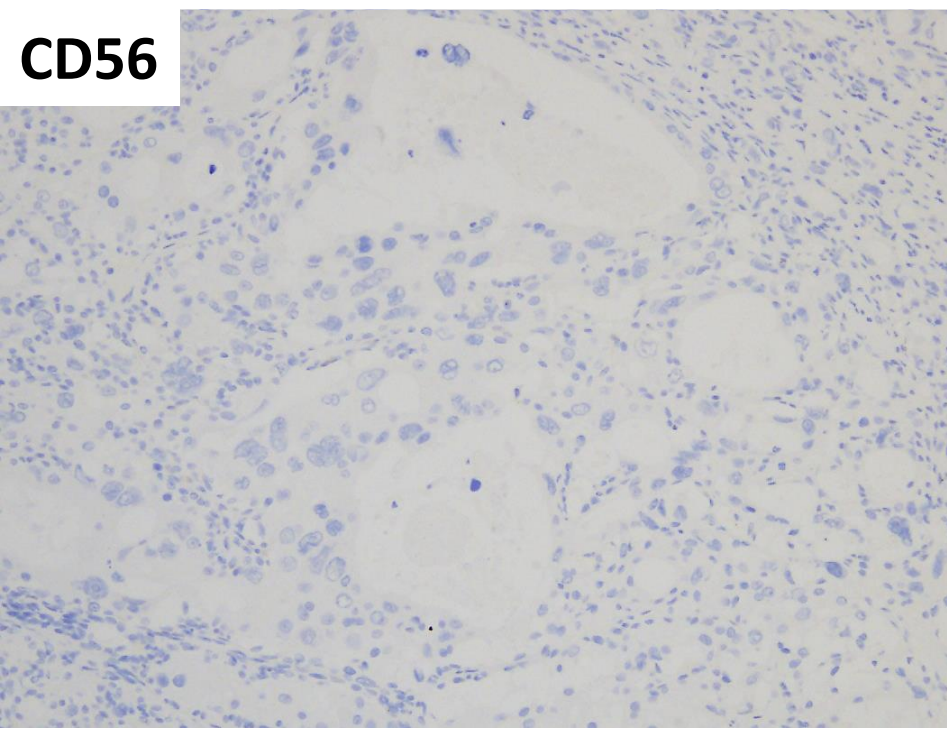
**Synaptophysin**



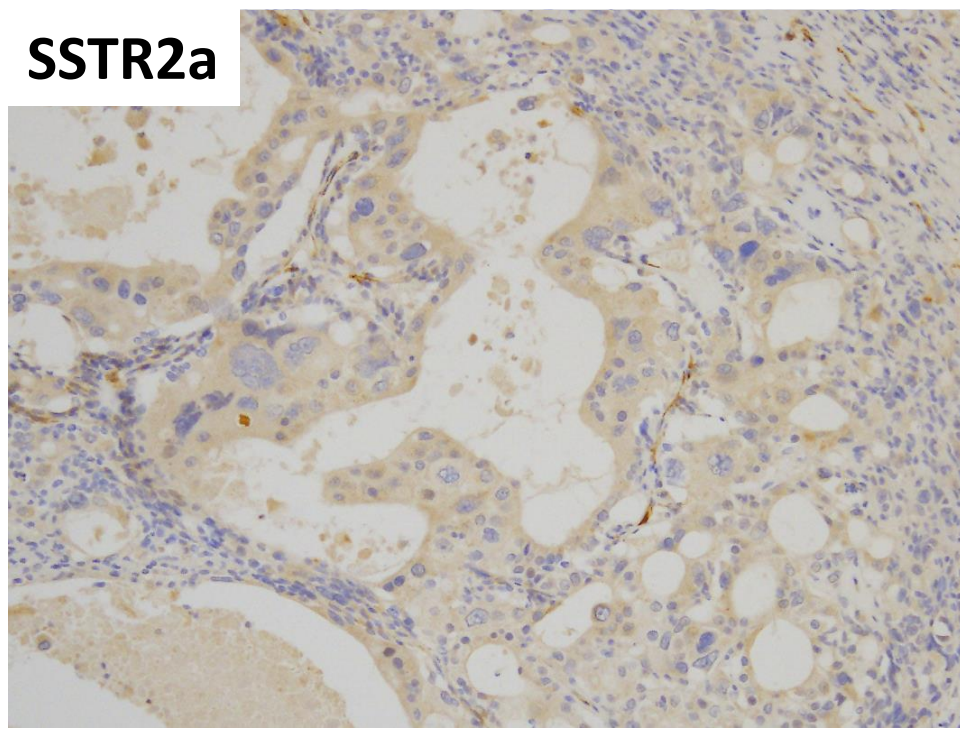
**Chromogranin A**

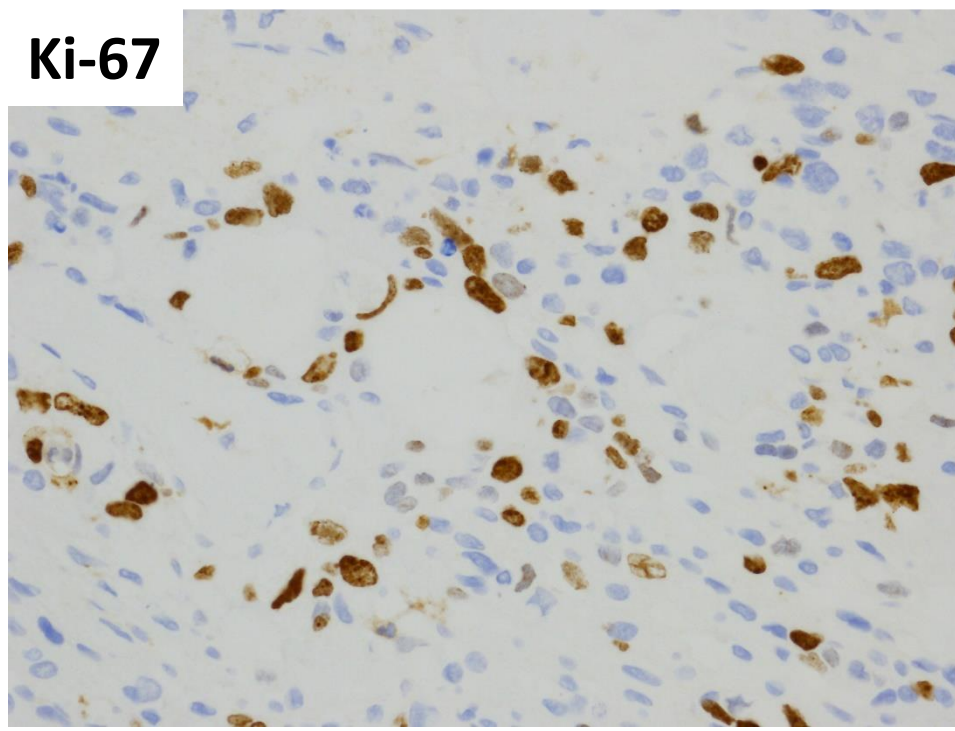
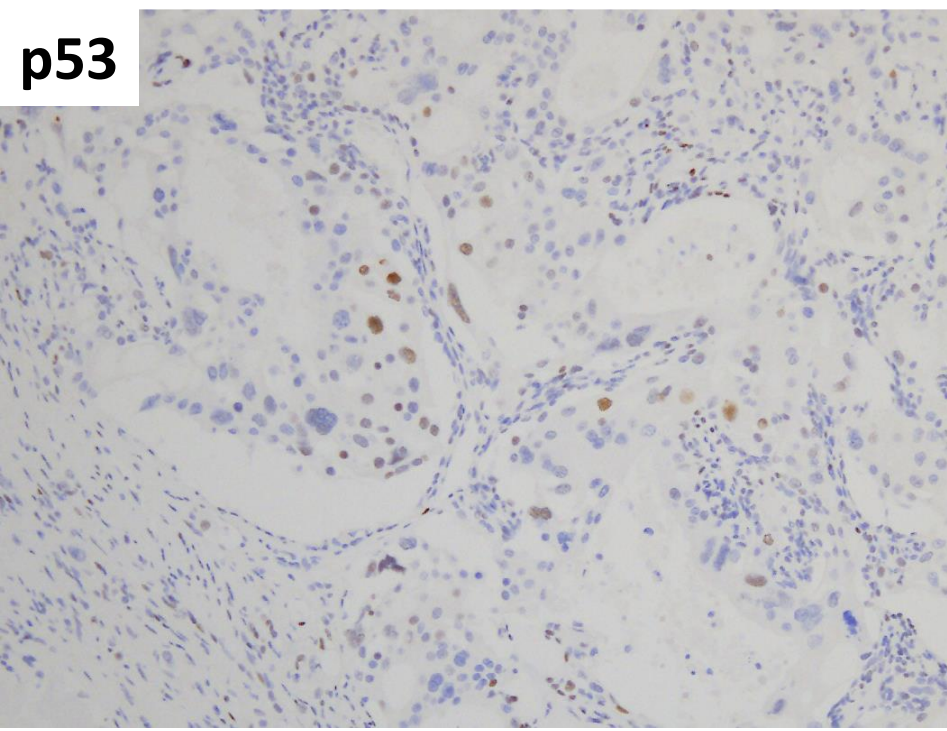
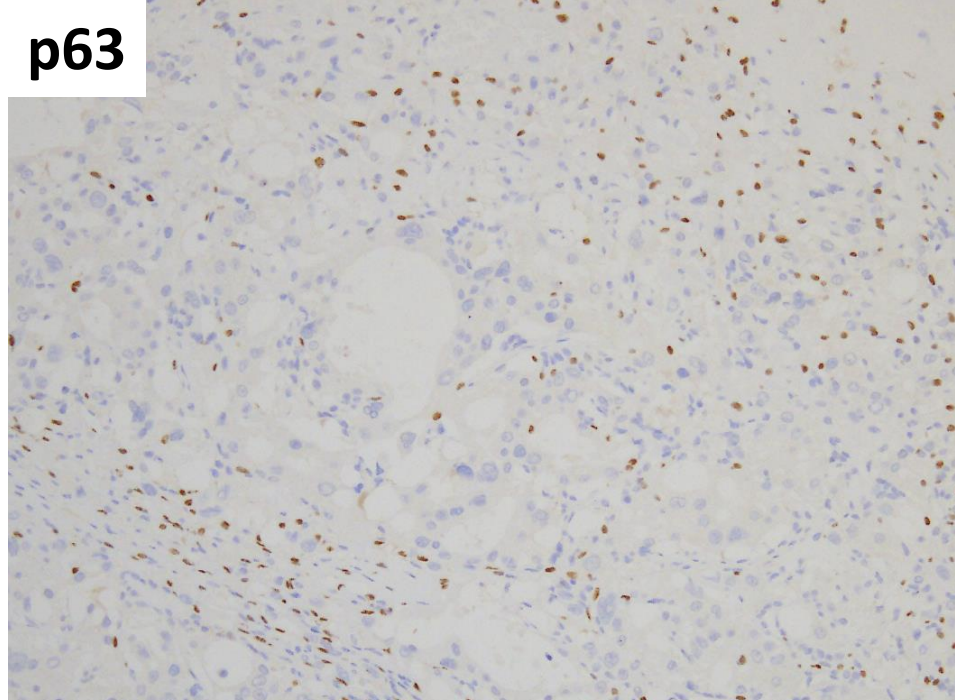
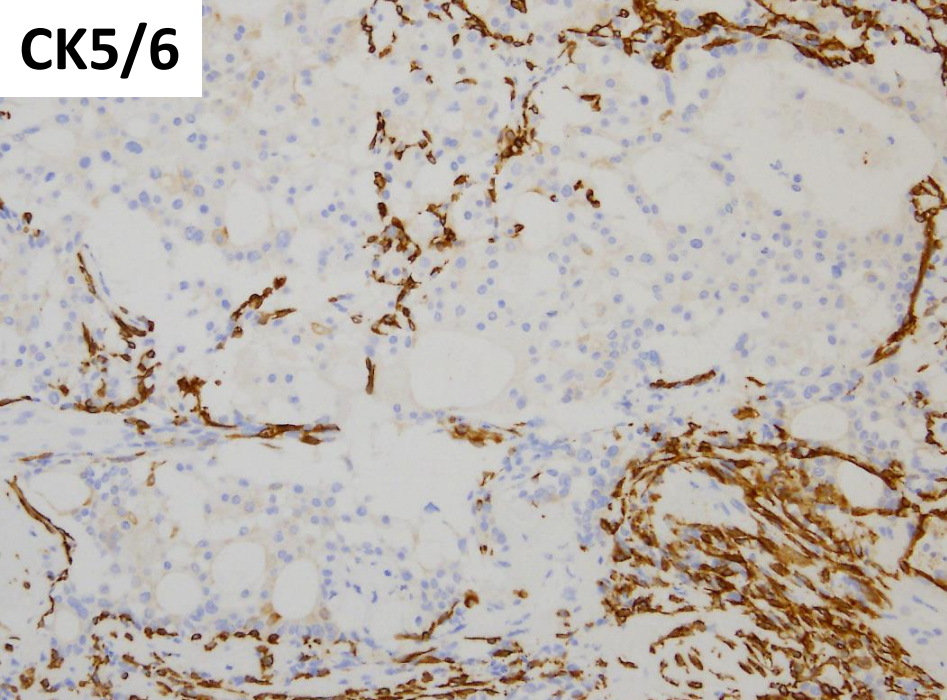


**CD56**

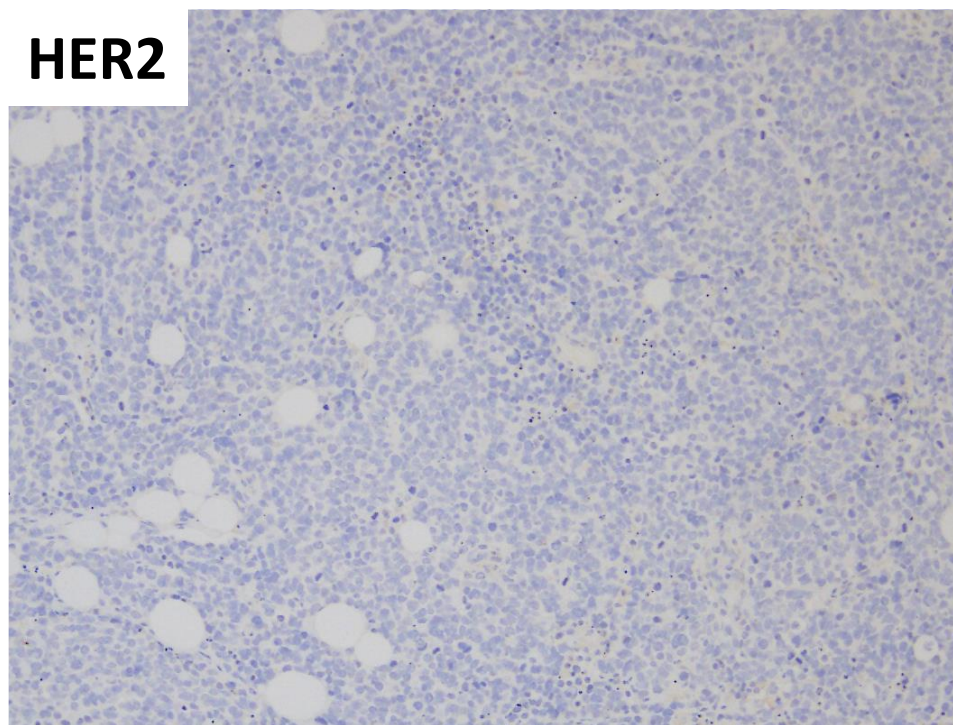
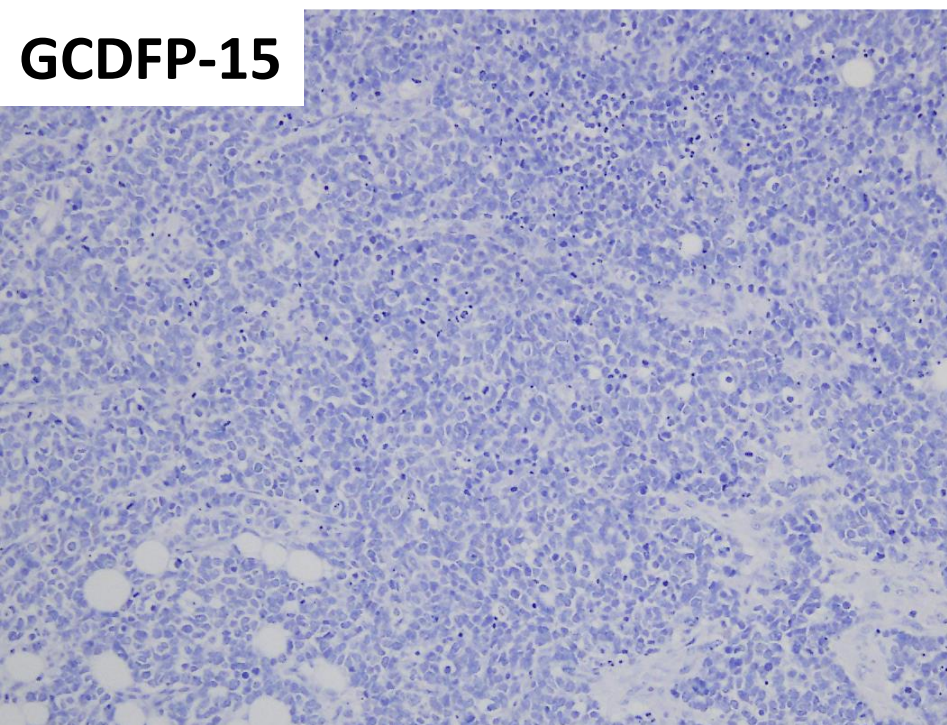
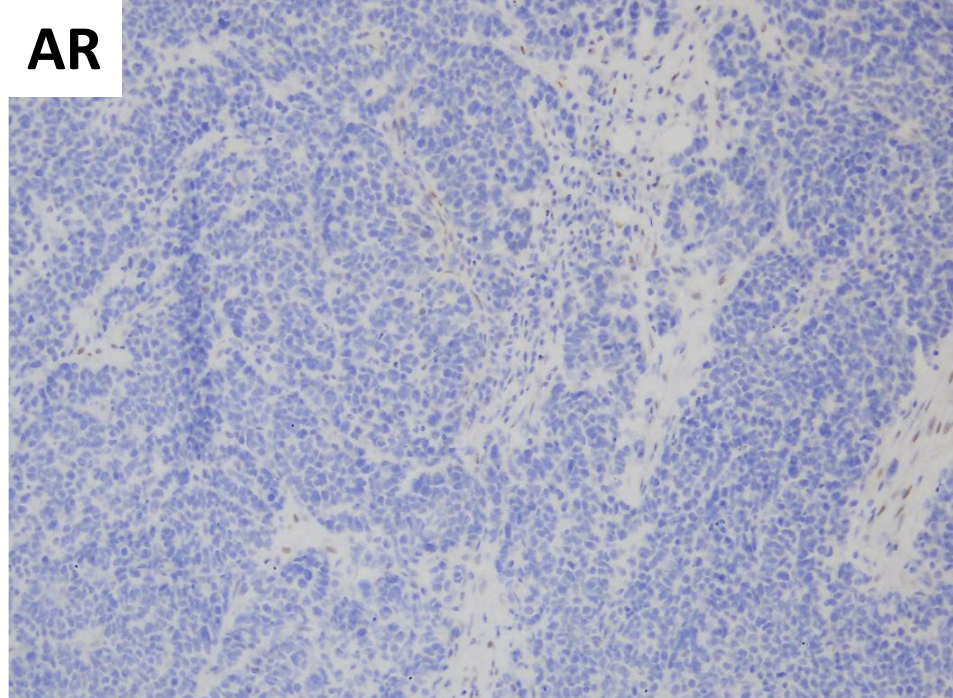
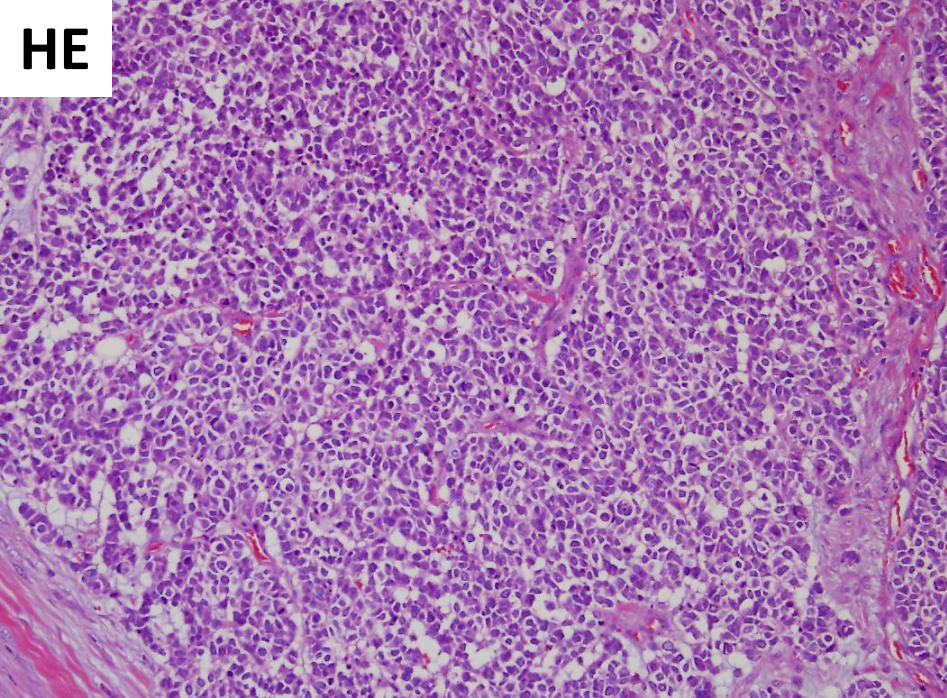


**SSTR2a**

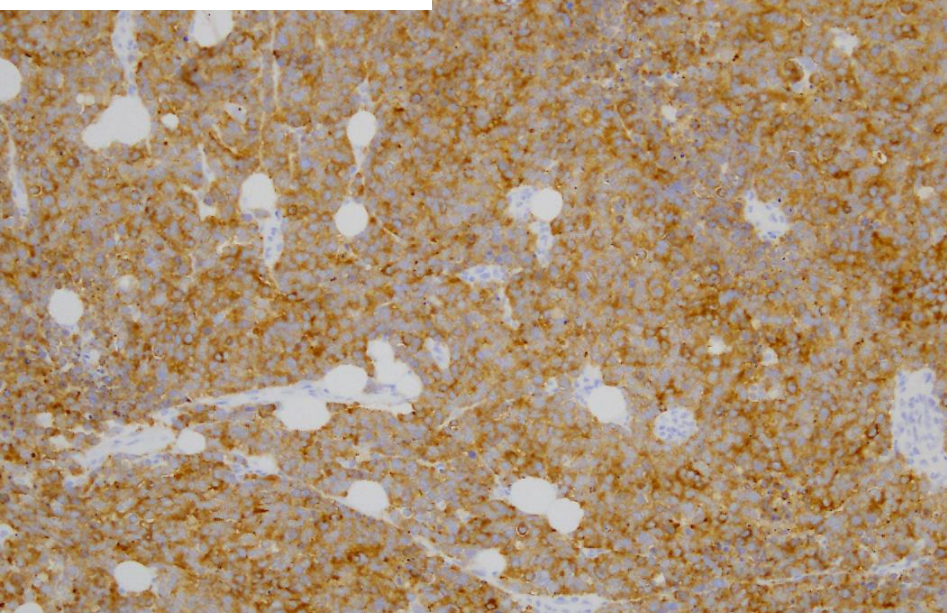




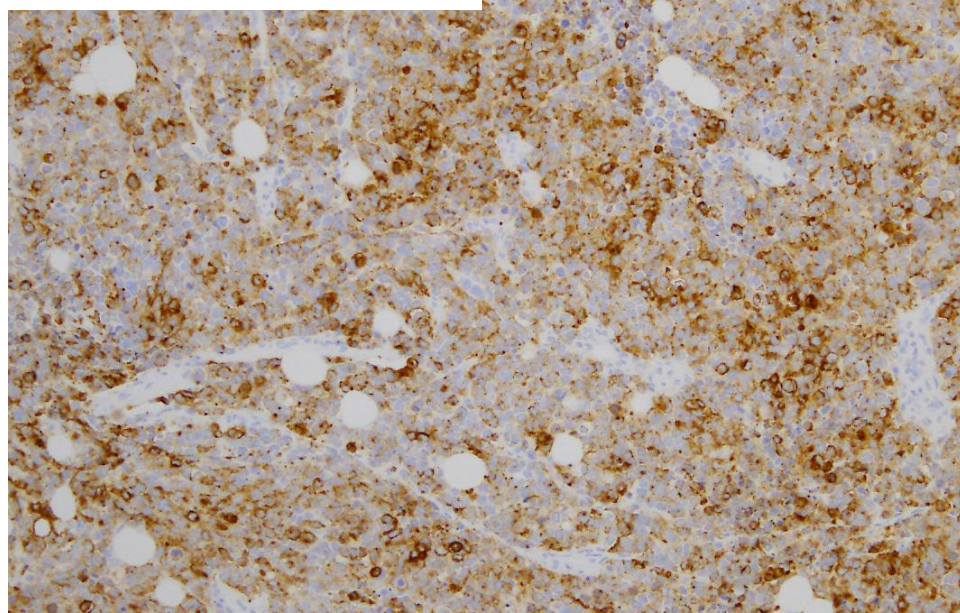
# 小細胞癌にみえた成分



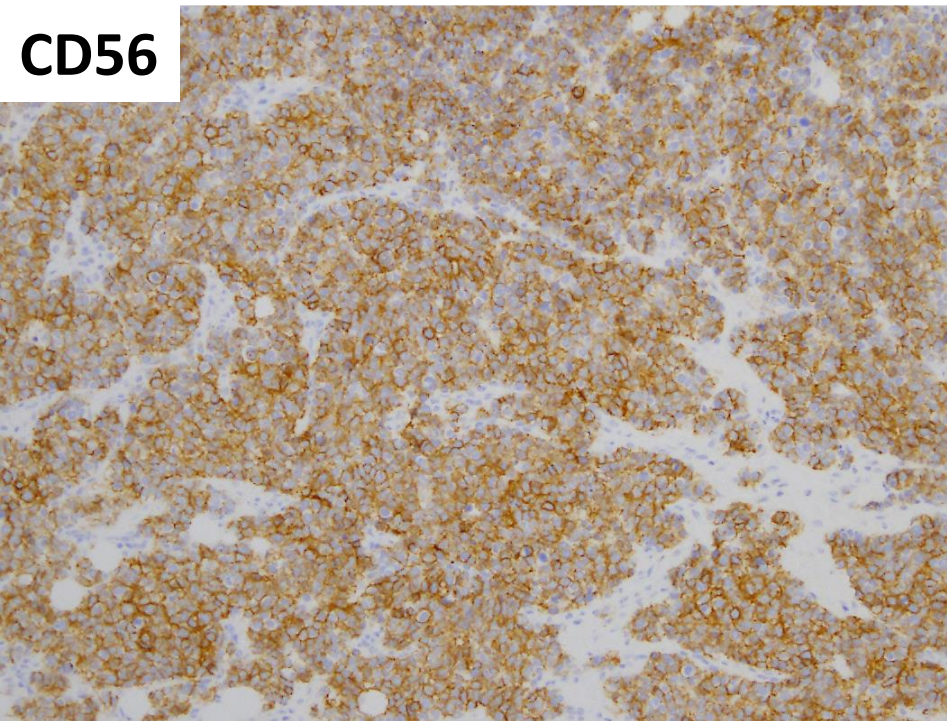
**Synaptophysin**



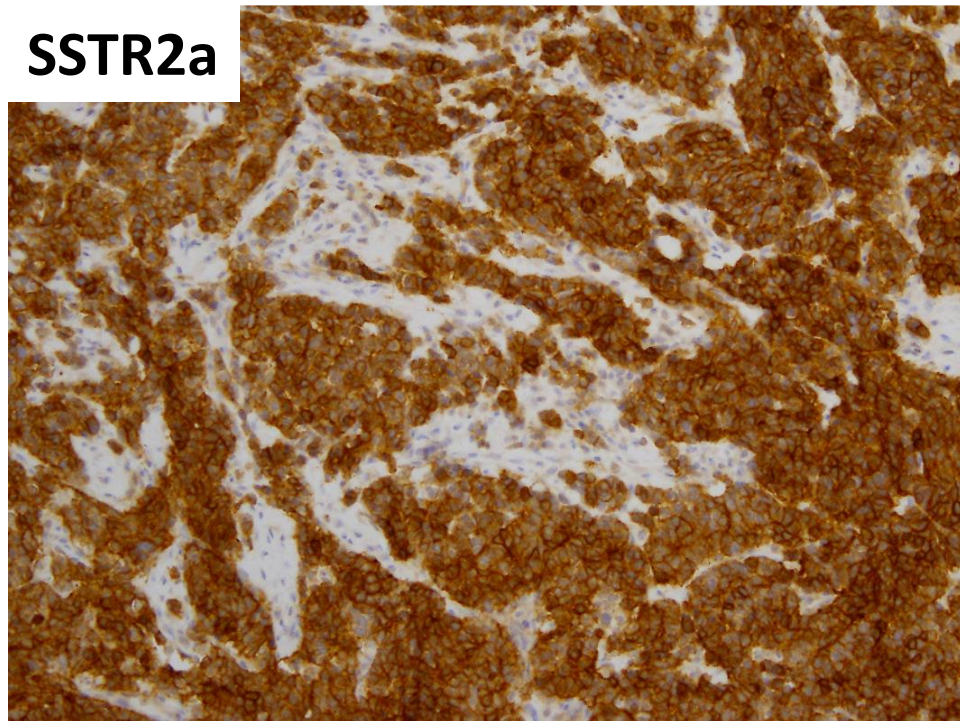
**Chromogranin A**



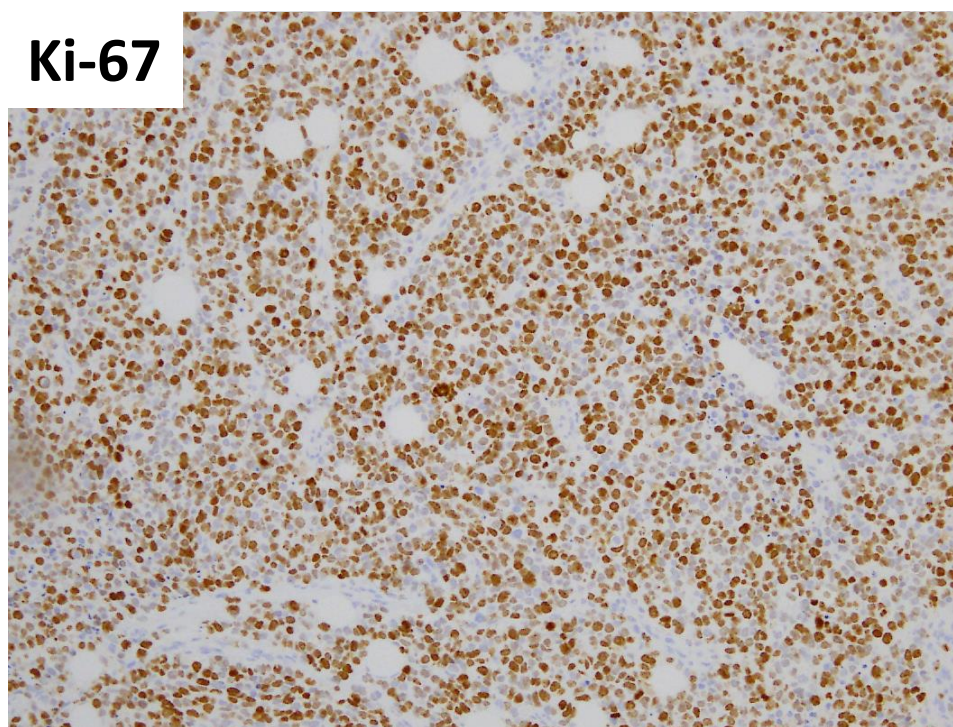
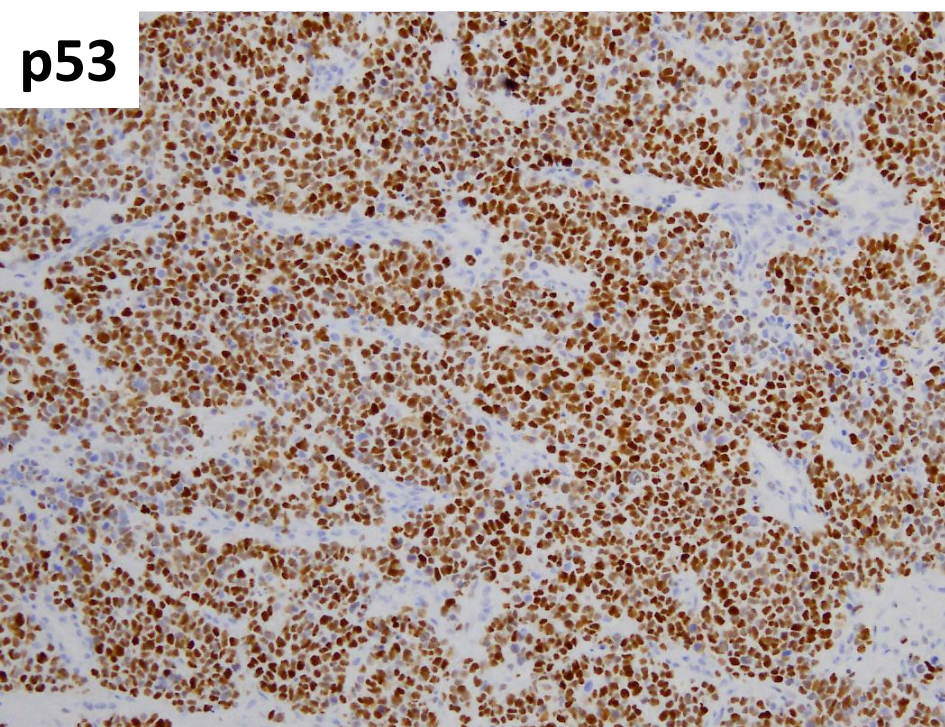
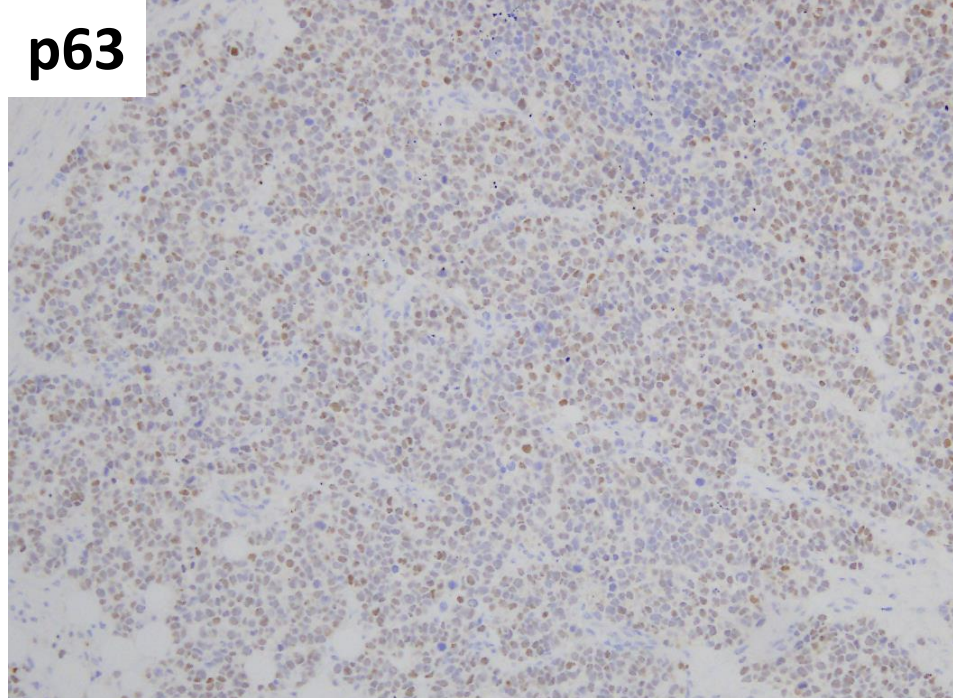
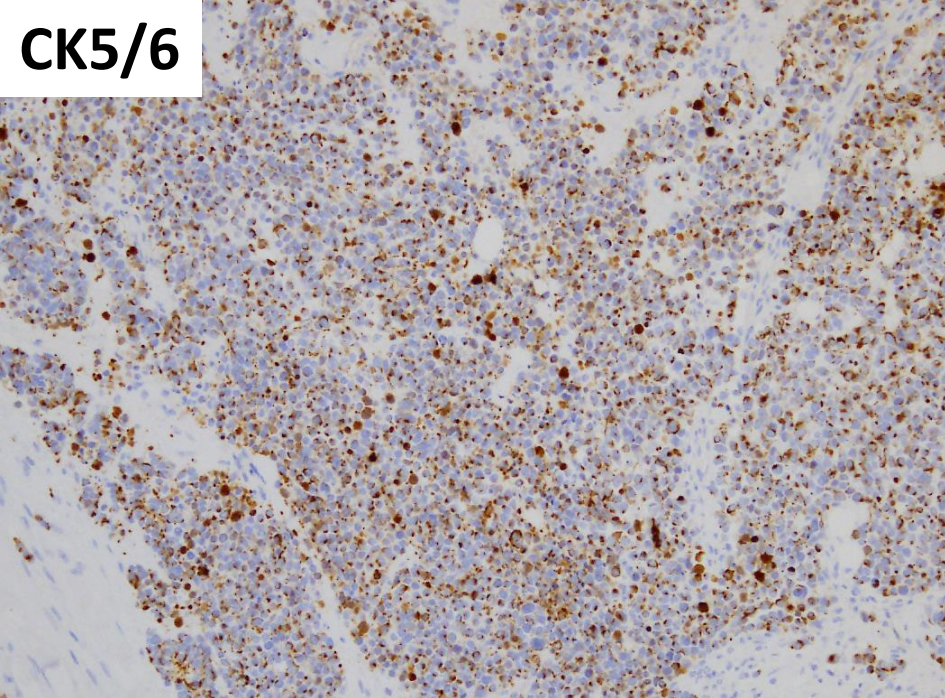
**CD56**



**SSTR2a**

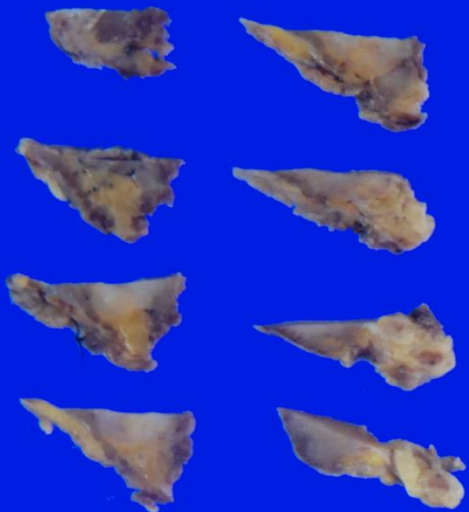



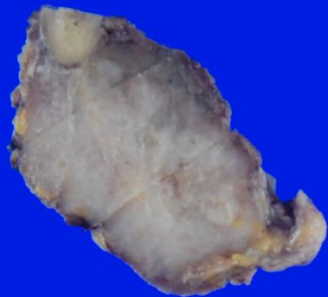


	唾液腺導管癌	小細胞癌
GCDFP-15	Focal +	—
AR	Focal +	—
HER2	Equivocal (score2)	— (score0)
Synaptophysin	—	+
Chromogranin A	—	+
CD56	—	+
SSTR2a	— (score 1)	+(score3)
CK5/6	—	+
p63	—	±
p53	±	+
Ki-67 labeling index	20~30%	90%

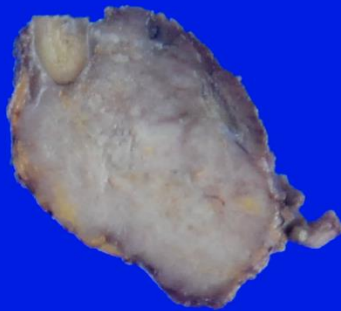
A



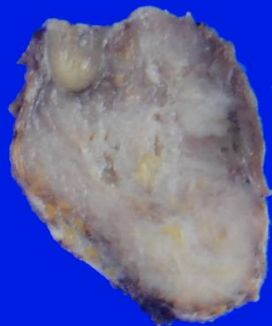B



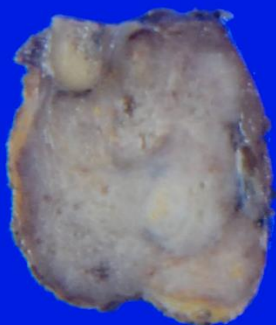C



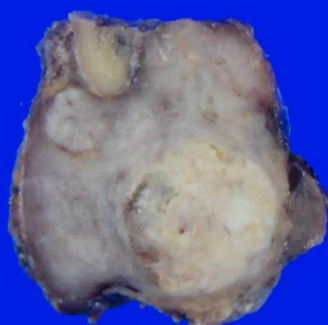
D



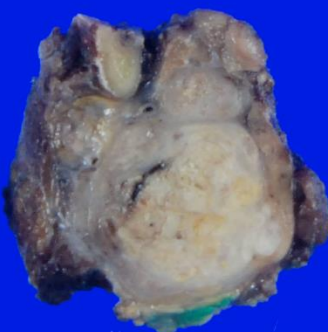
E



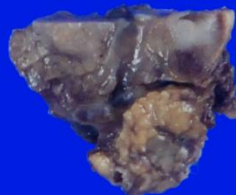
F



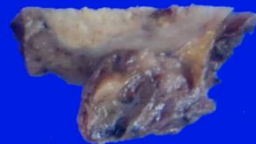G



I



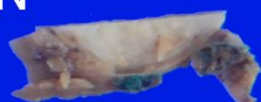K



M



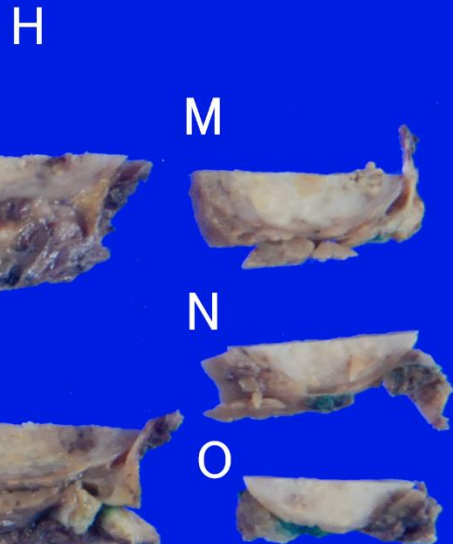N



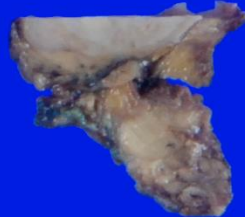
O



H




J



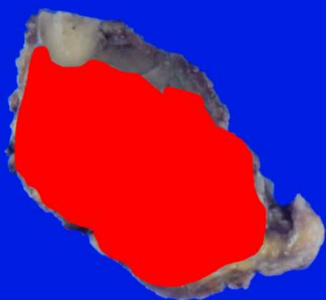L



A



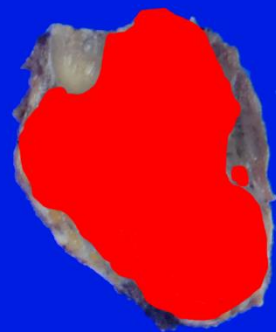B



C



D



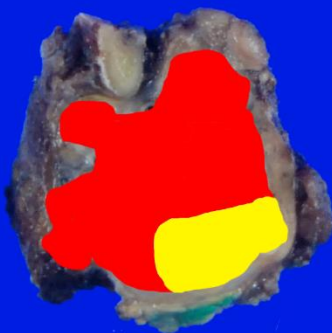E



F



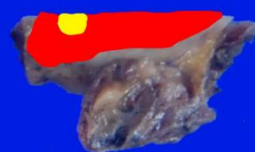G



I



H




M



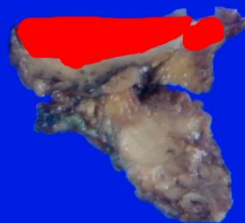N



O



J



L



唾液腺導管癌  
小細胞癌



# 【最終診断】

小細胞性神経内分泌癌、唾液腺導管癌  
の混合癌

mixed small cell neuroendocrine carcinoma and  
salivary duct carcinoma

# 【頭頸部癌取扱い規約 第5版】

左顎下腺, Mixed small cell neuroendocrine carcinoma and salivary duct carcinoma,

62x45x40mm, 浸潤型, pT3,

pN3b(本体付属:7/9, ①#右ⅡA:3/8,

②#右Ⅲ:0/14, ③#左ⅡAB:6/7, ④#左Ⅲ:3/7,

⑤#左Ⅳ:0/3, ⑦#左ⅤA:0/2, ⑦#左ⅤB:0/4),

M0, ly1, v1, pn2, pHM1, VM1, StageⅣB.

【TMN・UICC・7th】pT4pN3bM0, pStageⅣB.

## 【その後の経過】

術後42日～85日

POCRT (CDDP100mg/m<sup>2</sup>を2クール、放射線治療 50Gy)

術後174日

PETCTにて、骨(肋骨、肩甲骨、脊椎、骨盤骨)、腹腔リンパ節、肝臓、右副腎、脳転移を示唆する所見あり。

## 【小細胞性神経内分泌癌】

- いわゆる小細胞癌で、低分化癌の中の、小細胞性神経内分泌癌と分類されている。
- 唾液腺悪性腫瘍の2%程度。
- 多形腺腫由来癌の報告はある<sup>1)</sup>。
- 混合癌の報告は検索範囲ではみられなかった。

1) Cimino-Mathews A et al., 2012, Small cell carcinoma ex-pleomorphic adenoma of the parotid gland, Head Neck Pathol, 6, 502-506



## 【唾液腺導管癌】

- 唾液腺悪性腫瘍の10%程度
- 乳腺の乳管癌と類似した形態を示す。
- 肉腫様、富粘液、浸潤性微小乳頭状などの亜型が知られている。
- 富粘液亜型では、細胞内外に粘液がみられ、印環細胞様細胞もみられる。

## 【まとめ・考察】

- ・顎下腺の腫瘍で、形態像や免疫染色所見から、小細胞神経内分泌癌と唾液腺導管癌の混合癌と考えた。
- ・同様の症例の報告は検索範囲内でなく、非常にまれであると考えられる。

## 【疑問点】

- ・診断として問題ないでしょうか？
- ・経過から、唾液腺導管癌が小細胞癌に移行した可能性を考えましたが、矛盾ないでしょうか？